



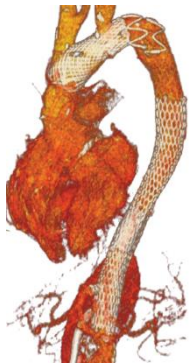
AORTIC  
LIVE

2016

October 17-18, 2016  
Philharmonie Essen, Germany

3rd Aortic Live Symposium

# UPDATE PATIENT FOLLOW-UP



**AORTIC LIVE**

September 11-13, 2014

2

Day 2 - 12.09.2014

Surg. P. Kasprzak

**Patient**

71 y/o male, 76 kg, 170 cm

Aortic arch aneurysm

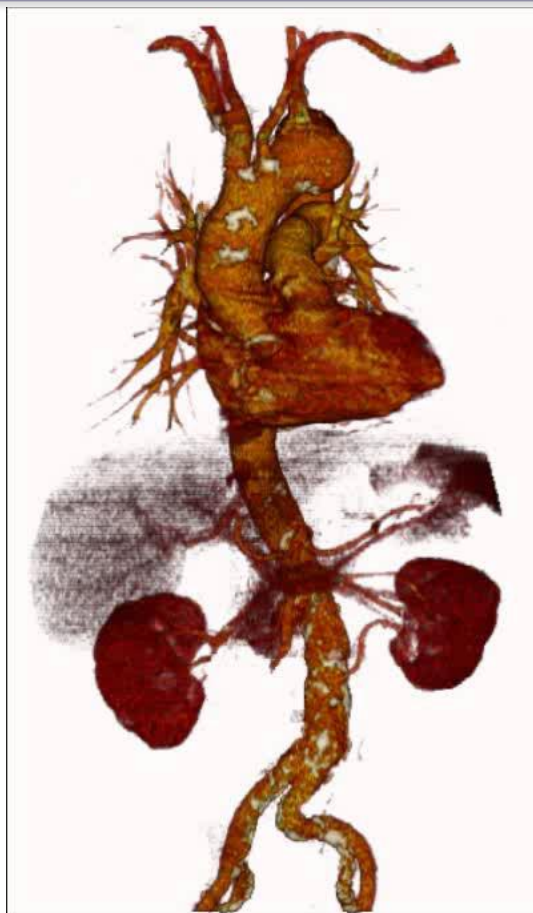
Recurrent thoracic pain

History of hypopharyngeal cancer with radiation and chemotherapy 07/2012

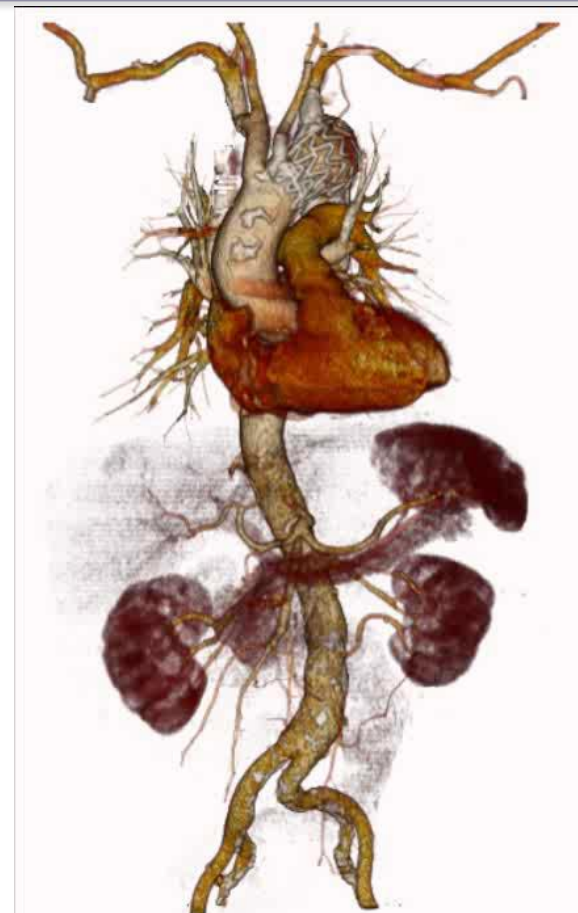
Radiation-induced dermal sclerosis (left neck)

Endovascular distal aortic arch repair using the chimney technique,

No limitation in daily life



26.05.2014



05.04.2016

Day 2 - 12.09.2014

Case 10: E-vita open  
Surg. H. G. Jakob

**Patient**

22 y/o male, 75 kg, 185 cm

Chronic type I aortic dissection

Left vertebral artery from the arch

Marfan syndrome

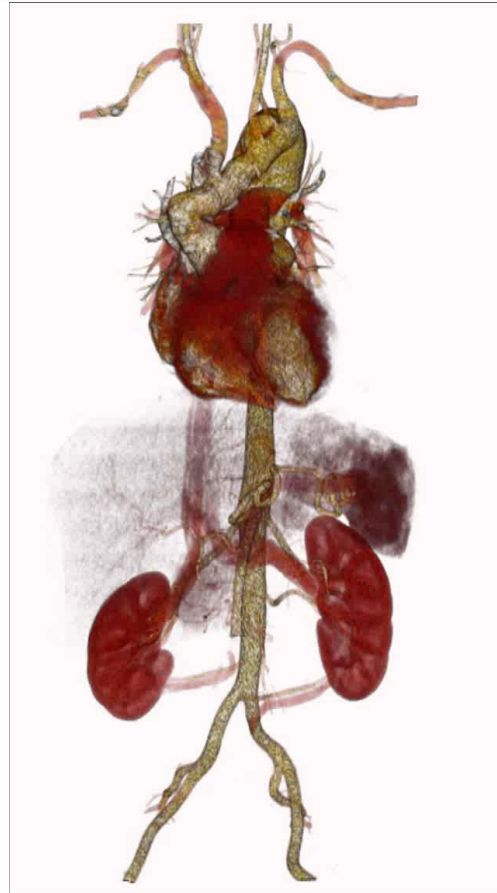
S/p Acute type I AD 07/2013

S/p mech. valve conduit, Hemiarch

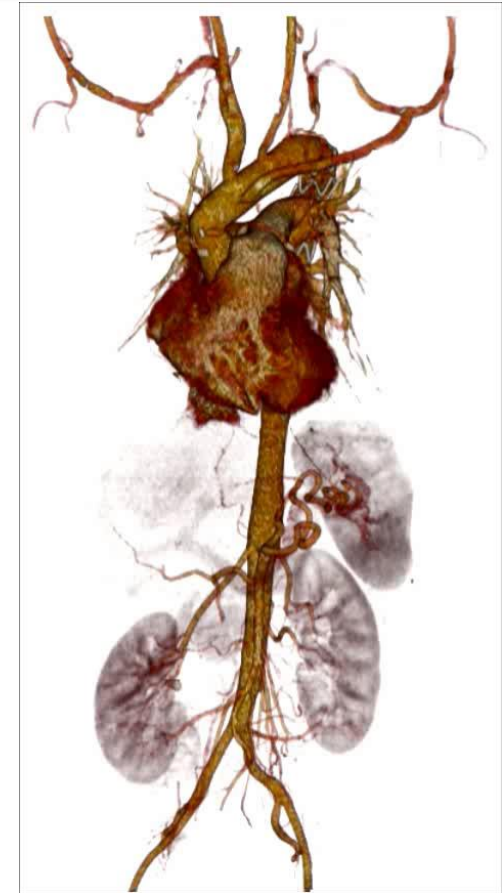
FET E-vita open

Prolonged postoperative stay,

Now back at University,  
studying



01.09.2014



14.09.2016

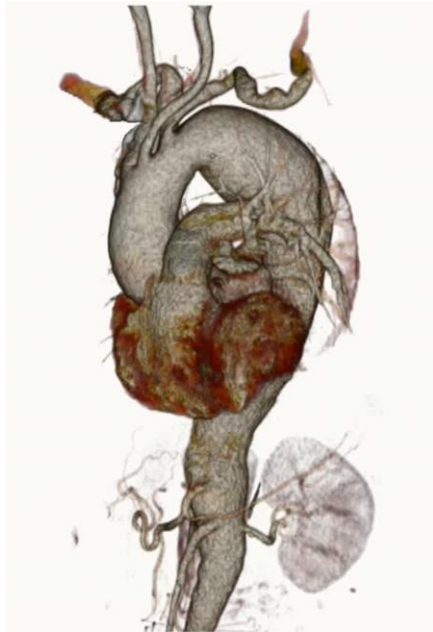Day 3 - 13.09.2014

Case 19: TAAA replacement  
Surg. H. J. Safi


**Patient**

59 y/o female, 54 kg, 165 cm

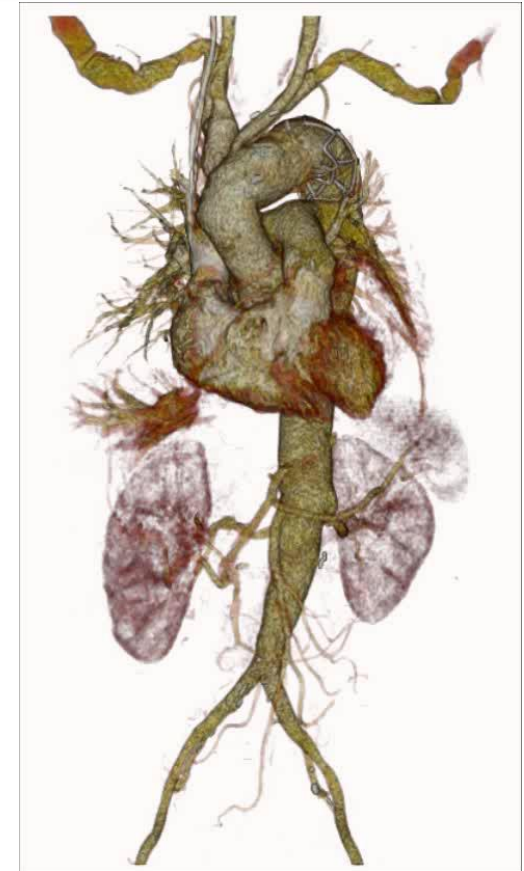
Generalized aortic aneurysm



30.01.2014

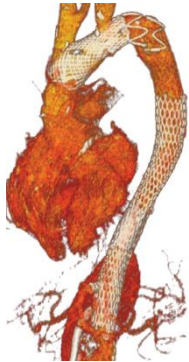
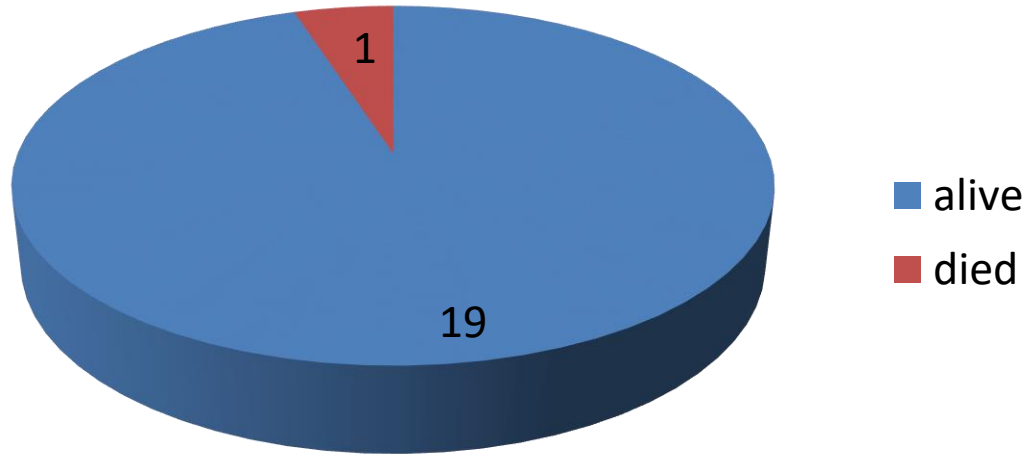


03.08.2014



10.03.2016

### Cases Outcome 2014



**AORTIC LIVE**

September 11-13, 2014

**2**