AV repair vs replacement: advantages and limitations

Hans-H. Sievers

Department of Cardiac and Thoracic Vascular Surgery,

University of Lübeck

Disclosure

Speaker name: Hans-H. Sievers

.....

I have the following potential conflicts of interest to report:

- ☐ Consulting
- ☐ Employment in industry
- ☐ Stockholder of a healthcare company
- ☐ Owner of a healthcare company
- ☒ Other(s)

- ☐ I do not have any potential conflict of interest

Anatomy of the aortic valve

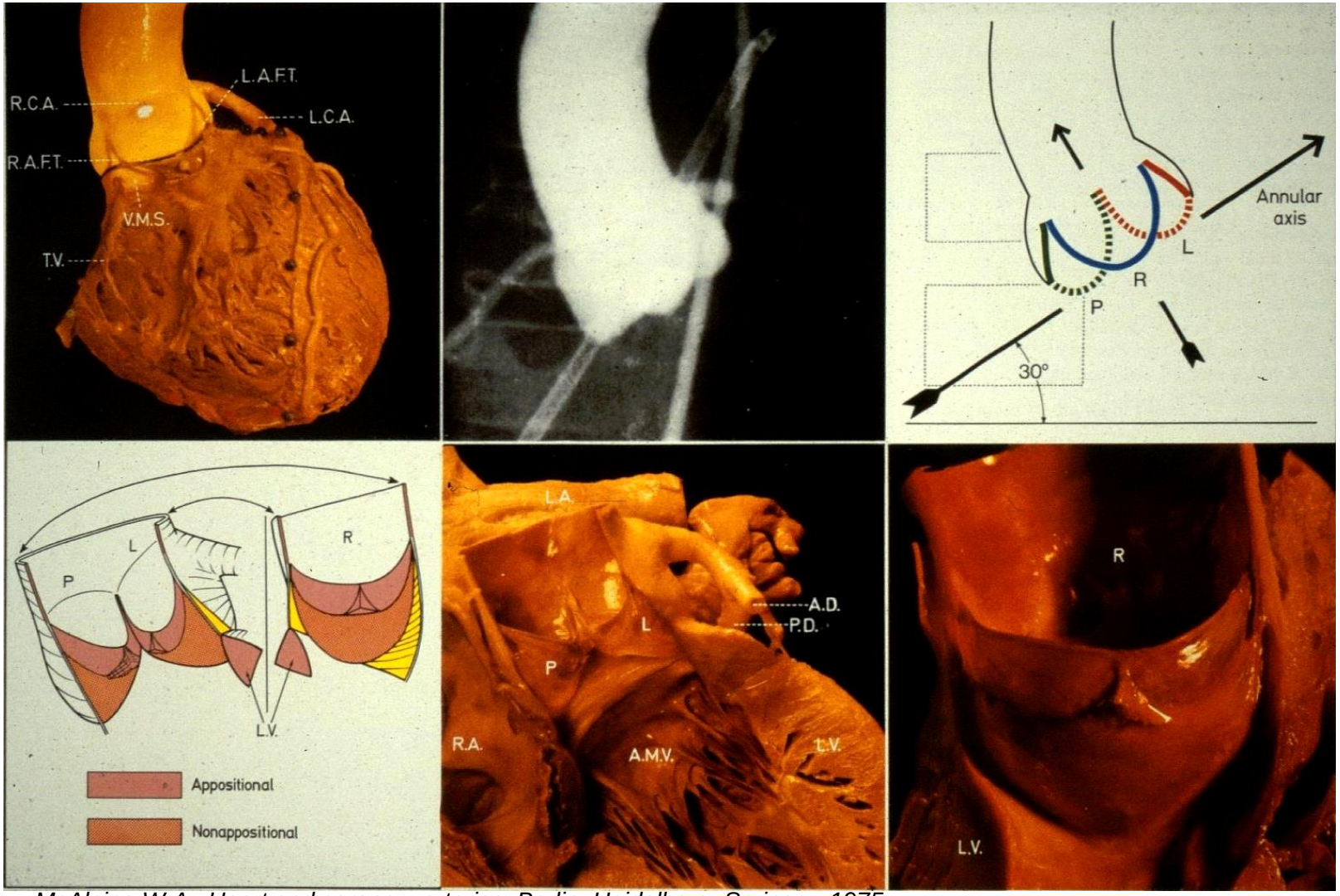

McAlpine W.A.: Heart and coronary arteries. Berlin, Heidelberg: Springer, 1975

eine Einheit = Leaflet + Sinus

Aortic valve: endoscopic view at 80 mmHg

A

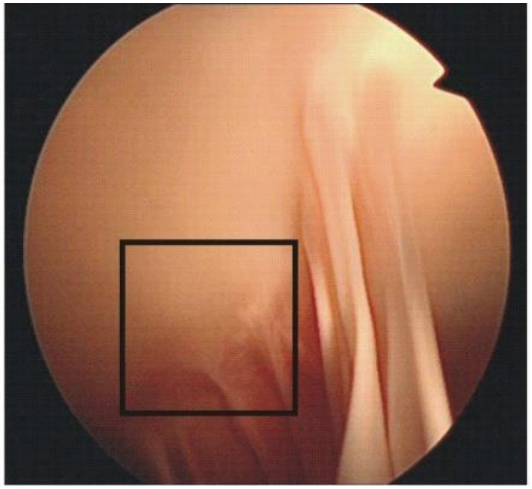

B

C

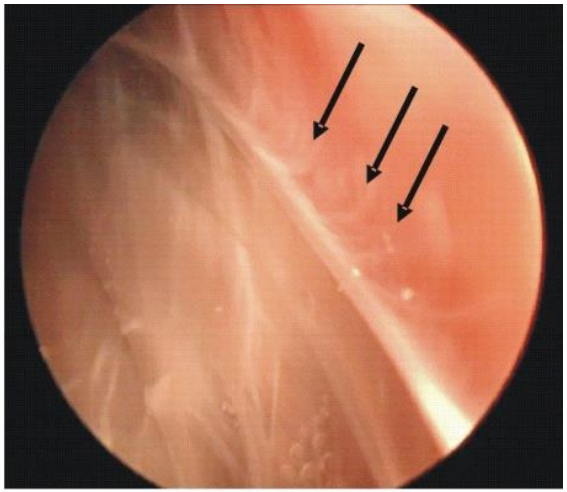

A: Endoscopic view into the sinus of Valsalva of a pressurized porcine aortic root.

B: Near the annulus strong collagen fibers bear thin hammock-shaped membranes (Insert of A).

C: Smaller collagen fibers are embedded in these membranes (arrows).

Sievers HH J Thorac Cardiovasc Surg. 2007;134:20-22.

Collagenous Cords in the Aortic/Pulmonary Valve

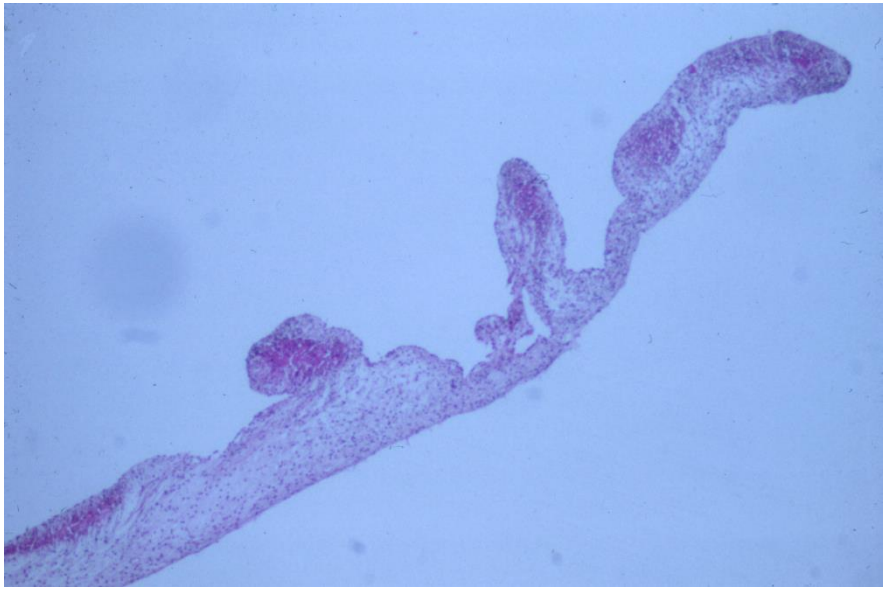

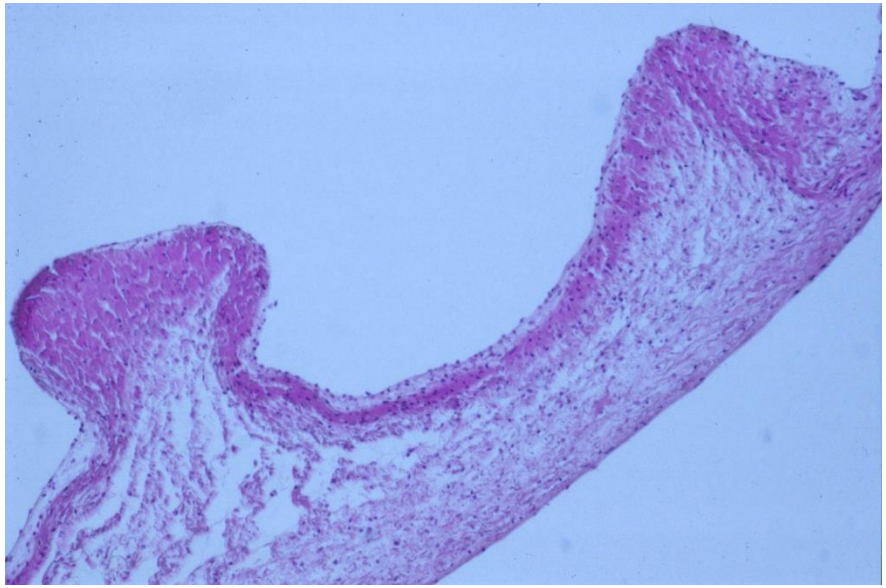



red = collagenous fibres

wavy configuration/ stress absorption

Fastenrath, S. Texture of collagenous fibres of the Aortic/Pulmonary Valve, Thesis 1995 University of Kiel.

A Photomicrograph of a porcine aortic valve leaflet

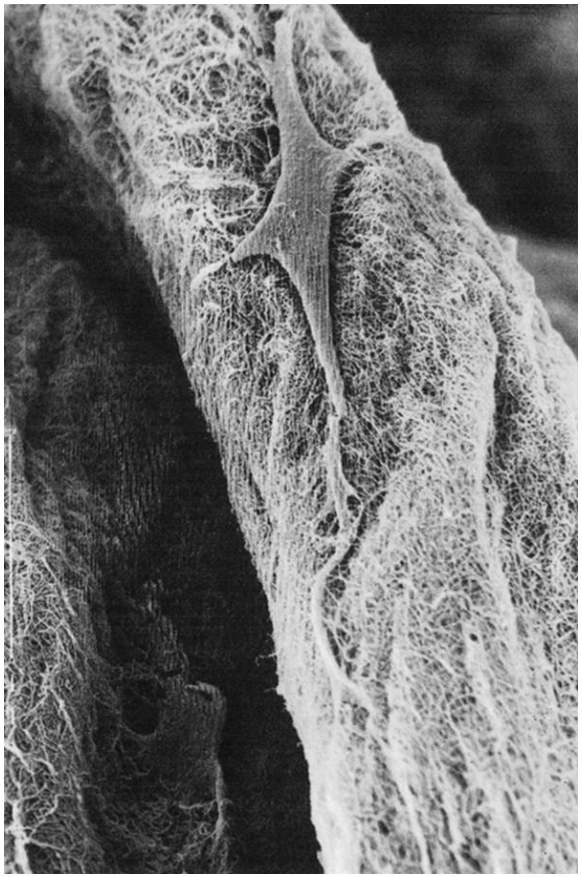

Scanning electron micrograph of a human aortic valve interstitial cell on collagen fiber showing 3D shape and long cellular extensions

Yacoub, M. H. et al. Circulation 2004;109:942-950

Taylor PM et al. J Heart Valve Dis. 2002; 11: 298–306

Double-label immunofluorescence micrographs of cultured VICs from ovine heart valve

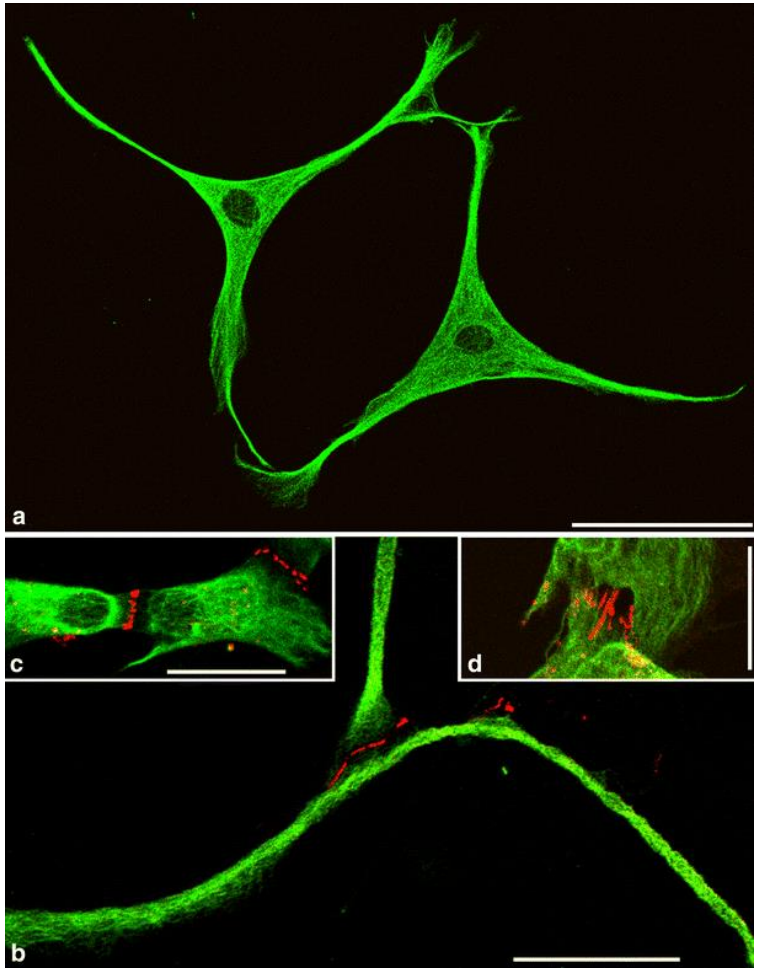

a Typical micrograph of early contacts of two ovine VICs (*green* cytoplasmic filament meshwork stained with antibody against vimentin), forming contacts with their opposing processes.

b Battery of AJs, visualized by immunostaining with antibodies to N-cadherin (*red, transmembrane glycoprotein)*), at the end of a cell process and forming an extended AJ-rich area with the middle segment of a long cell process (exceeding 150 µm).

c, **d** Established batteries of AJs (adhering junctions) (*red* staining with antibodies against N-cadherin) between adjacent VICs are presented either as a punctate series (**c**) or as a group of AJ-positive cell-cell bridges (**d**). *Bars* 100 µm (**a**), 25 µm (**b-d**)

Barth M. et al. Cell Tissue Res 2009; 337:63-77

Aortic Valve Function
ventricular – atrial – valvular coupling

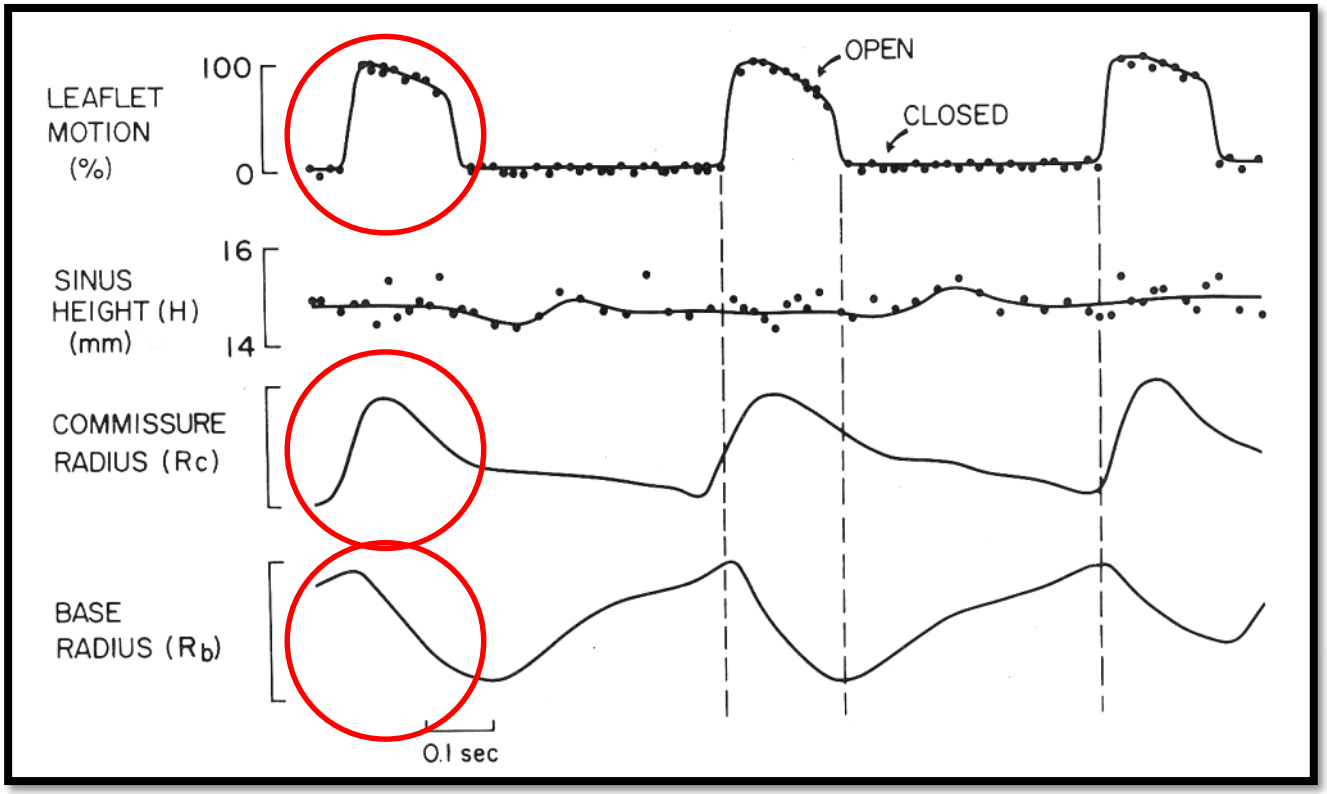

Continuous plot of leaflet motion, sinus height, commissure radius, and a base radius vs. time. Each data point on first two curves was obtained from a single video field.

Thubrikar M et al. Am J Physiol. 1981;241:H795-801.

All structures are distensible and functionally connected.

Conclusion

Nature is the optimal solution for the aortic valve to warrant lifelong function.

➔ This is a call for REPAIR whenever possible.




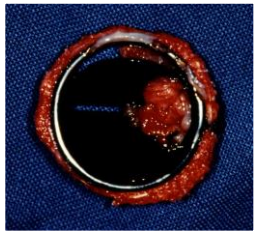

Patients outcome after aortic valve replacement with a mechanical or biological prosthesis: Weighing lifetime anticoagulation-related event risk against reoperations risk

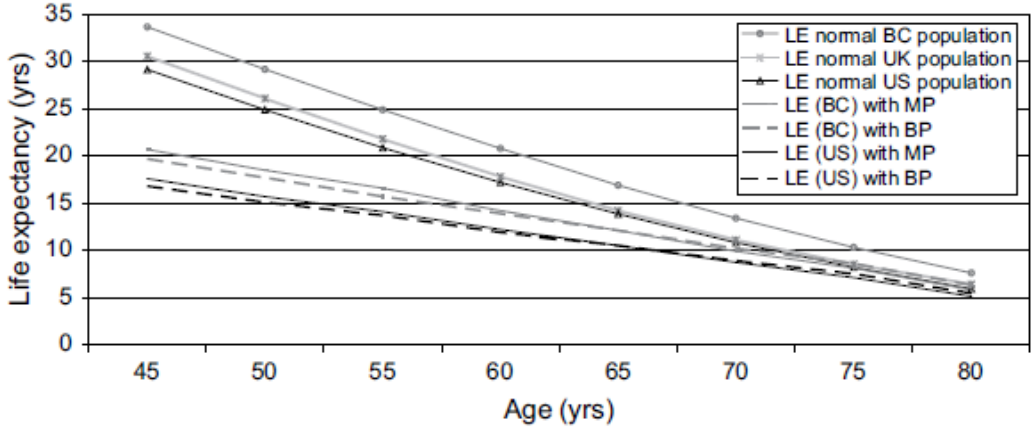

Life expectancy in men of different ages in British Columbia (BC), Canada, the United Kingdom (UK), and the United States (US) versus life expectancy after AVR in British Columbia and the United States. LE, Life expectancy; MP, mechanical prosthesis; BP, biological prosthesis

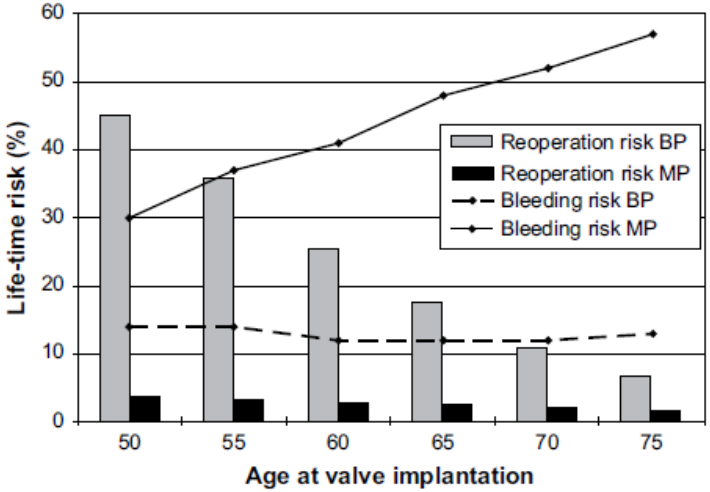

Lifetime risks of reoperation and bleeding after AVR with mechanical and bioprostheses.
BP, Bioprosthesis; MP, mechanical prosthesis

van Geldorp MWA et al. J Thorac Cardiovasc Surg 2009;137:881-6

Advantages and limitations of repair compared to replacement

	Repair	Replacement		
		Ross	Bioprosthesis	Mechanical valve
Thromboembolism	+	+	(+)	-
Bleeding	+	+	+	-
Noise	+	+	+	-
Lifestyle restriction	+	+	+	(+)
Survival relative to normal (long-term)	(+)?	(+)?	(-)??	(+)?
Durability	+??	+?	+???	+
Function	+	+	(+)?	(+)
Complex operation	-	-	+	+

Repair

Complex operation

Topics of repair

- Understanding anatomy and function
- Decide which technique
- Surgical technique itself
- Material
- Assessment of leaflet quality

Aims

- Normal leaflet mobility
- Adequate coaptation area
- Stable annulus + STJ

Understanding anatomy and function

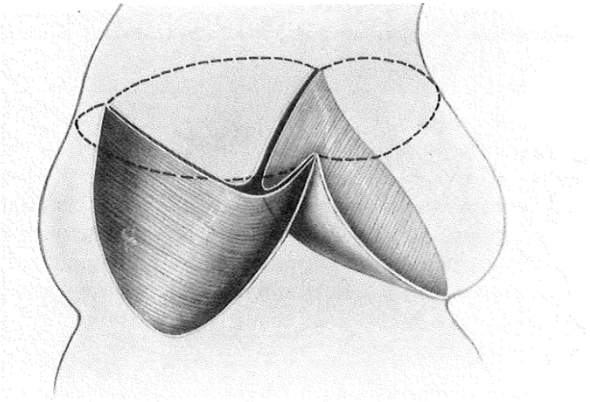

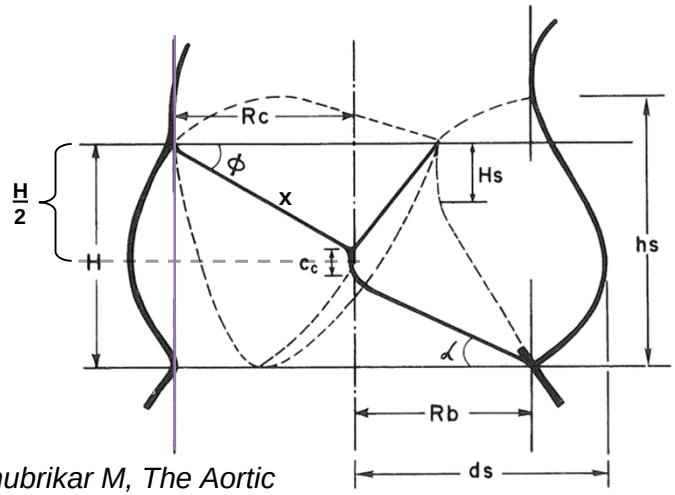

Thubrikar M, The Aortic Valve, CRC Press Inc., 1990

Optimal valve (Thubrikar)

$H\ Man: 12 - 14\ mm$
$Rc\ Man \sim 10\ mm$

$$Rc^2 + \left(\frac{H}{2}\right)^2 = x^2$$
$$Rc = R = 10$$
$$\frac{H}{2} \sim 6{,}5 \sim \frac{R * 6{,}5}{10} = 0{,}65\ R$$
$$R^2 + (0{,}65R)^2 = x^2$$
$$1{,}43R^2 = x^2$$
$$x = 1{,}2\ R$$
$$d.h.\ x\ ist\ ca. 20\%\ länger\ als\ R$$
$$x \sim \frac{1}{2} TL\ (Taschenlänge)$$
$$2x = 1TL = 2 * 1{,}2R$$

$$\boldsymbol{TL \sim 2{,}4R = 1{,}2D}$$

gemessen mit 2,4 – 2,6 R

Swanson et al.
Sands et al.
Silver et al.

Understanding anatomy and function

Annahme: BAV Anatomie = TAV Anatomie

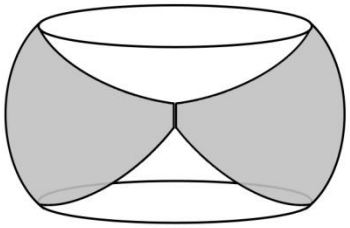

TL=2,4R = 1,2D

Diastole:

Klappe suffizient

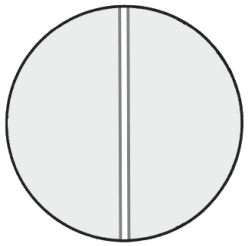

Systole:

+ ca. 10% STJ-Expansion

d.h.: B =

$$\frac{1{,}1D\ \pi}{2} = \underline{1{,}73D}$$

TL = 2,4R = <u>1,2D</u>

B = 1,73D; TL = 1,2D ➔

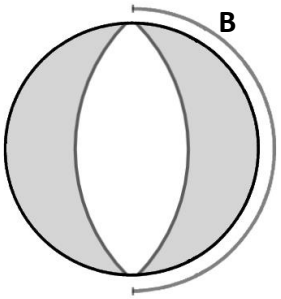

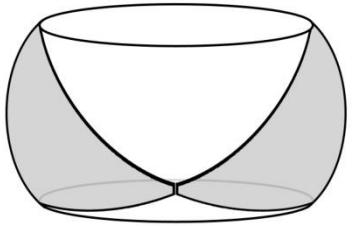

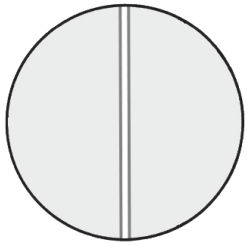

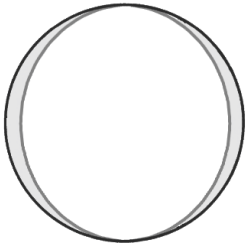

Wenn die bicuspide Klappe nicht stenotisch sein soll und eine Distensibility von 10 % vorliegt, muss TL~1,7D sein, d.h. die Koaptationsfläche liegt eher in Annulusnähe wenn der freie Rand symmetrisch ohne Faltenbildung gestaltet wird.

sehr kleine Koaptationsfläche
prä-Prolaps Zustand
extrem empfindlich auf Annulusdilatation (wichtig: Annulus-reduktion + Stabilisierung)

D.h. bikuspide ist immer stenotisch, um so mehr je höher der freie ungefaltete Taschenrand in der STJ-Ebene zu liegen kommt

Techniques of repair depending on the primary lesion

- Leaflets only
- STJ ± leaflet
- Sinus ± leaflet → Remodeling (Yacoub) Diameter < 28 mm
- Sinus + annulus ± leaflet → Reimplantation (David) Diameter > 28 mm

Two valve sparing root replacement techniques

Remodeling (Yacoub)



Reimplantation (David)

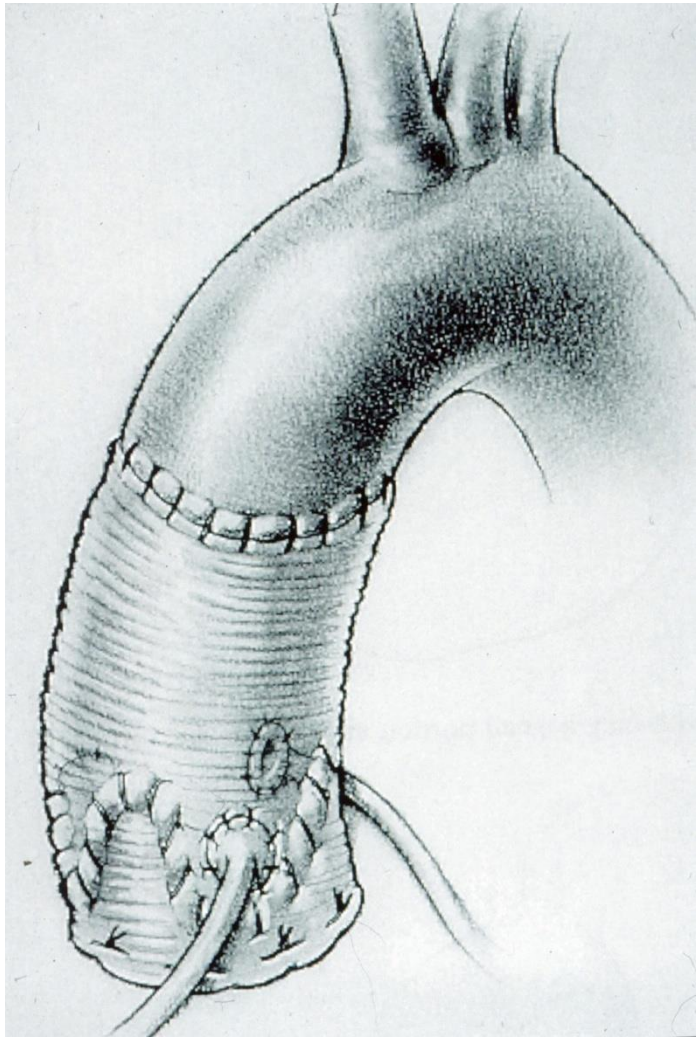

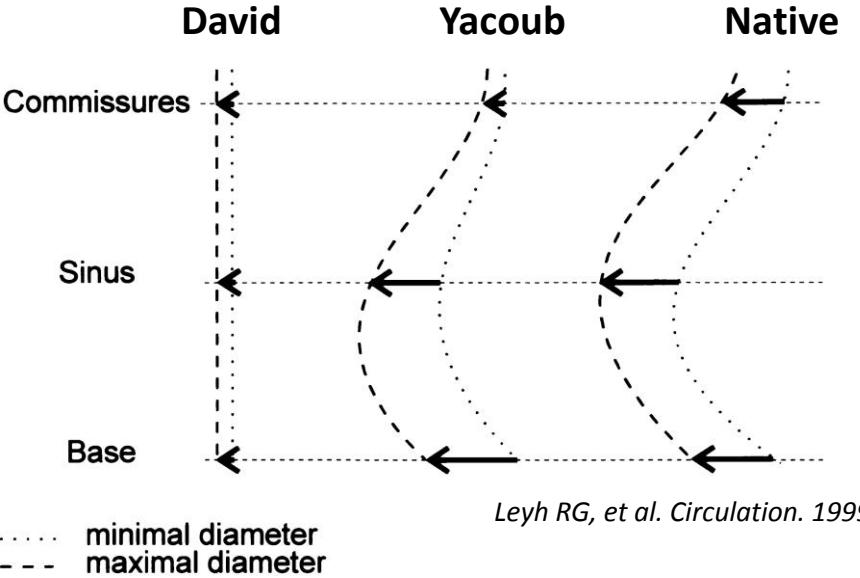

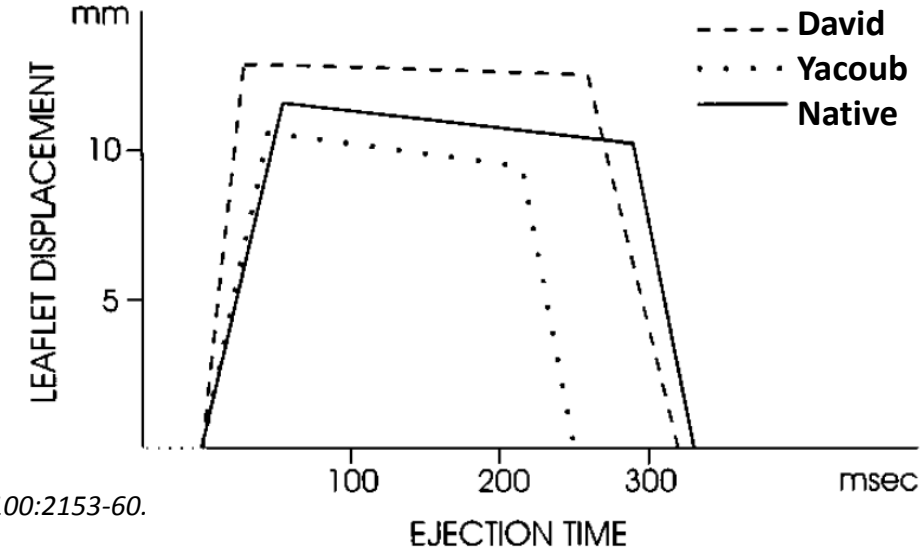

Leyh RG, et al. Circulation. 1999;100:2153-60.

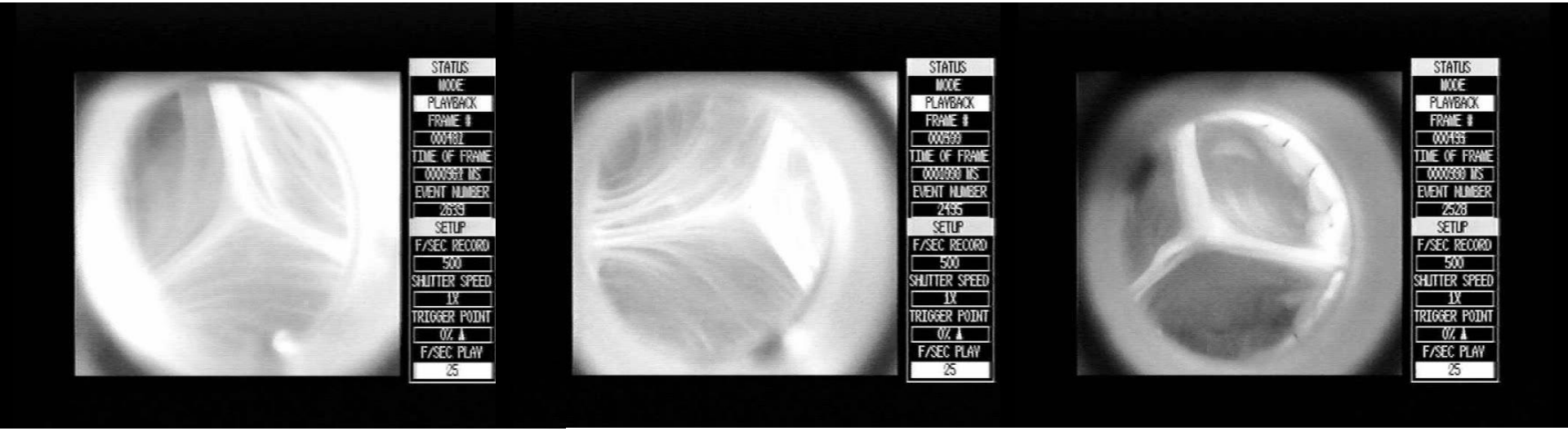

Native root **Remodeling (Yacoub)** **Reimplantation (David)**

Yacoub more physiological than David

Material

- Straight tube
- Sinus prosthesis

Is a Sinus in the prosthesis necessary? Role of Sinuses of Valsalva

- Proper and timely valve opening and closure [1-2]
- Stabilize leaflets in open position[3]
- Minimize leaflet stress[4]
- Minimize transvalvular pressure gradients[5]
- Promote coronary flow[6]

Uni-Graft® W SINUS,
Braun Melsungen, Germany

[1] Robicsek F et al. Ann Thorac Surg. 2002;73:1346-54.
[2] Katayama S et al. J Thorac Cardiovasc Surg. 2008;136:1528-35, 1535.e1.
[3] Caro C et al. The Mechanics of Circulation, Cambridge University Press, 2012.
[4] Grande-Allen KJ et al. J Thorac Cardiovasc Surg. 2000;119:753-63.
[5] Pisani G et al. J Thorac Cardiovasc Surg. 2013;145:999-1003.
[6] Bellhouse BJ et al. Nature. 1968;219:1059-61.

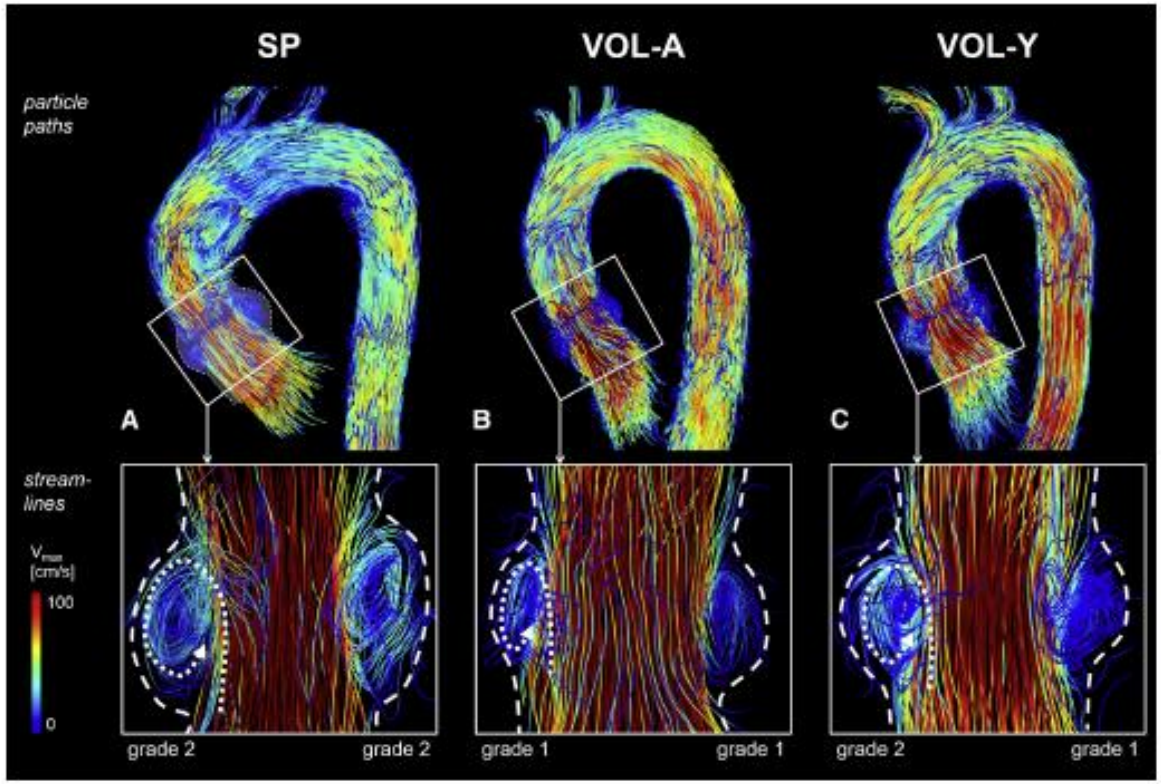

FIGURE 3. Sinus vortices. *Top row*: particle paths at peak systole delineate hemodynamics in the thoracic aorta of 60-year-old patient with SP (A), of a healthy 53-year-old VOL-A (B), and a 30-year-old VOL-Y (C). *Bottom row*: sinus vortices in the right and left coronary sinus as visualized by instantaneous streamlines. Sinus vortices develop behind the opened valve cusp in each coronary sinus during systole and persist until early diastole. Vortices in patients had a similar configuration than those in volunteers. *Dashed lines* are used to emphasize sinus borders and *dotted lines* to underline vortex direction. *SP*, Sinus prosthesis; *VOL-A*, age-matched volunteers; *VOL-Y*, young volunteers; *Vmax*, peak velocity.

Normal Sinus vortices with Uni-Graft® W SINUS prosthesis

Oechtering T et al. J Thorac Cardiovasc Surg. 2016; 152: 418-428

Sinus reduces bending deformation stress on leaflets

David OP
straight tube

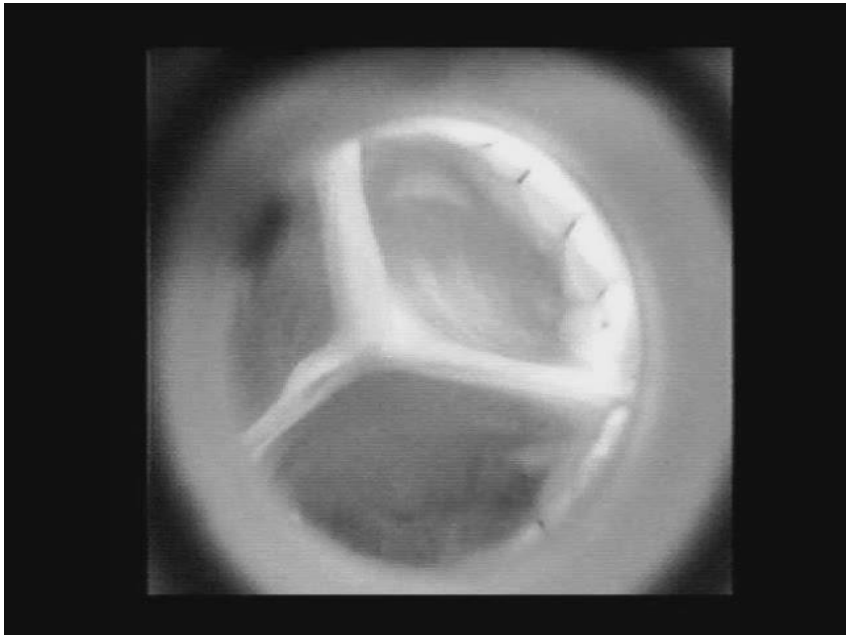

David OP
Uni-Graft® W SINUS prosthesis

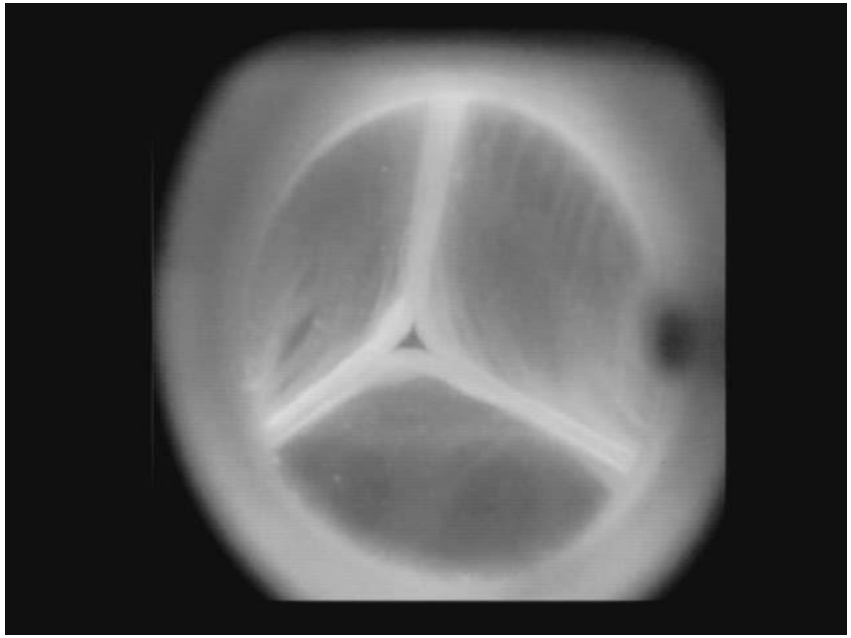

Less bending deformation of the leaflets in the Sinus prosthesis compared to a straight tube.

Crucial issue:

Assessment of leaflet quality

- Echo
- MRI
- **Mainly eyeballing during operation (Decision of the surgeon)**

Repair

Normal looking leaflets, Tricuspid valve

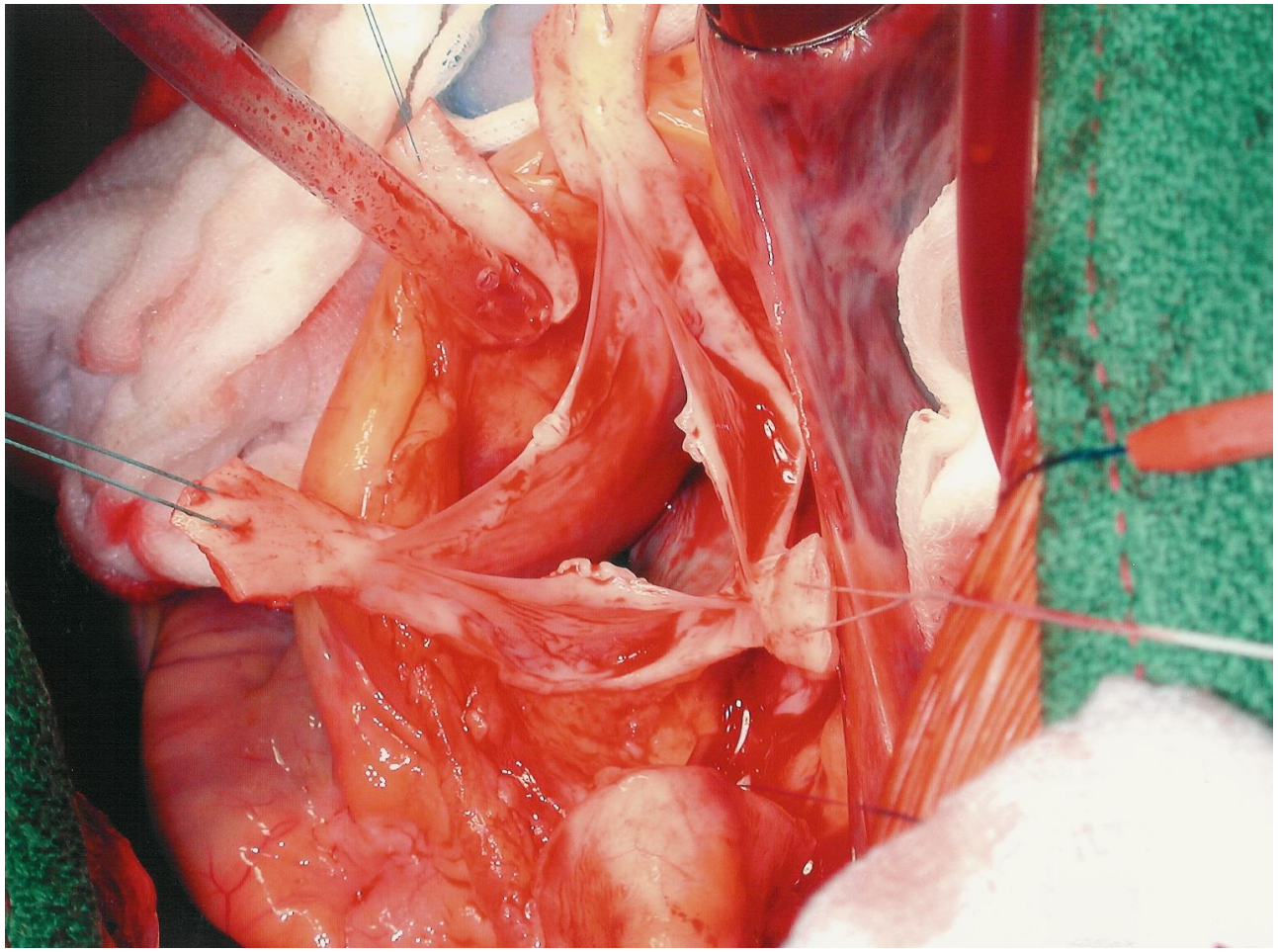

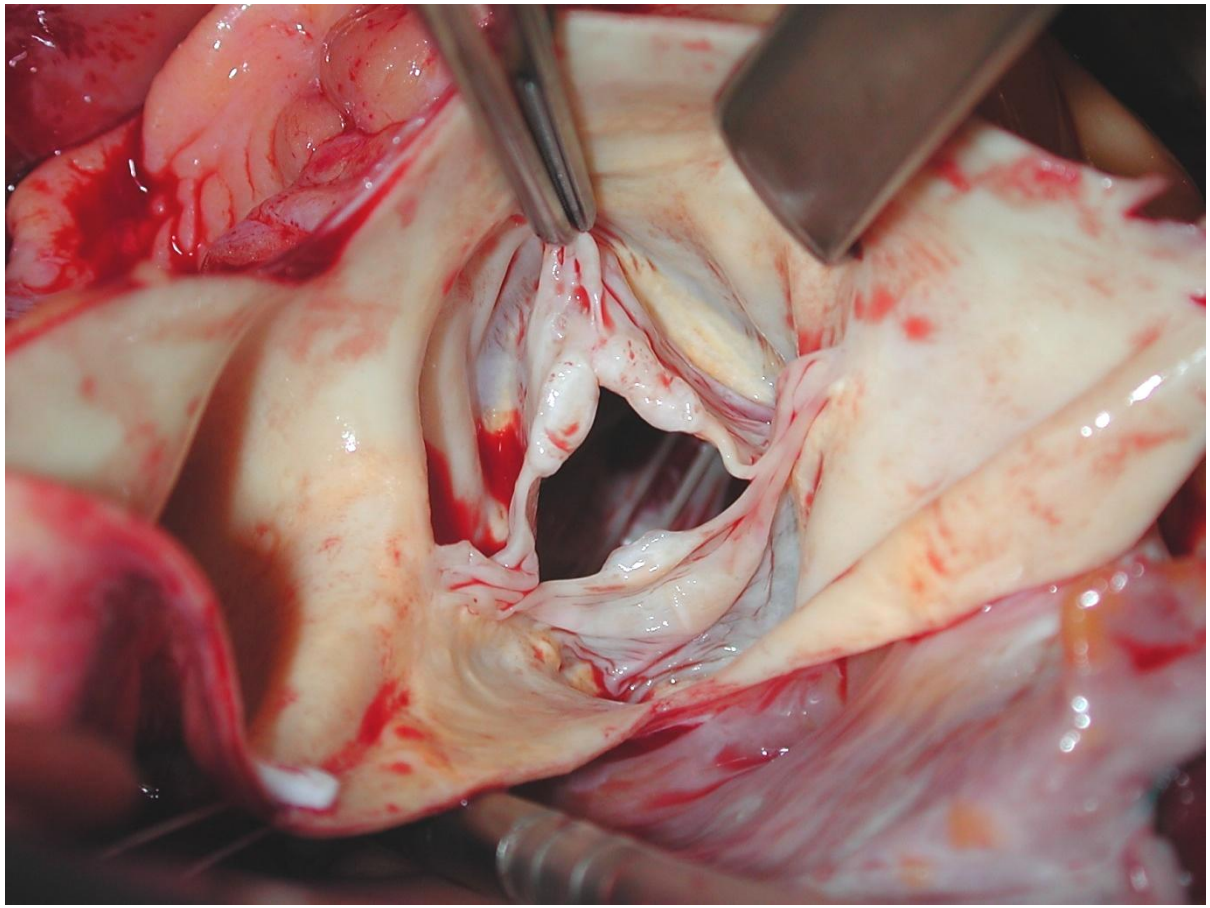

Type 1 L/R BAV

Repair

Sievers HH et al. J Thorac Cardiovasc Surg.2007;133:1226-1233

Post endocarditis hole

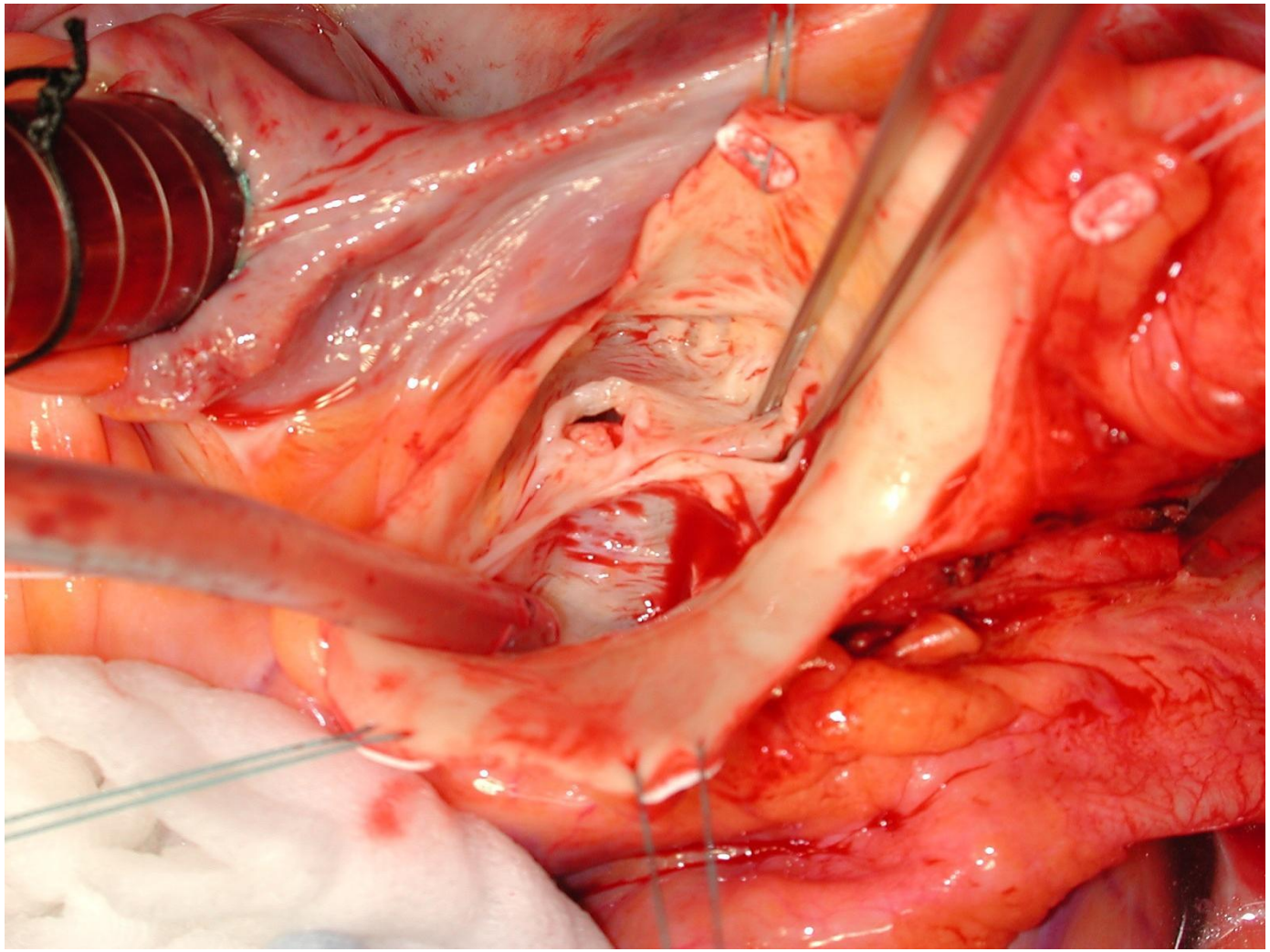

Repair

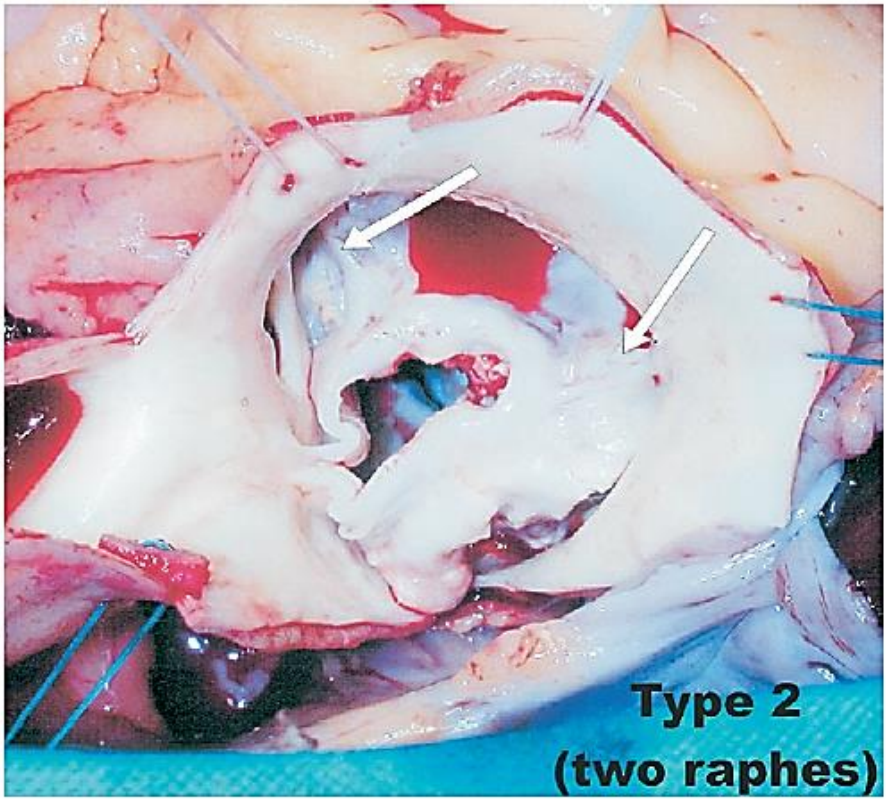

Figure 5. Intraoperative picture of a bicuspid aortic valve type 2, L/R-R/N, S (see text and Table 1 for explanation) with two raphes *(arrows)* but developmental anlagen of three cusps with a high degree of stenosis.

Type 2/unicuspid BAV

?

➔ rather replace

Sievers HH et al. J Thorac Cardiovasc Surg.2007;133:1226-1233

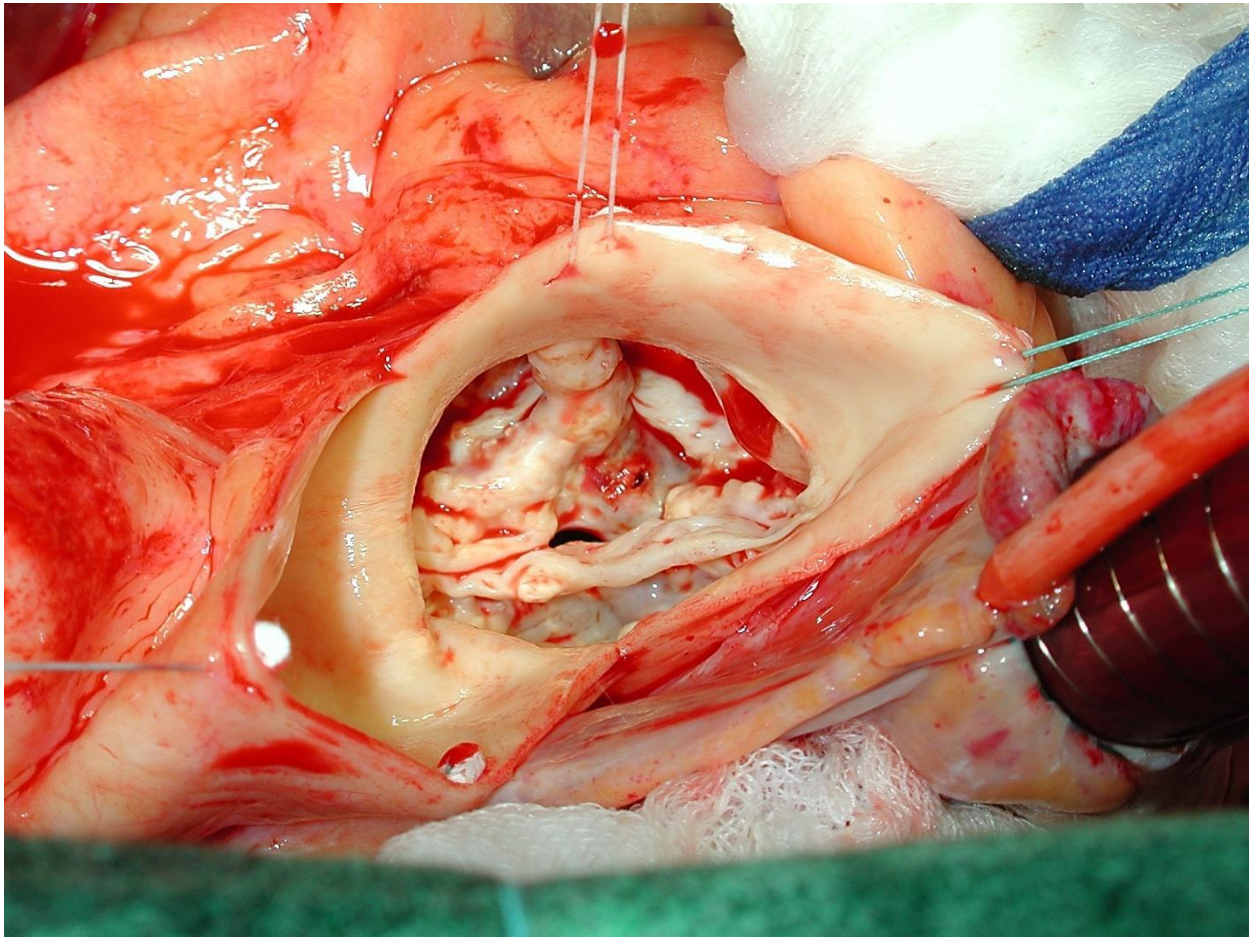

Type 1 BAV

Replacement

Ross

Fenestration?

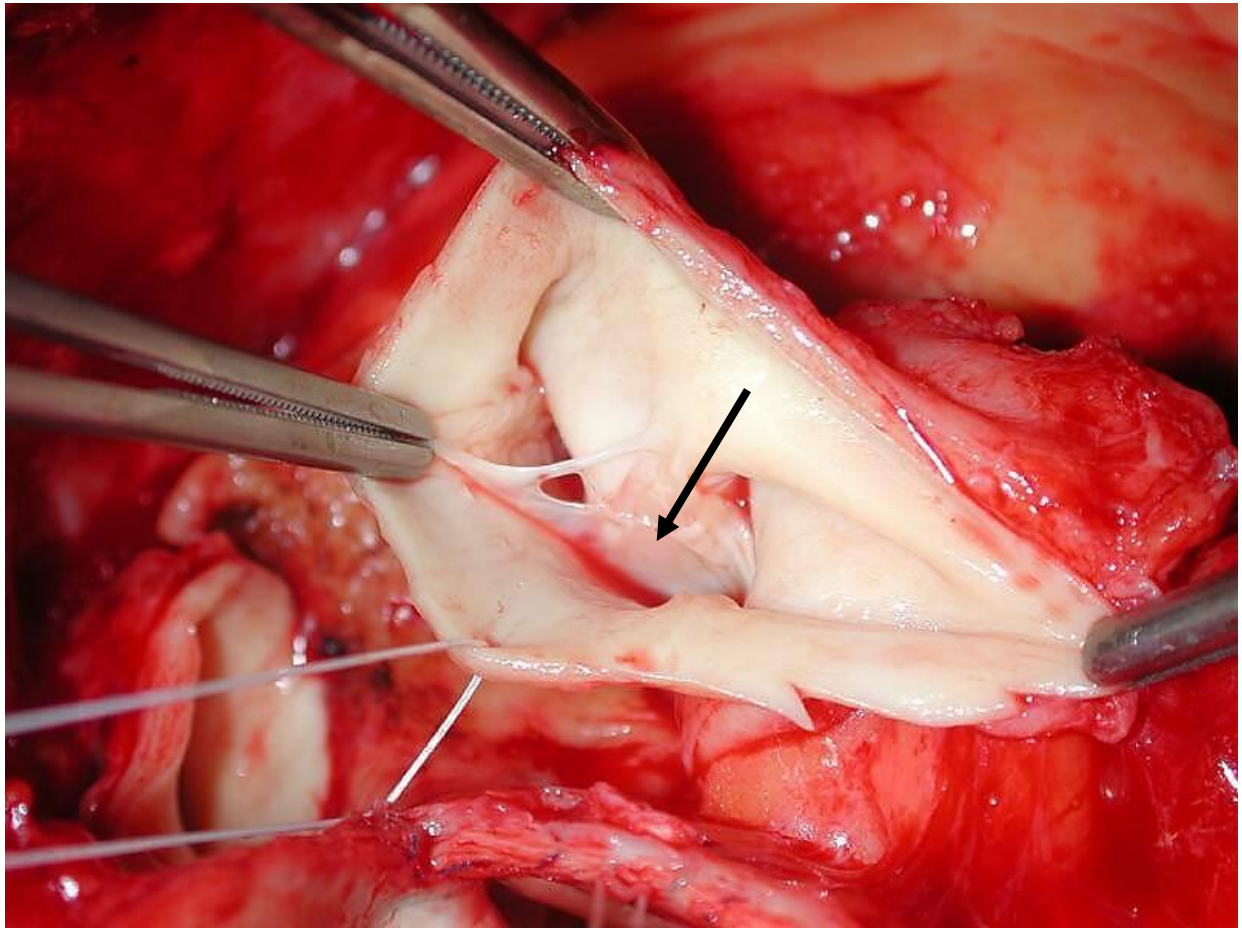

?

Thinned leaflets?

?

Techniques

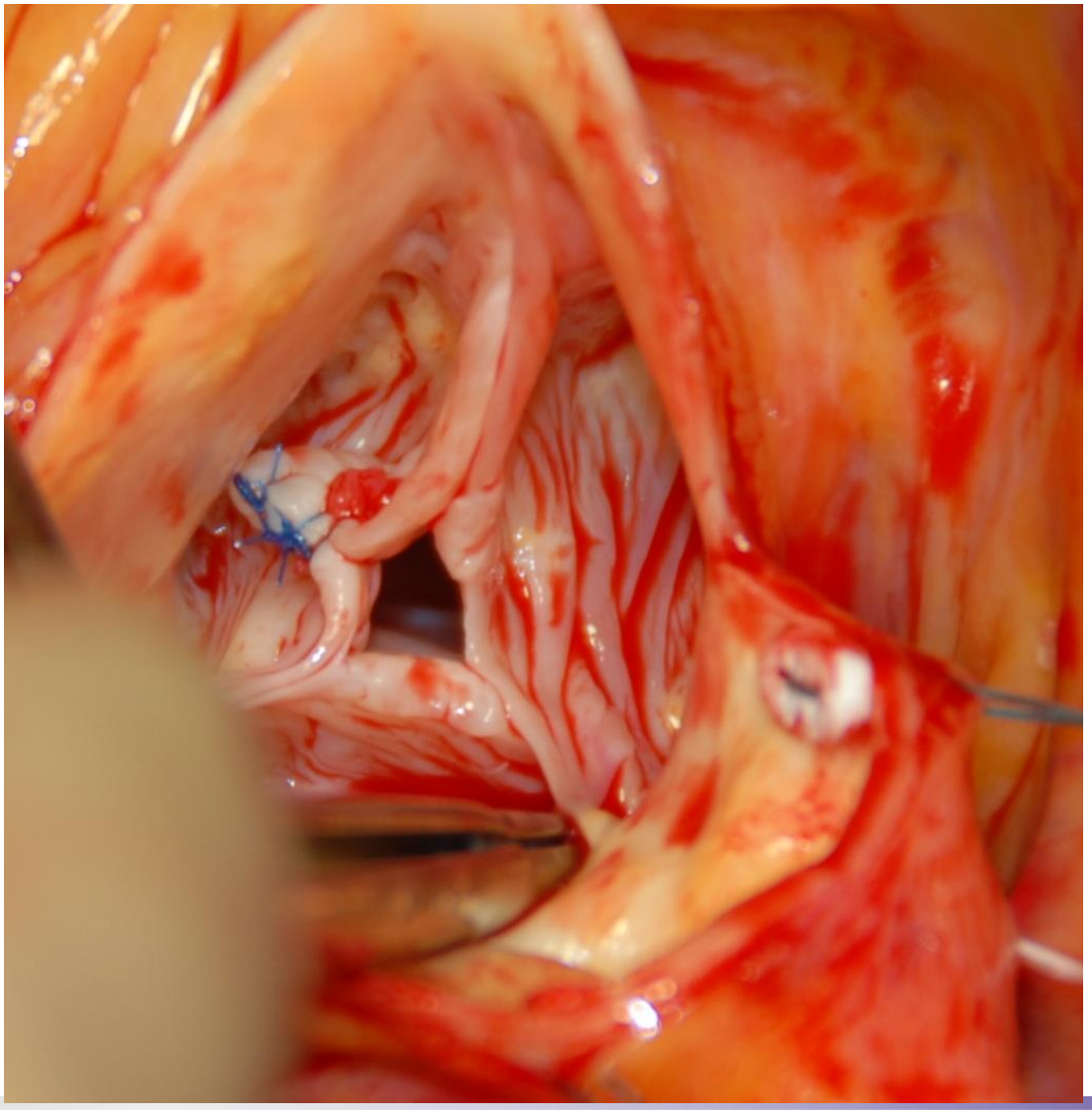

Central plication

Techniques

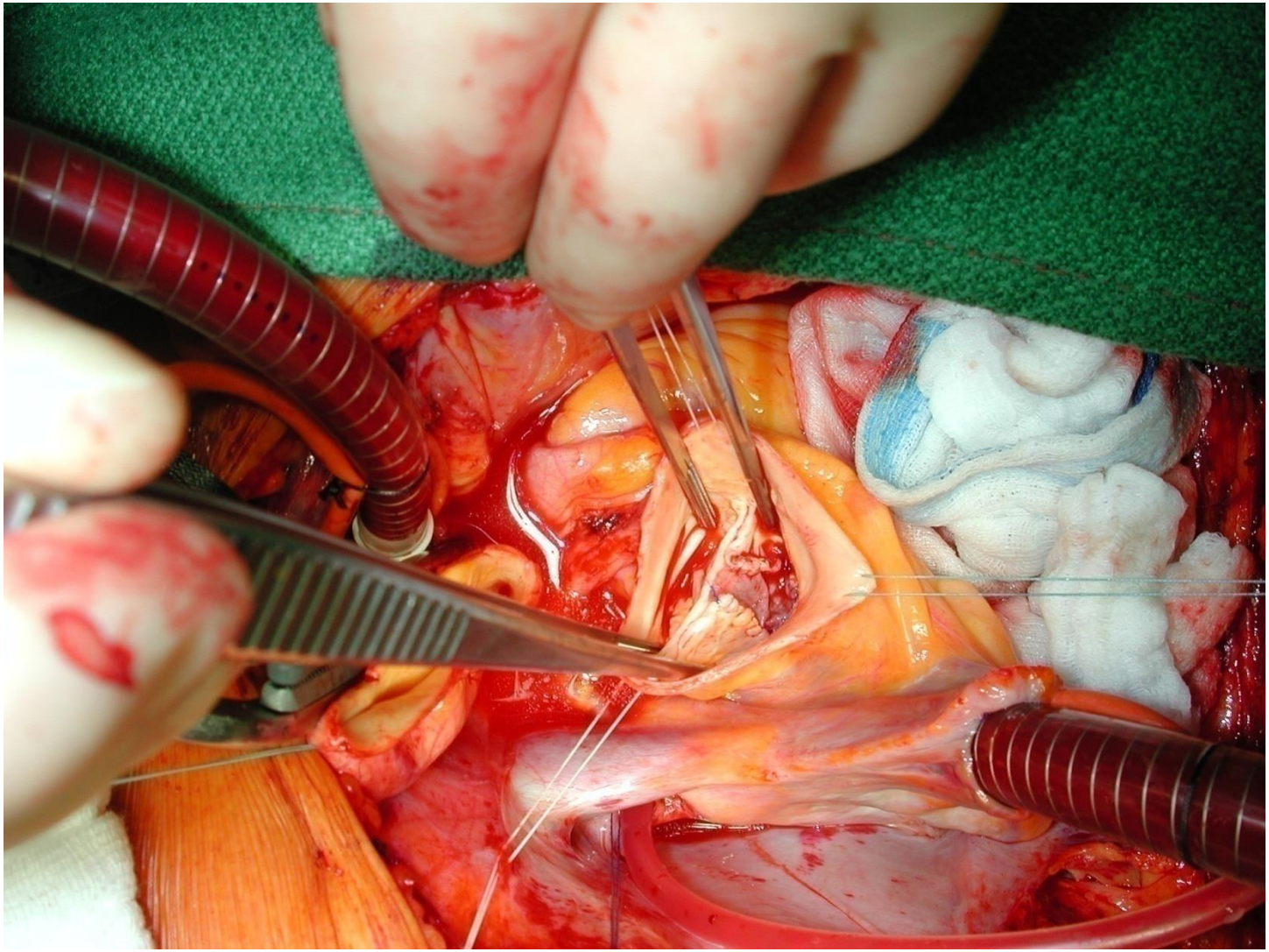

Replacement of raphe with pericardium

Techniques

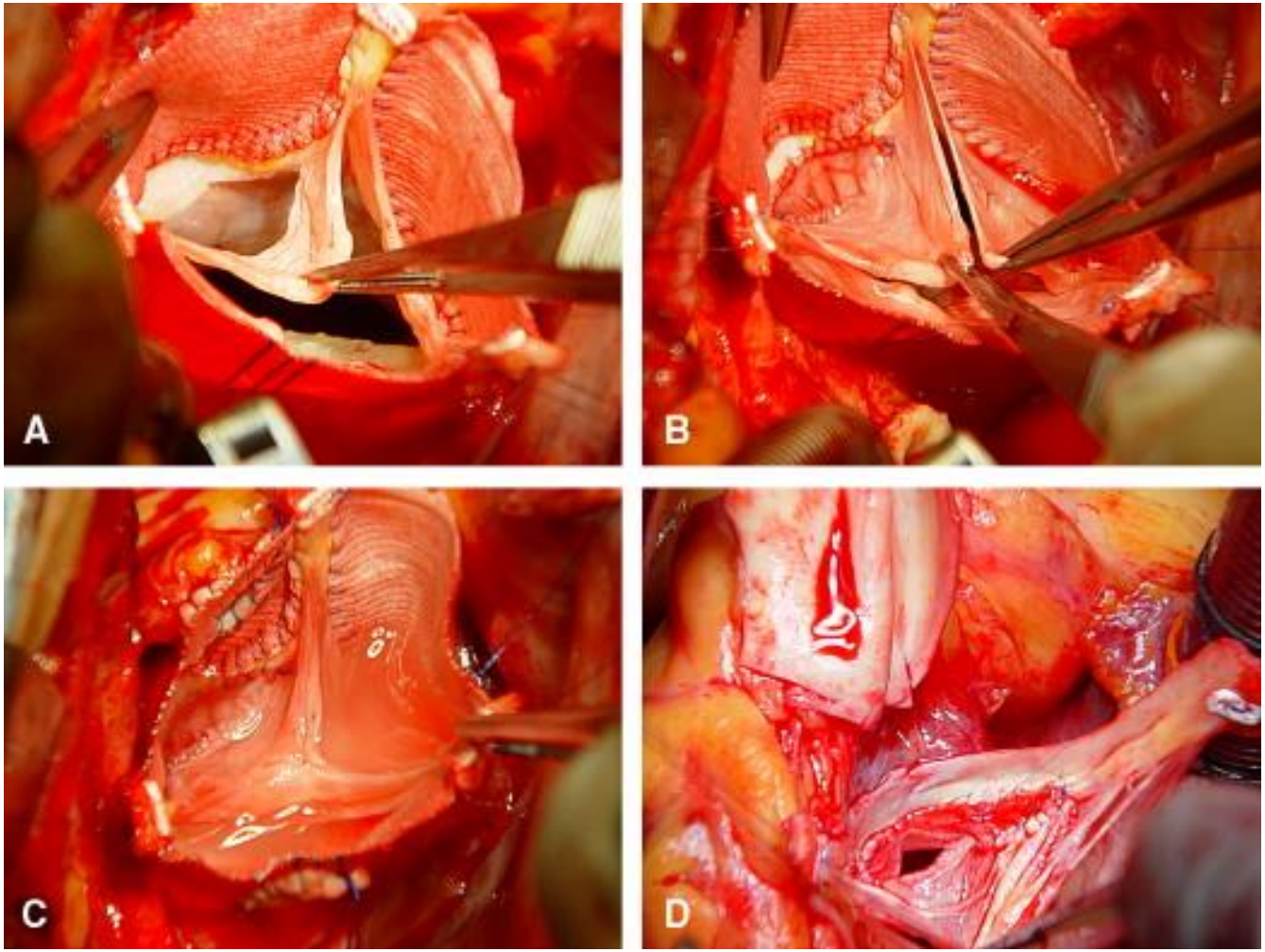

Intraoperative photographs showing basal cusp enlargement with pericardial patch in patients operated on using single patch technique (A through C) and reimplantation technique (D).

Basic leaflet elongation

A, Incision at base of cusp;
B, pericardial patch sewn into cusp;
C, aortic valve view after completion of cusp enlargement;
D, cusp enlargement before reimplantation of valve into tube.

Urbanski PP. J Thorac Cardiovasc Surg. 2010 Jan;139:98-102.

Techniques

Tricuspidalization of BAV

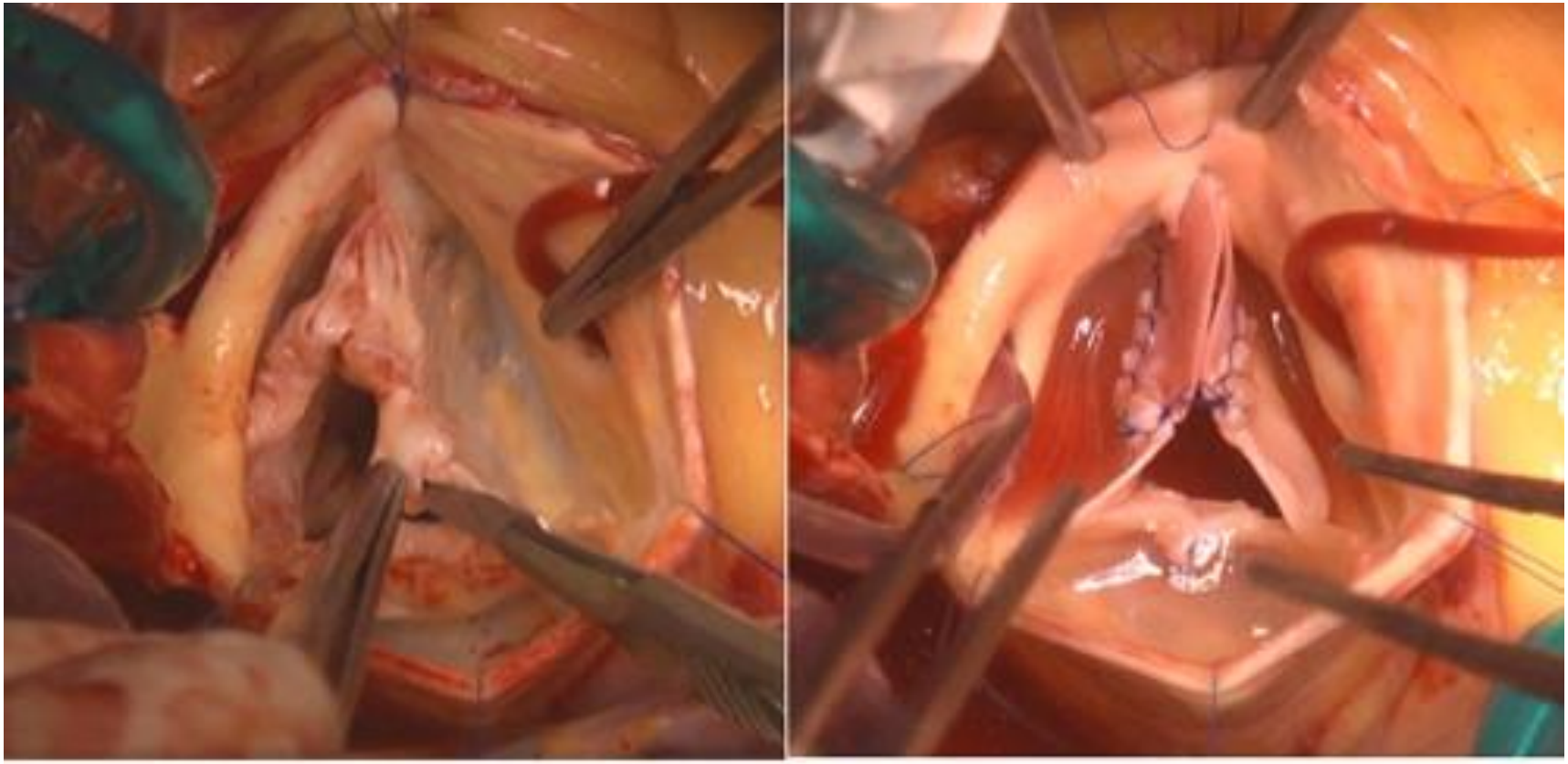

A Figure 1. A, Bicuspid aortic valve type I with restrictive raphe between the right and the left coronary cusps (left) and tricuspidization of the bicuspid aortic valve with the single-patch commissural reconstruction technique (right). A bovine pericardial patch is used to create a new commissure at the place of the raphe.

Vohra HA et al. J Thorac Cardiovasc Surg 2013;145:882-6

Techniques

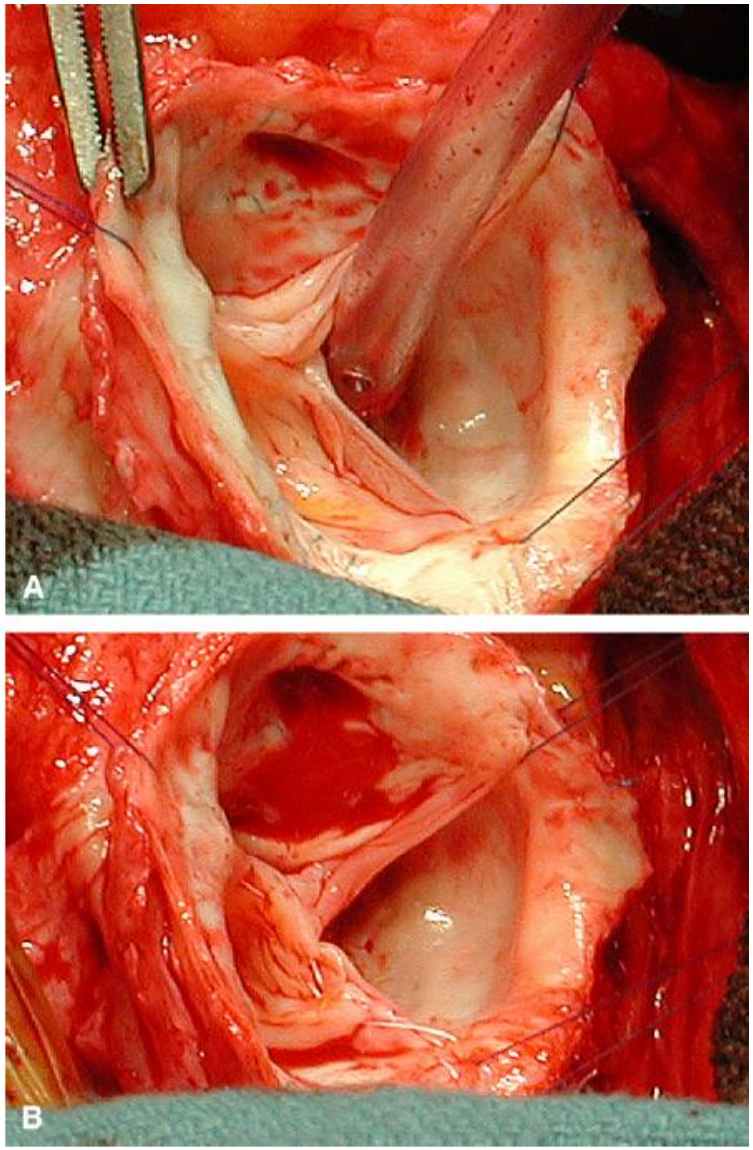

5/0 Gore suture for prolapse correction

FIGURE 2. A, Intraoperative photograph of a repaired noncoronary aortic cusp with polytetrafluoroethylene (Gore-Tex) suture 12.7 years after reimplantation of the aortic valve. The polytetrafluoroethylene (Gore-Tex) is invisible. The left cusp is prolapsing. B, The left cusp is repaired with a double layer of 6-0 polytetrafluoroethylene (Gore-Tex) suture.

David TE et al. J Thorac Cardiovasc Surg. 2010 May;139:1340-2.

Bicuspid aortic valve repair by complete conversion from "raphe'd" (type 1) to "symmetric" (type 0) morphology.

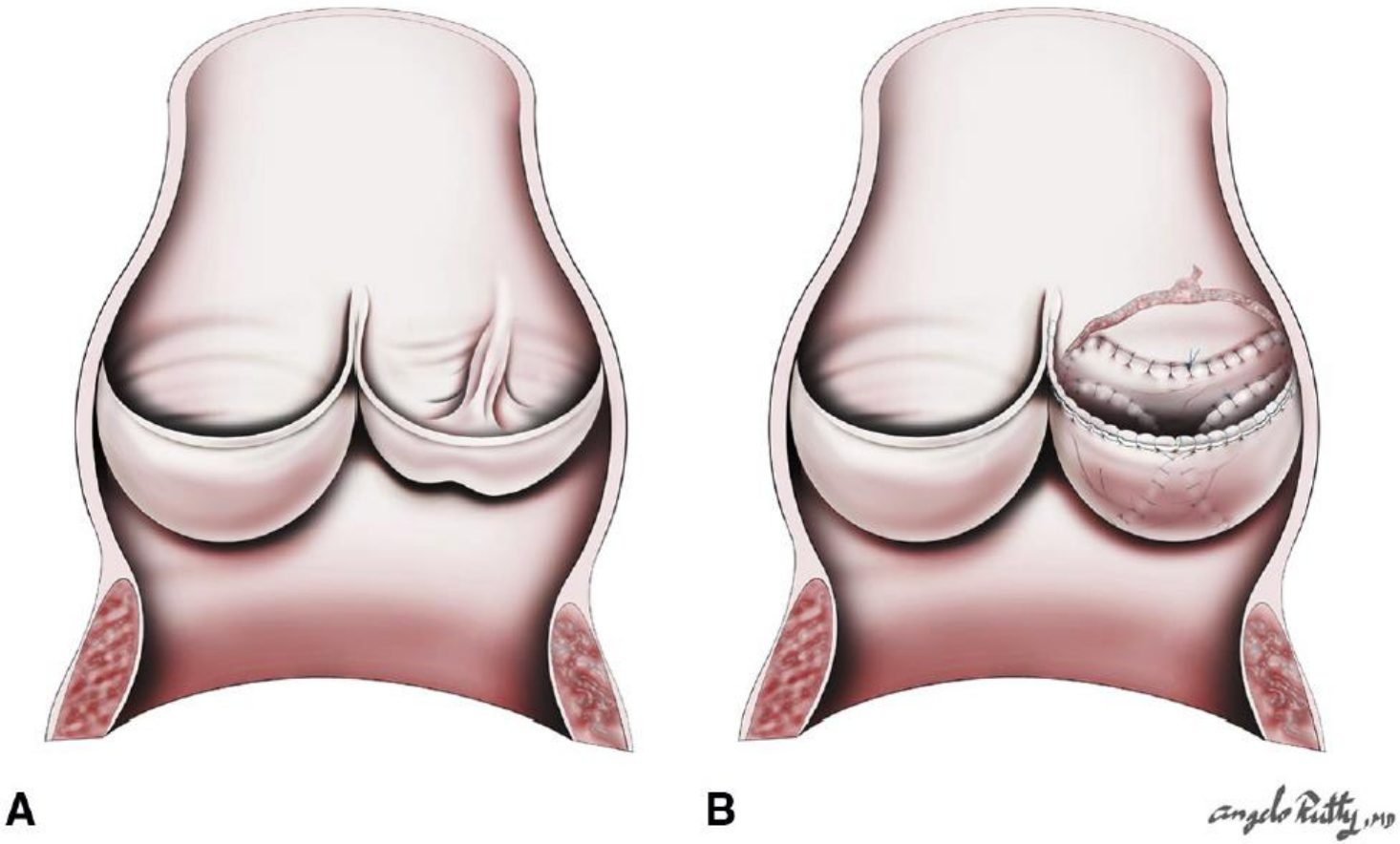

A, The appearance of the pathologic “raphe'd” (type 1) bicuspid aortic valve. B, The repaired valve with its complete conversion to a symmetric (type 0) bicuspid aortic valve.

Gleason TG. J Thorac Cardiovasc Surg. 2014;148:2862-8.e1-2.

Techniques

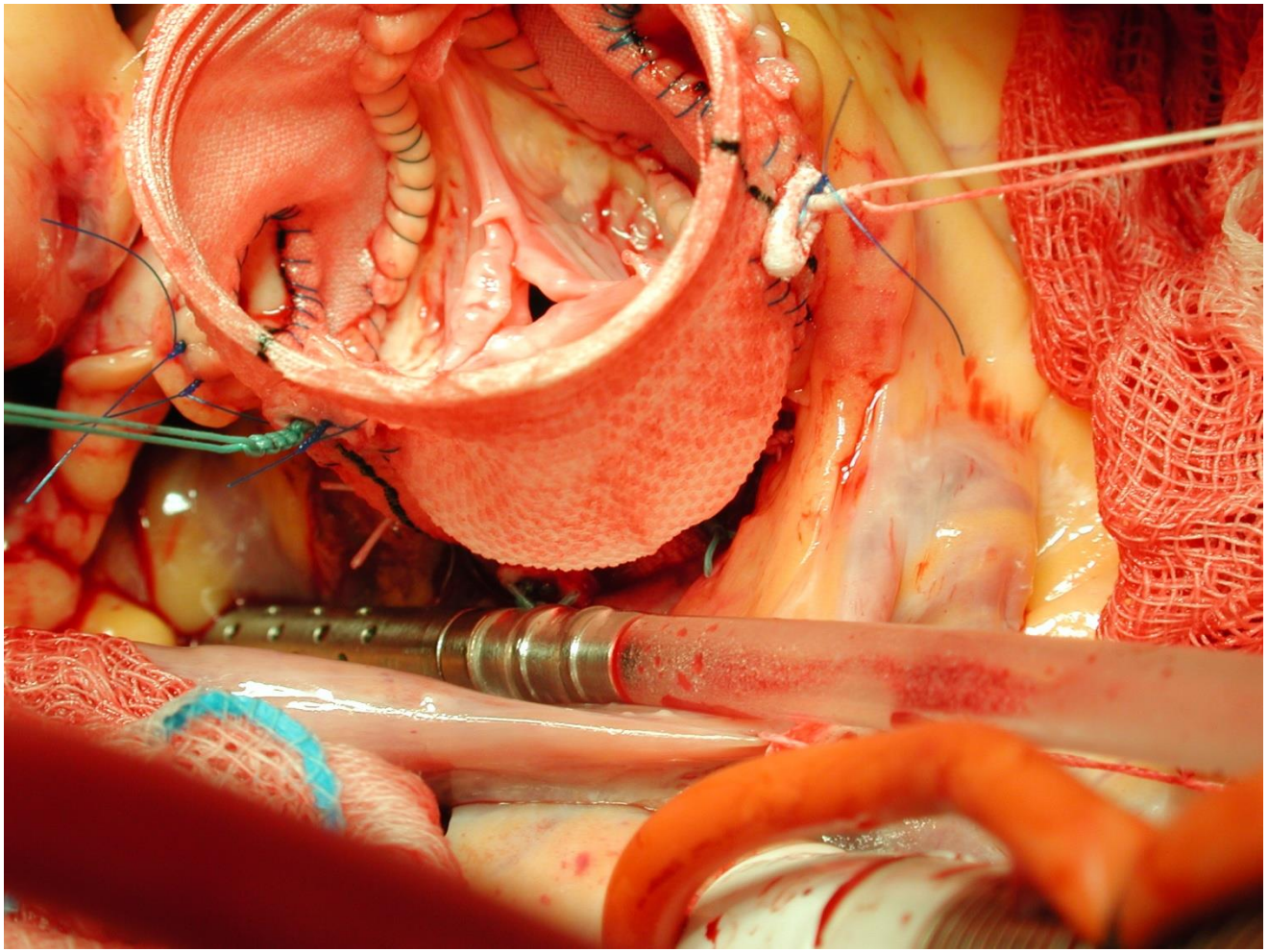

Sinus prosthesis in place

Techniques

Yacoub operation

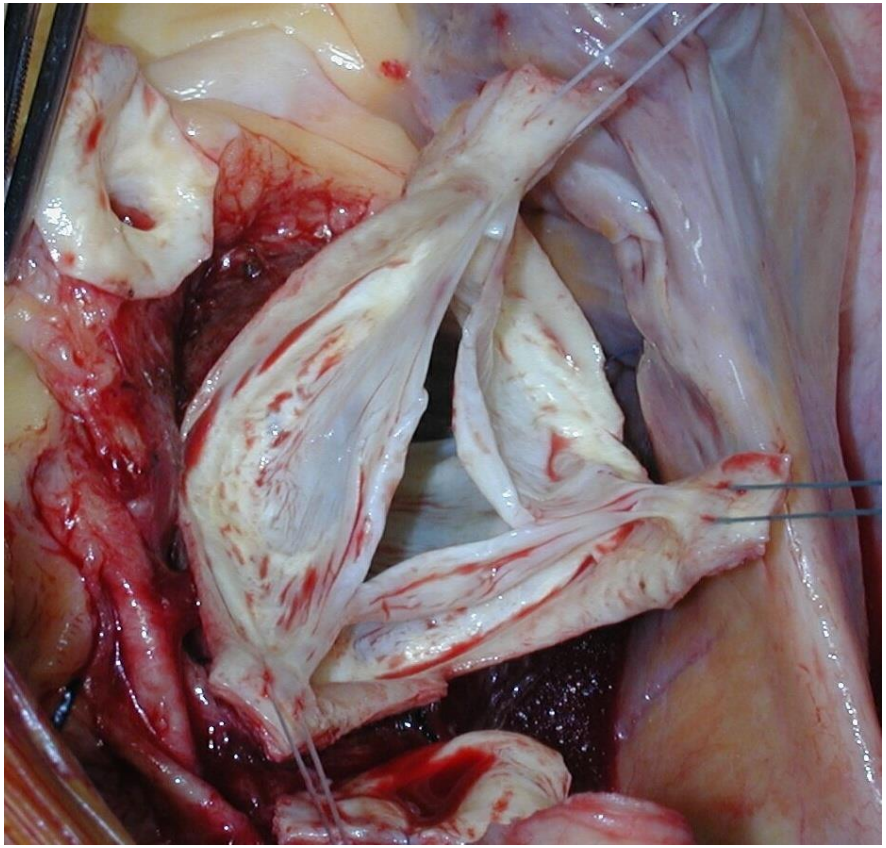

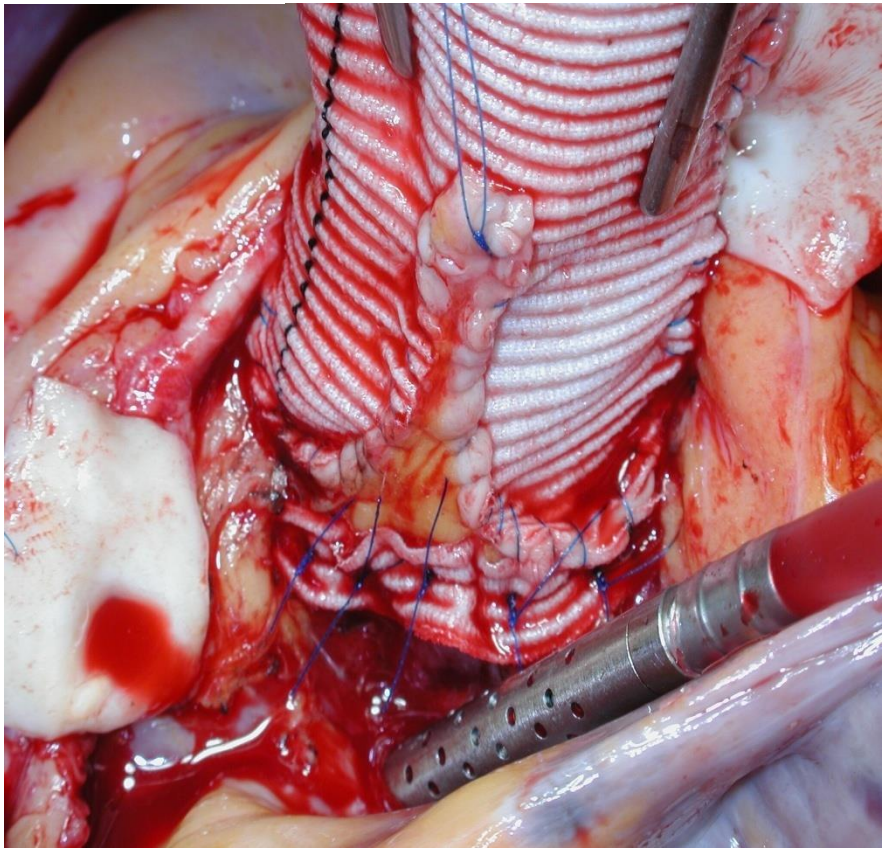

Left panel: Intraoperative situs after excision of sinuses in root aneurysm with insufficiency.
Right panel: Replacement of sinuses (S) with prosthetic material prior to implantation of coronary buttons (CB)

Failures

Aortic valve repair

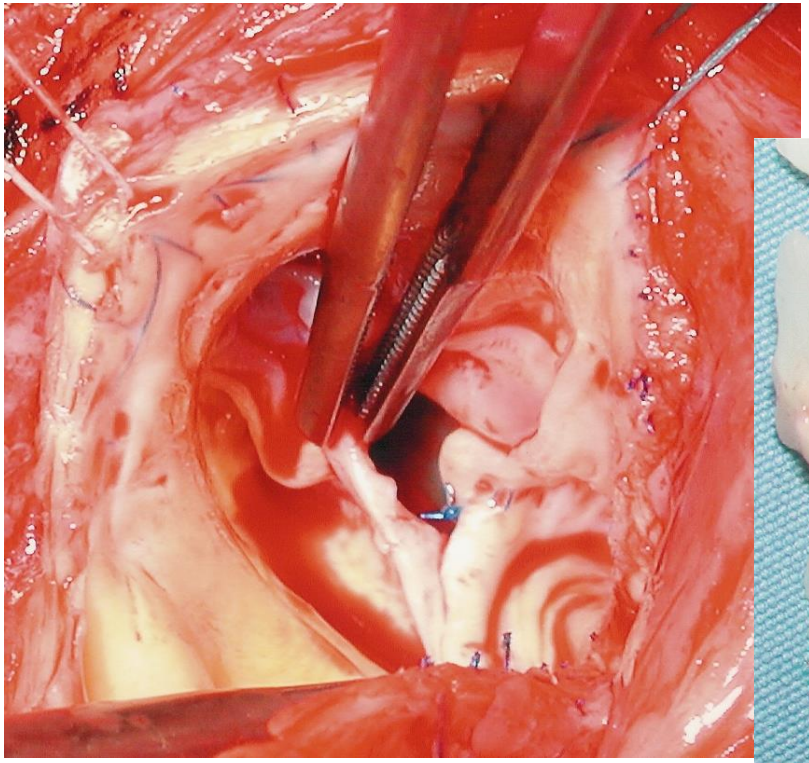

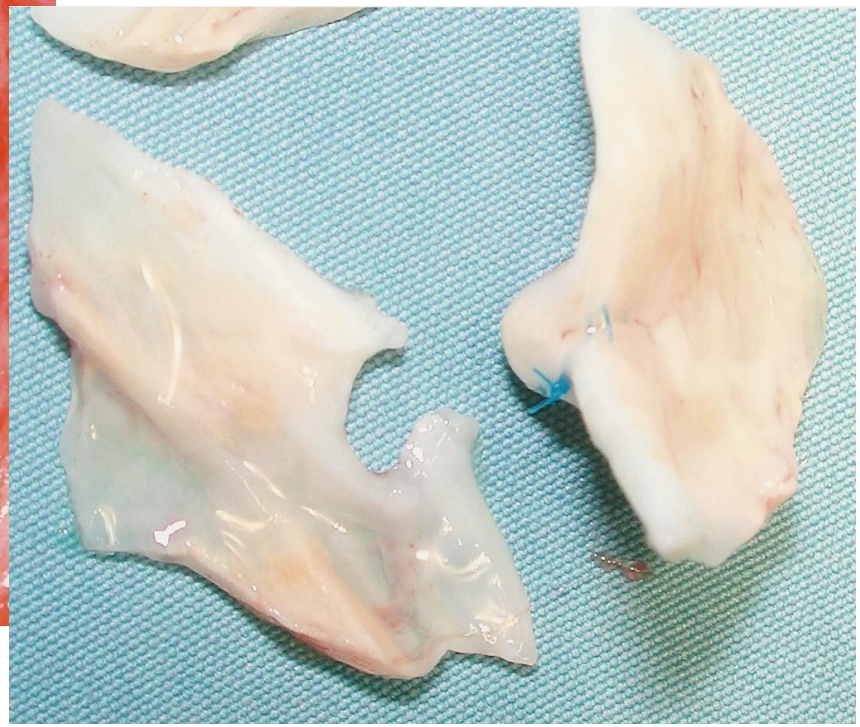

Failures

9 years later after David - bicuspid valve

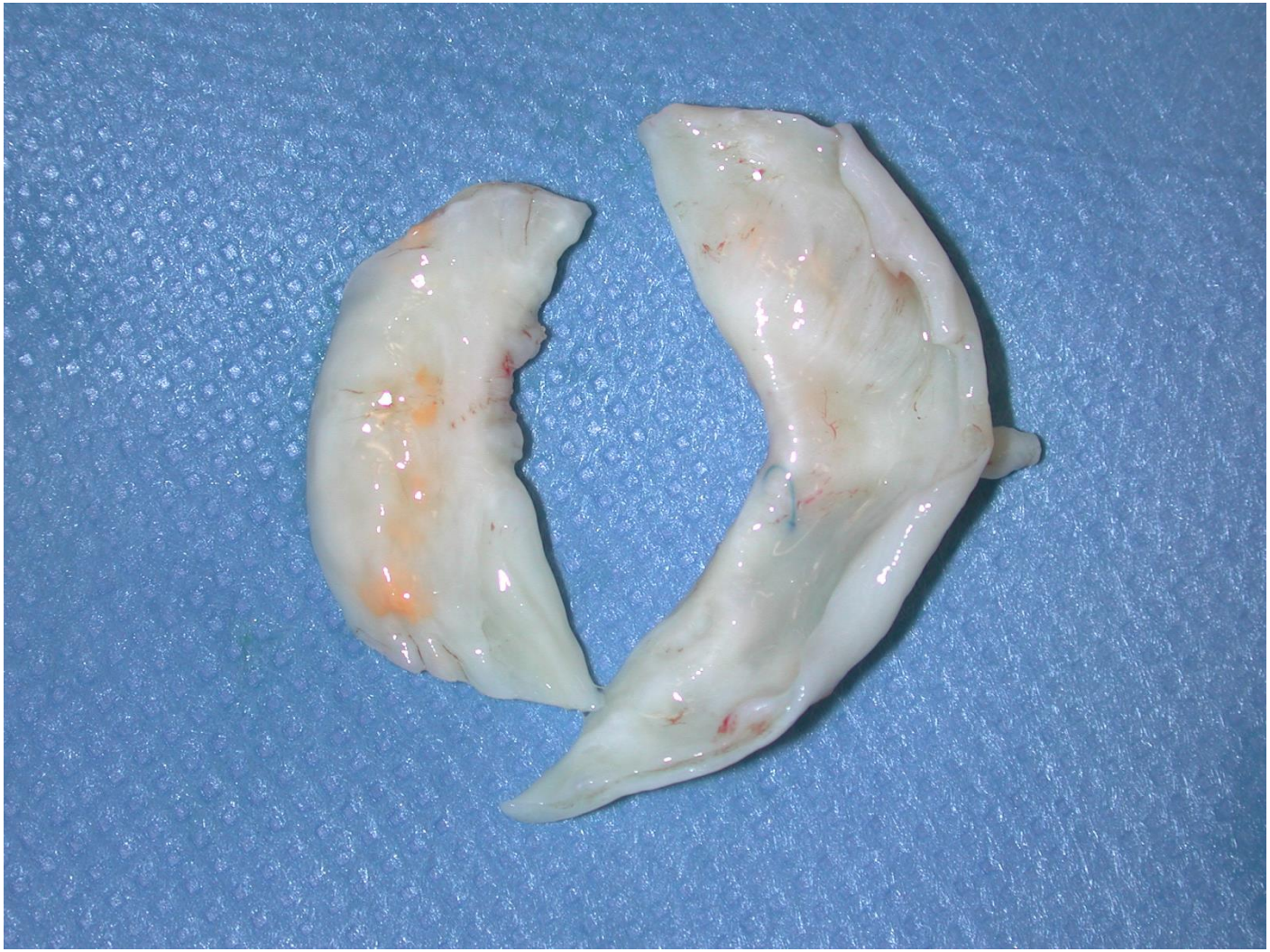

Results

Survival (Lübeck)

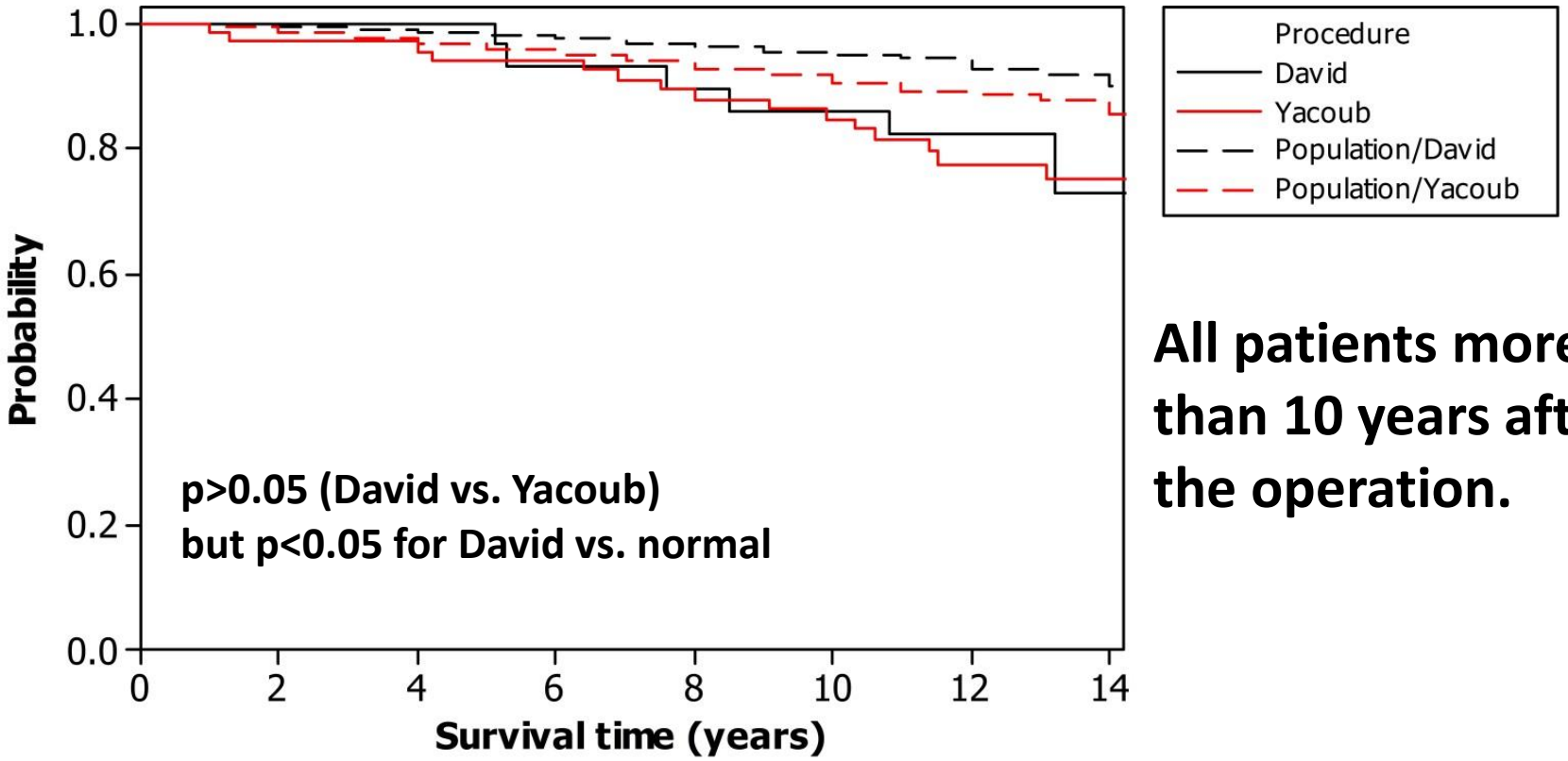

All patients more than 10 years after the operation.

Numbers at risk								
David	29	29	29	27	25	24	11	7
Yacoub	66	64	64	62	59	52	39	20

Results

Freedom from reoperation (Lübeck)

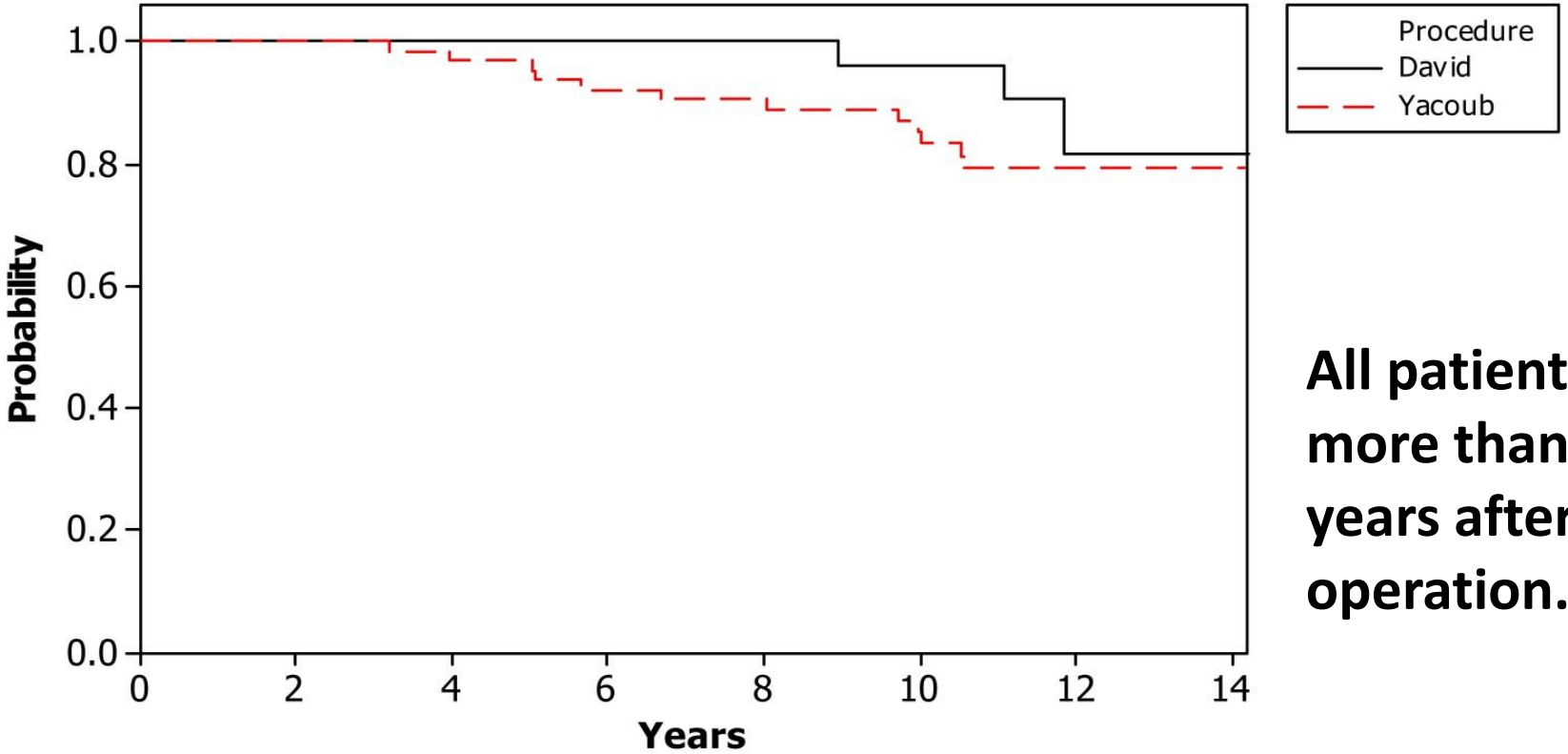

Numbers at risk								
David	29	29	29	27	25	23	9	6
Yacoub	66	64	62	57	53	46	33	19

All patients more than 10 years after the operation.

Results

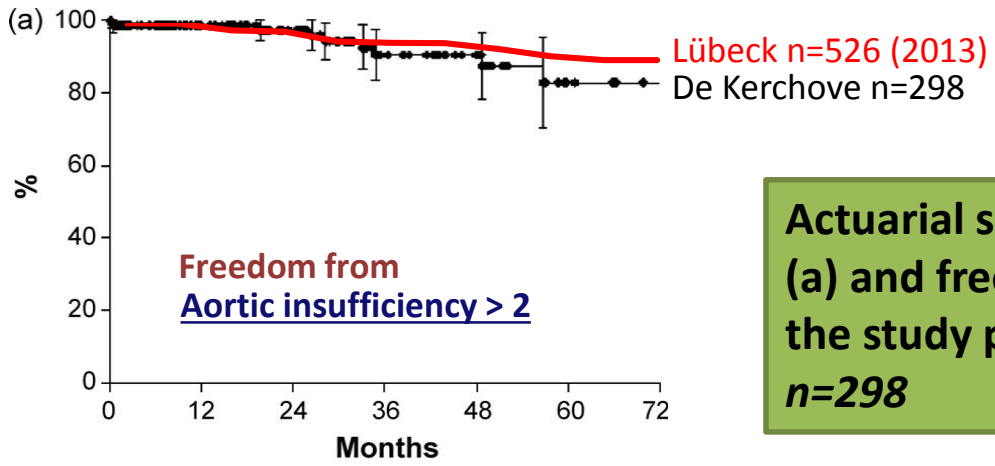

Actuarial survival freedom from AI > grade 2 (a) and freedom from AV reoperation (b) in the study population
n=298

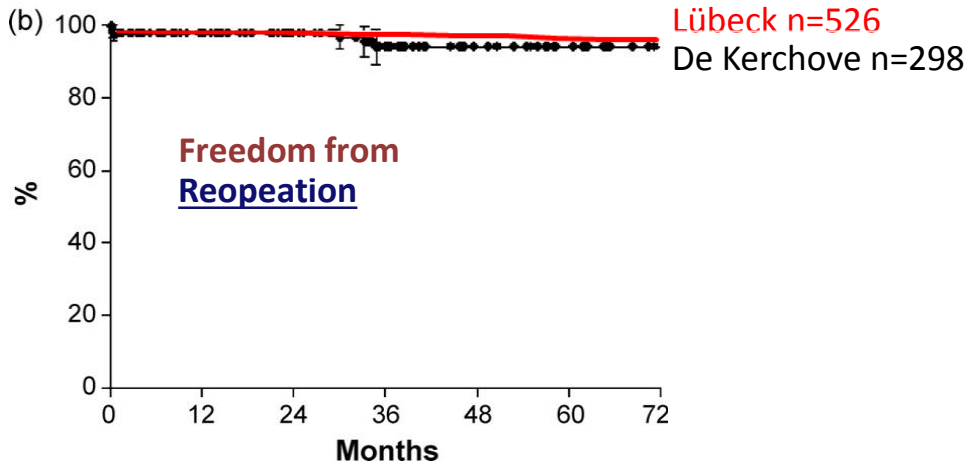

De Kerchove L et al. Eur J Cardiothorac Surg 2008;34:785-791

Total repair n= 488

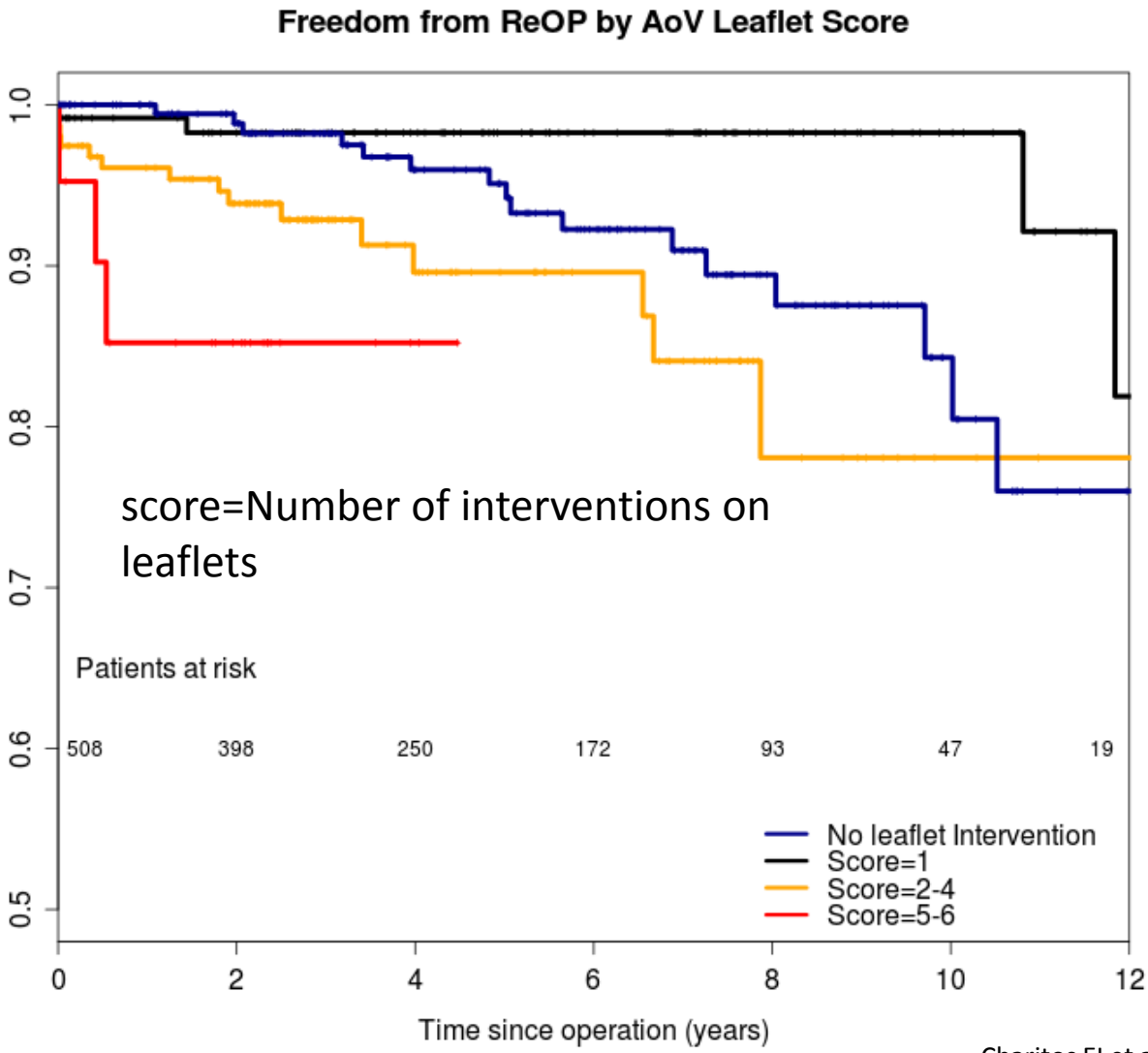

Lübeck

Charitos EI et al. J Heart Valve Dis. 2014;23:550-7.

Freedom from prosthetic aortic valve replacement

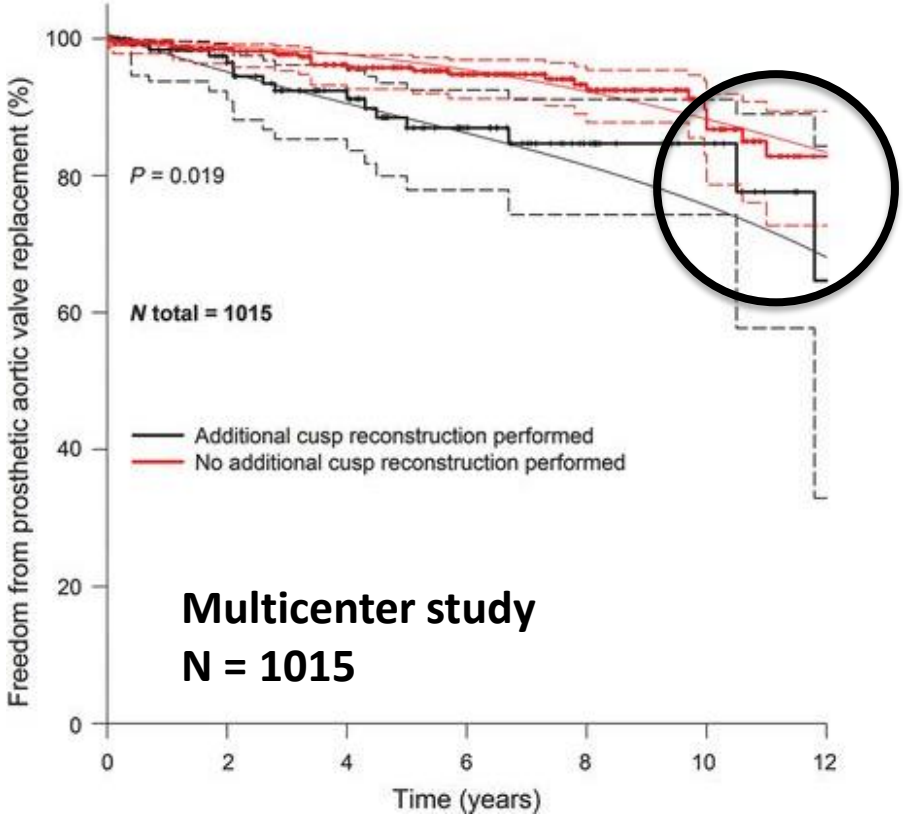

Kari FA et al. Interact Cardiovasc Thorac Surg. 2016;22:431-8.

Very Long-Term Outcomes of the Carpentier-Edwards Perimount Valve in Aortic Position

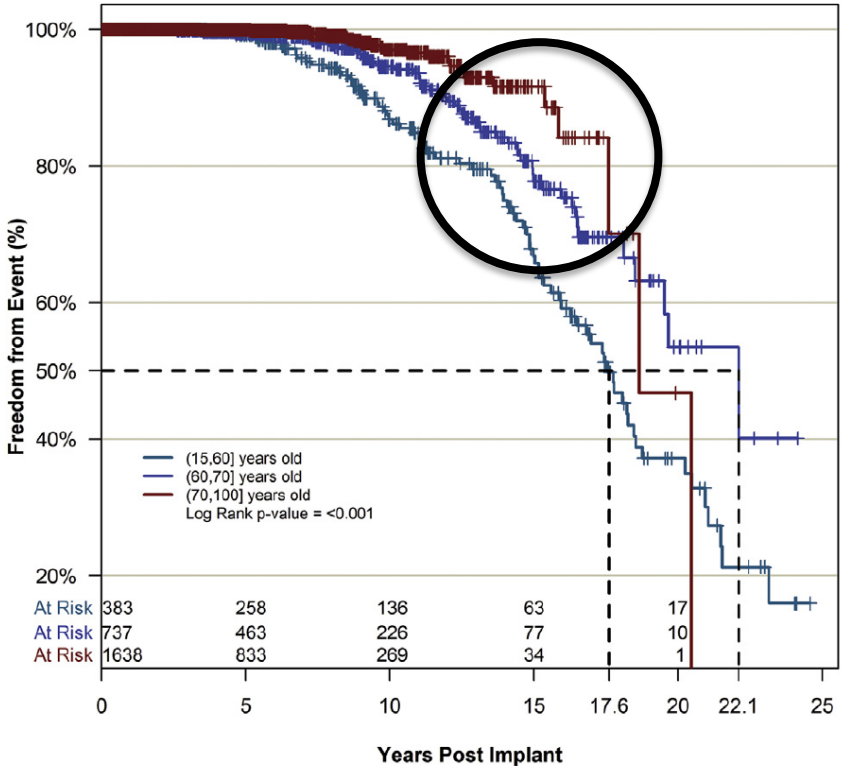

Bourguignon T et al. Ann Thorac Surg. 2015;99:831-7.

Combined AG HG Reoperations – Adult population
Stratification by technique

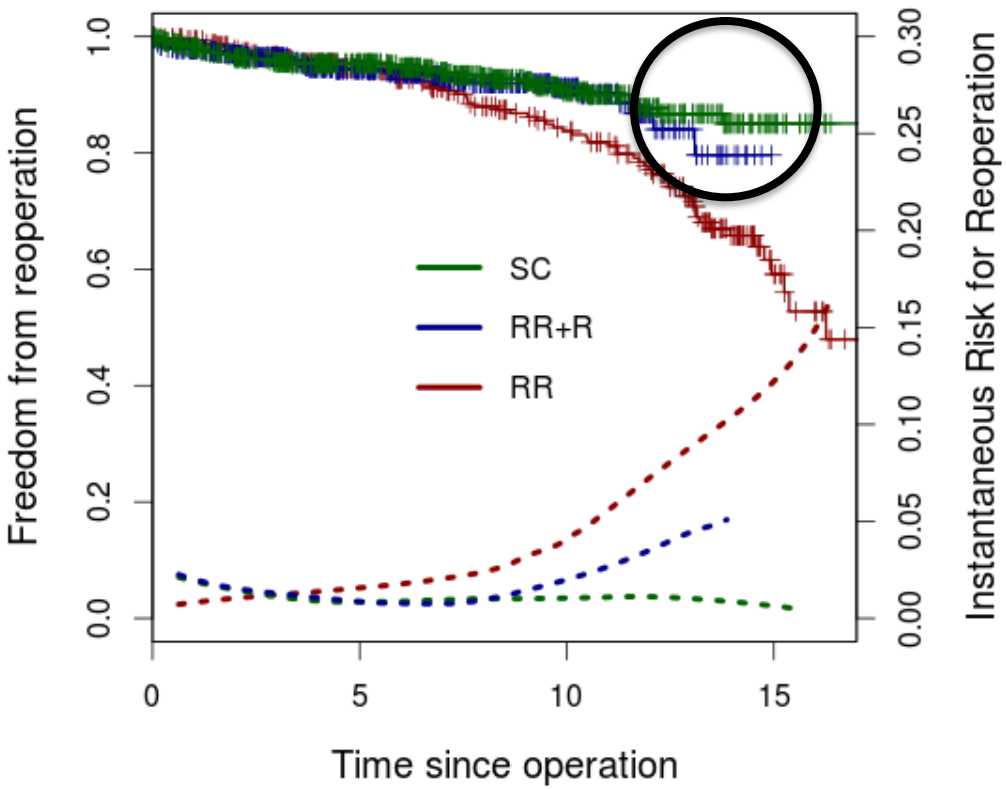

Time	10y	15y
Freedom from ReOP	0.90	0.85
n at risk	194	23
Freedom from ReOP	0.90	
n at risk	112	
Freedom from ReOP	0.81	0.58
n at risk	167	33

Risk factors for reoperation

Freedom from recurrent AI (≥3+) or reoperation in patients who underwent cusp repair by pericardial patch use

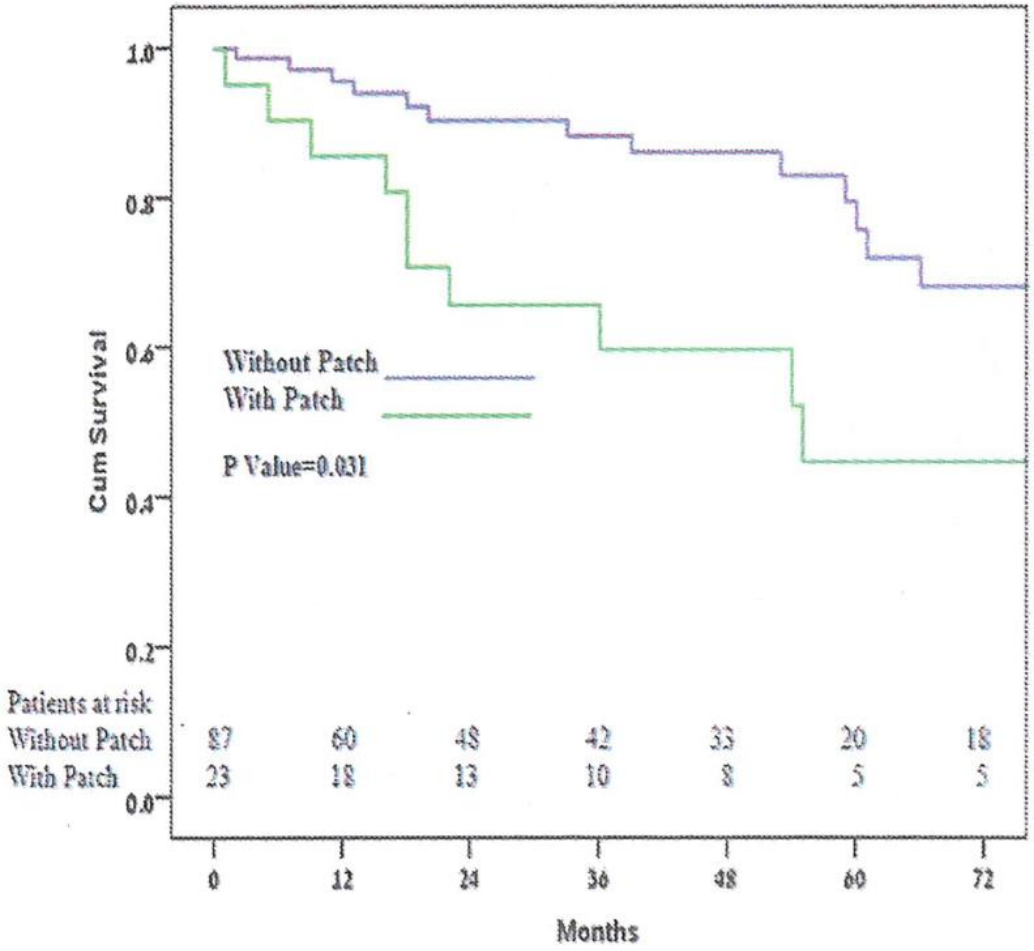

Pericardial patch

Ram E et al. EACTS Daily News, 2016:Issue 2, Sunday 2 October: page 44

Actuarial freedom from reoperation after aortic valve repair in patients with a BAV depending on postoperative achieved eH

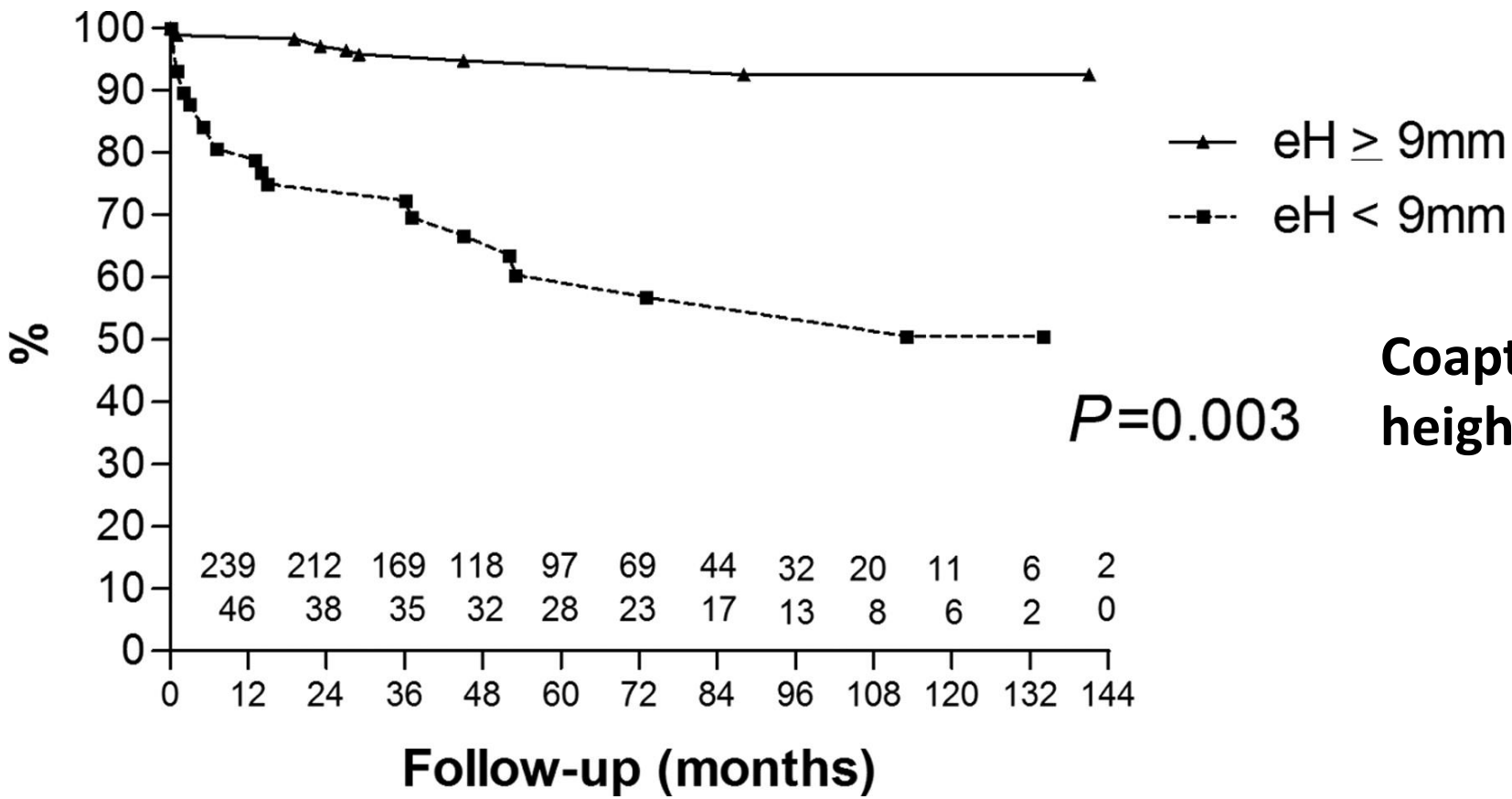

Coaptation height

Aicher D et al. Circulation. 2011;123:178-85.

VSSR vs. Simple BAV repair (SCA) with dilated annulus (>27 mm): SCA Fails in short term N=83

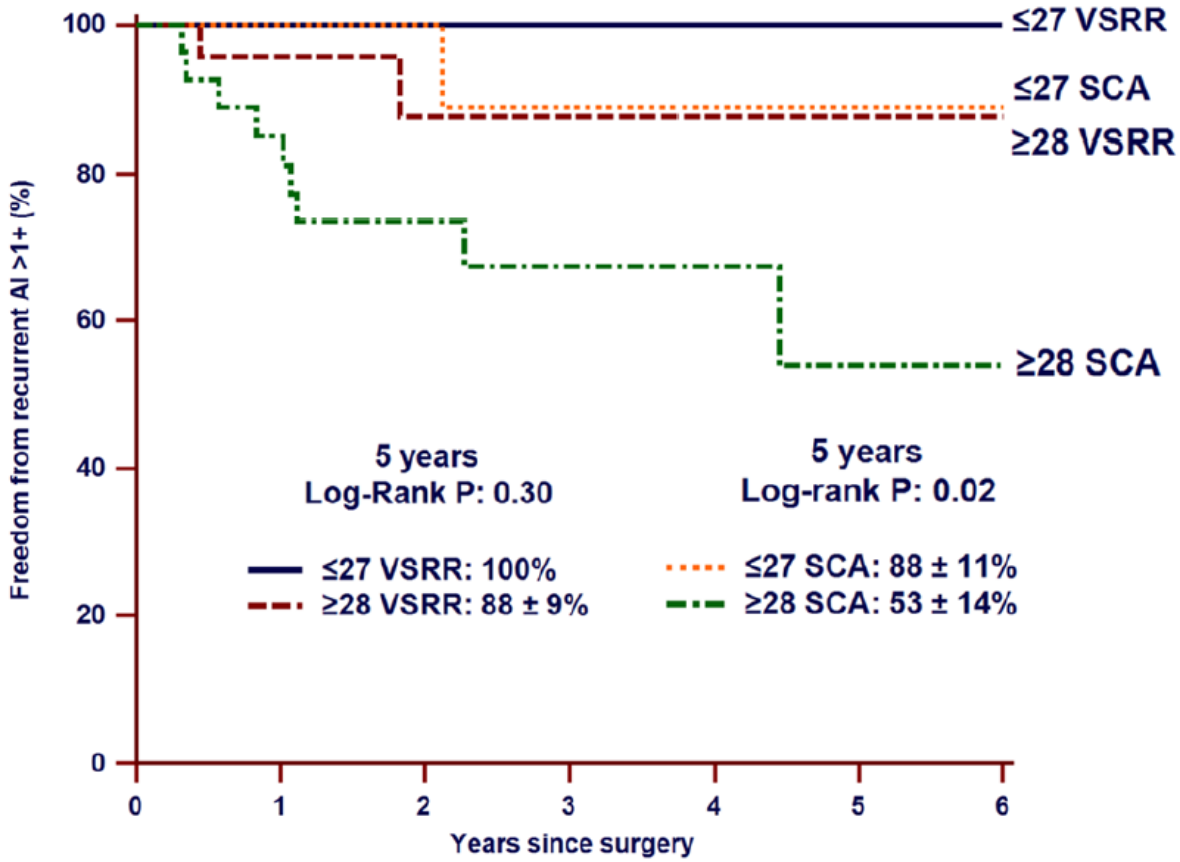

Number at risk

≤27 VSRR 12	10	9	7	5	5	5
≥28 VSRR 24	18	8	5	4	4	2
≤27 SCA 18	12	9	3	2	2	1
≥28 SCA 29	22	14	8	6	3	2

For larger diameters > 27 mm no subcommissural annuloplasty!

Bavaria JE. 2nd North American Aortic Valve Repair Symposium; Philadelphia: 2016

Advantages and limitations of repair compared to replacement

	Repair	Replacement		
		Ross	Bioprosthesis	Mechanical valve
Thromboembolism	+	+	(+)	-
Bleeding	+	+	+	-
Noise	+	+	+	-
Lifestyle restriction	+	+	+	(+)
Survival relative to normal (long-term)	(+)?	(+)?	(-)??	(+)?
Durability	+??	+?	+???	+
Function	+	+	(+)?	(+)
Complex operation	-	-	+	+

Conclusion I

Special issues of
Aortic valve repair:

- Technique is still in the developing process
- Leaflet tissue of good quality
- Consider risk factors for reoperation
- Gain adequate coaptation area (~6mm)
- Stabilize annulus and STJ if dilated
- Experienced centers
- Don’t overstress the method (It is different from MV repair!)
- Surgeons variability of surgical techniques, no standardization, generalizability?
- Longer than 10 years follow-up are rare and most important

Conclusion II

Aortic valve replacement

- Ross in experienced centers, excellent results
- Bioprosthesis
  - As large as possible (every millimeter counts, every effort is a must!)
  - Must have the potential for alter ViV
- Mechanical Valve
  - Optimal anticoagulation should be warranted (self-management)

Patients must be informed, repair should not be overstressed (negative for patient and method, alternatives also have their advantages), longer-term follow-up, standardization, experienced centers for repair and Ross, need for longer term follow-up and elastic prosthetic material

After David-OP