Spinal cord protection — segmental artery embolization

Christian D. Etz, MD, PhD
Heisenberg Professor for Aortic Surgery

UNIVERSITÄT LEIPZIG
HERZZENTRUM

MOUNT SINAI SCHOOL OF MEDICINE

UNIVERSITÄT LEIPZIG HERZZENTRUM

Ischemic Spinal Cord Injury

No definite prevention strategy

— **essential** for **safe open and endovascular repair** [1,2]

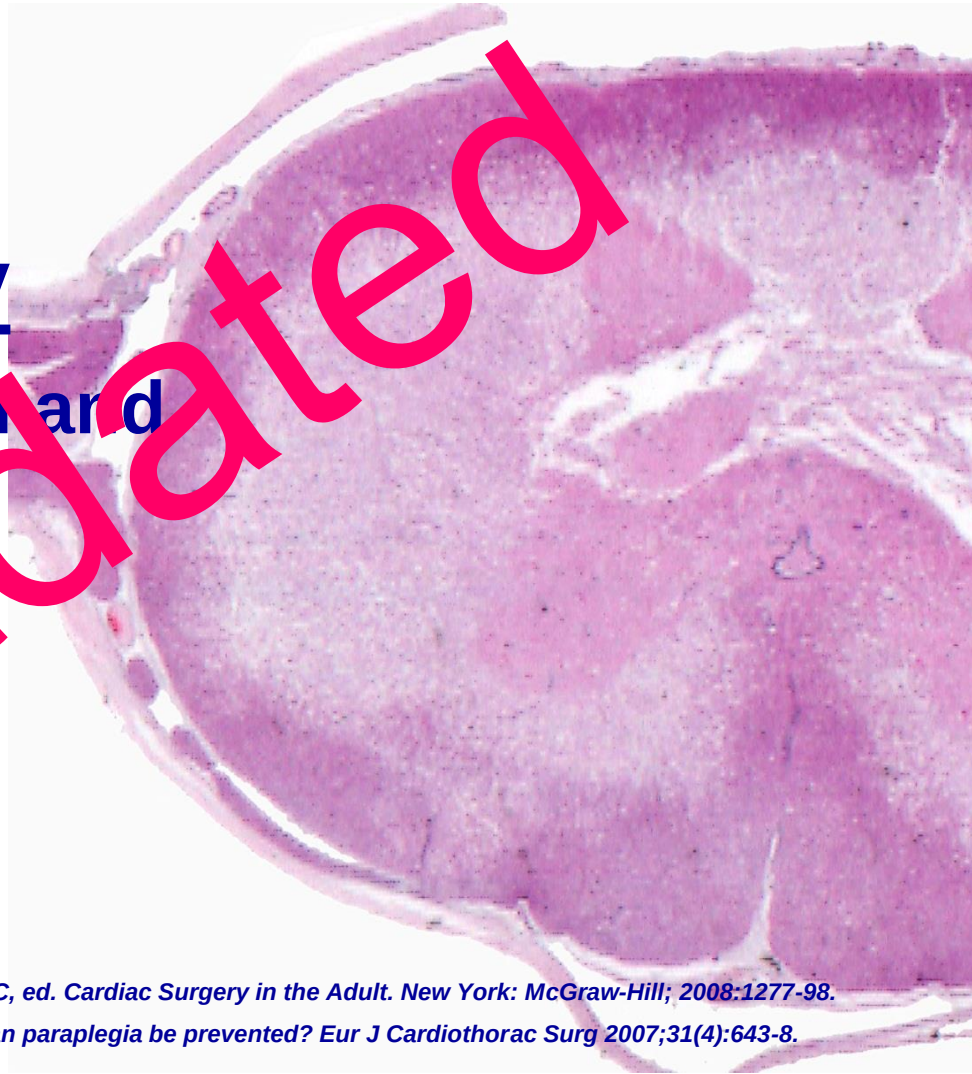

outdated

1 Coselli, LeMaire. Descending and Thoracoabdominal Aortic Aneurysms. In: Lh C, ed. Cardiac Surgery in the Adult. New York: McGraw-Hill; 2008:1277-98.

2 Etz CD et al. Spinal cord perfusion after extensive segmental artery sacrifice: can paraplegia be prevented? Eur J Cardiothorac Surg 2007;31(4):643-8.

‘If the theory does not fit the facts — *too bad for the facts*’

Kurt Biedenkopf (former Ministerpräsident of Saxony) quoting a frustrated UC Berkley student

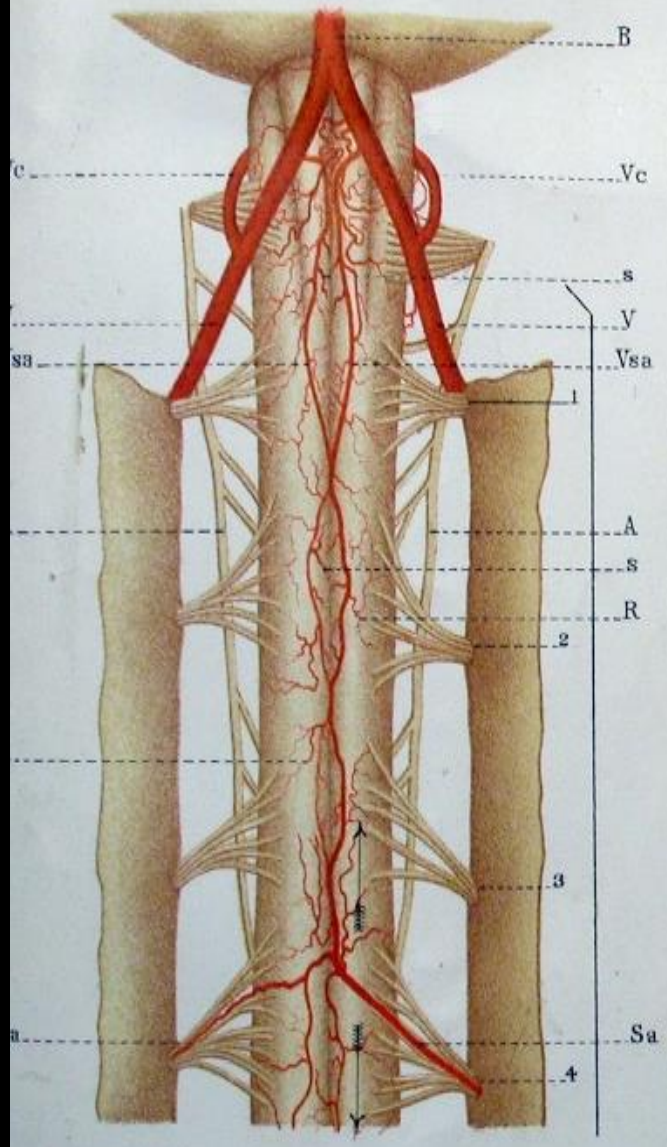
B
Vc
s
V
Vsa
1
A
s
R
2
3
Sa
4

I.

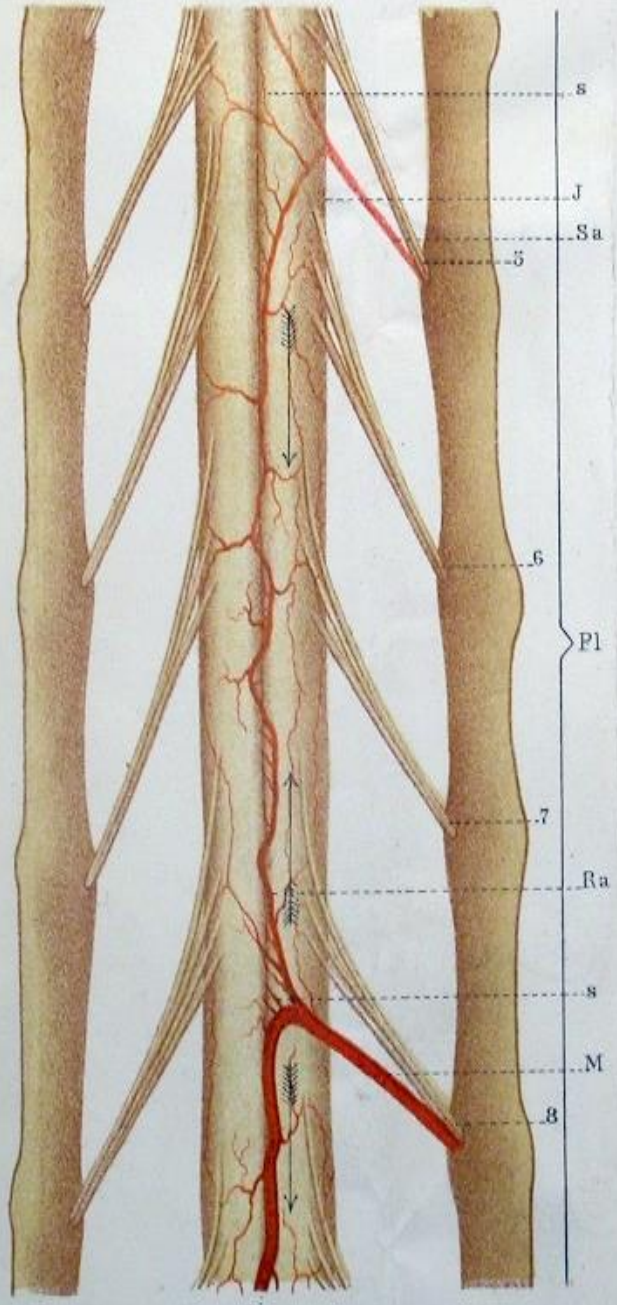
s
J
Sa
5
6
Pl
7
Ra
s
M
8
Aa

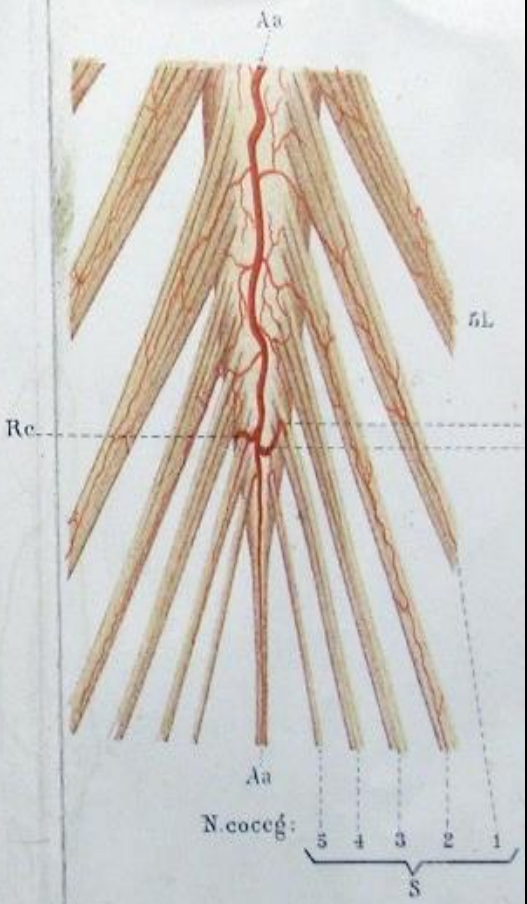
Aa
5L
Rc
Aa
N.coccg:
5 4 3 2 1
S

III.

Die Blutgefässe des menschlichen Rückenmarkes.

I. Theil.

Die Gefässe der Rückenmarkssubstanz.

Von Prof. Dr. **Albert Adamkiewicz.**

(Mit 6 Tafeln.)

(Institut für experimentelle Pathologie der k. k. Universität Krakau.)

(Vorgelegt in der Sitzung am 3. November 1881.)

‘If the theory does not fit the facts, *change the facts*’

Albert Einstein

MOUNT SINAI SCHOOL OF MEDICINE

Segmental Artery Occlusion

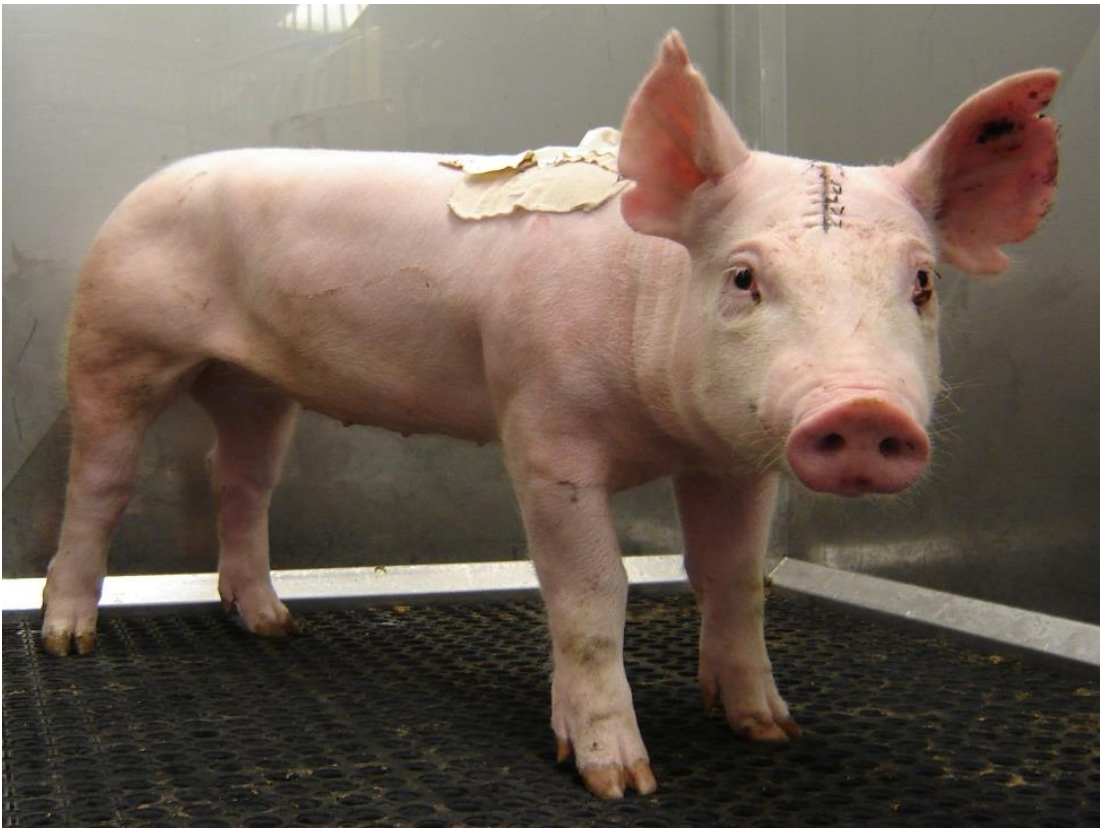

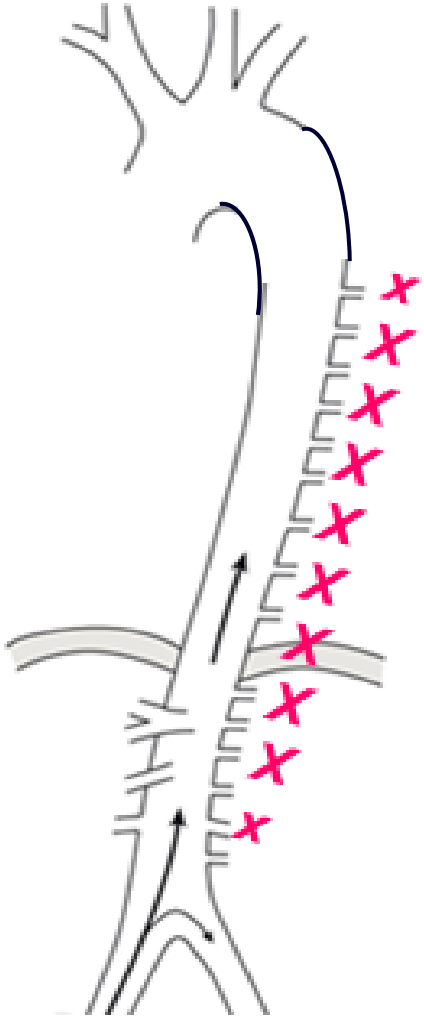

Yorkshire pigs

(*N* = 20)

Direct blood pressure measurement

MOUNT SINAI
SCHOOL OF
MEDICINE

MAP

SCPP

POSTOPERATIVE SCPP

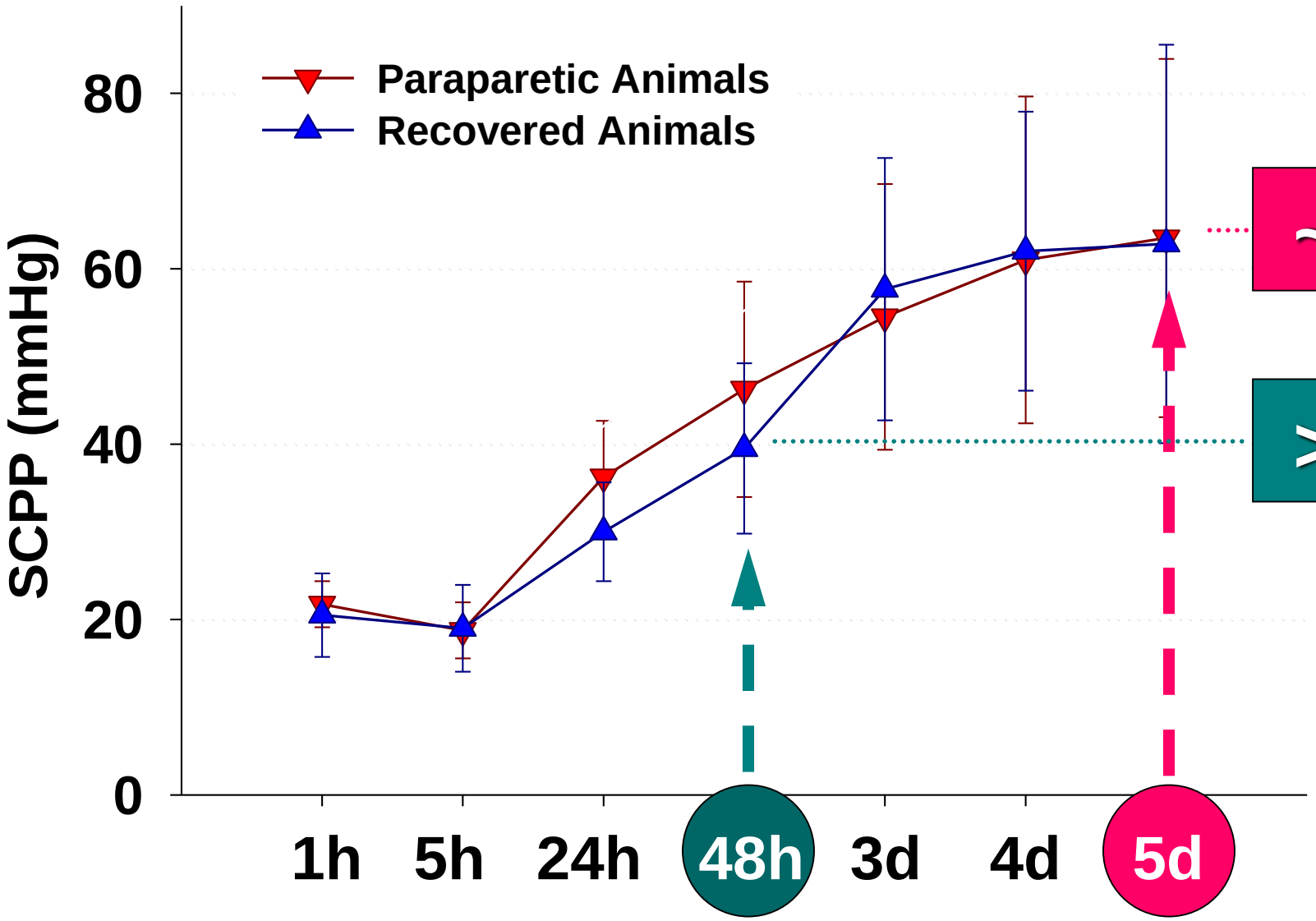

~ 95%

> 60%

after ALL clamped

MOUNT SINAI SCHOOL OF MEDICINE

Collateral Network recovers blood flow within 72h !

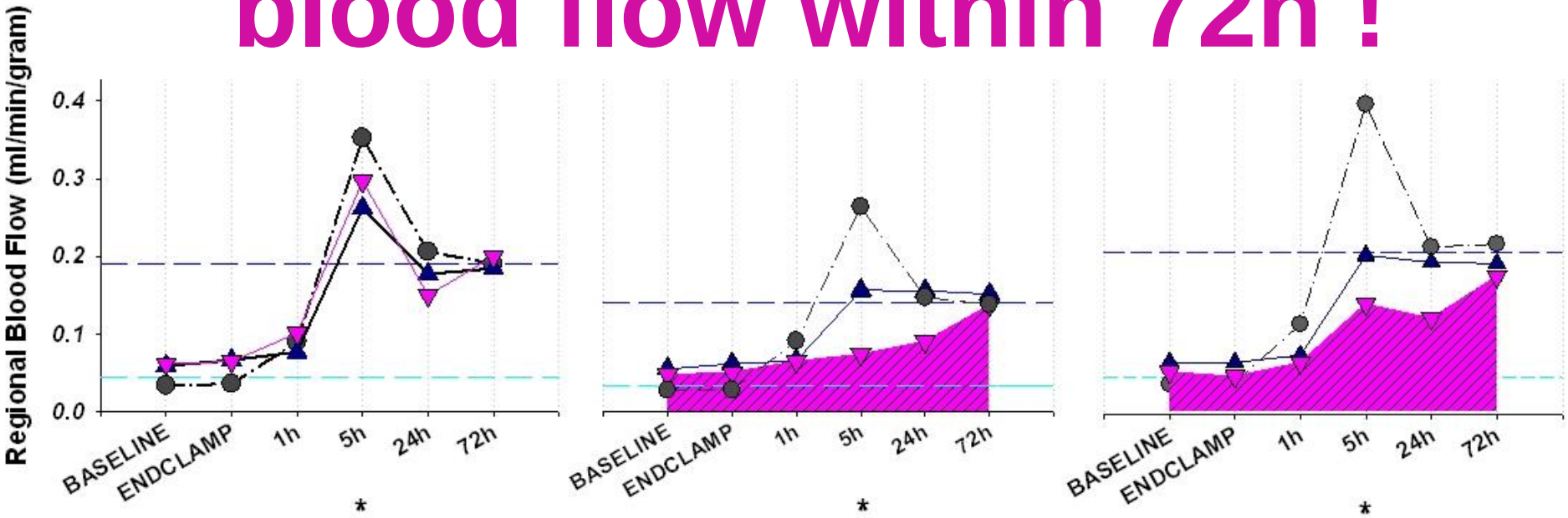

* p= .46 (not significant)

* p= .0002 (significant)

* p= .0007 (significant)

HUMAN vs PIG

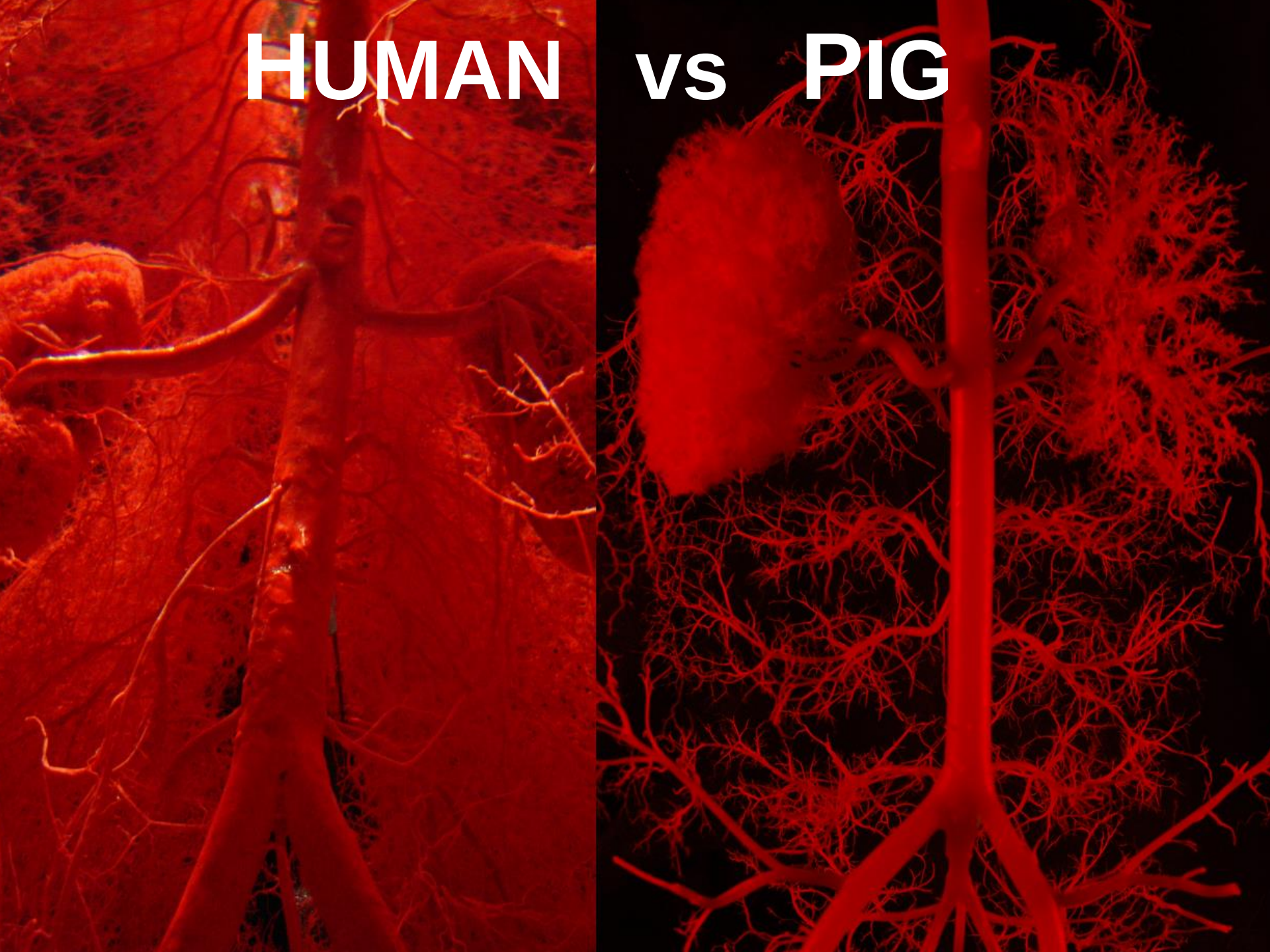

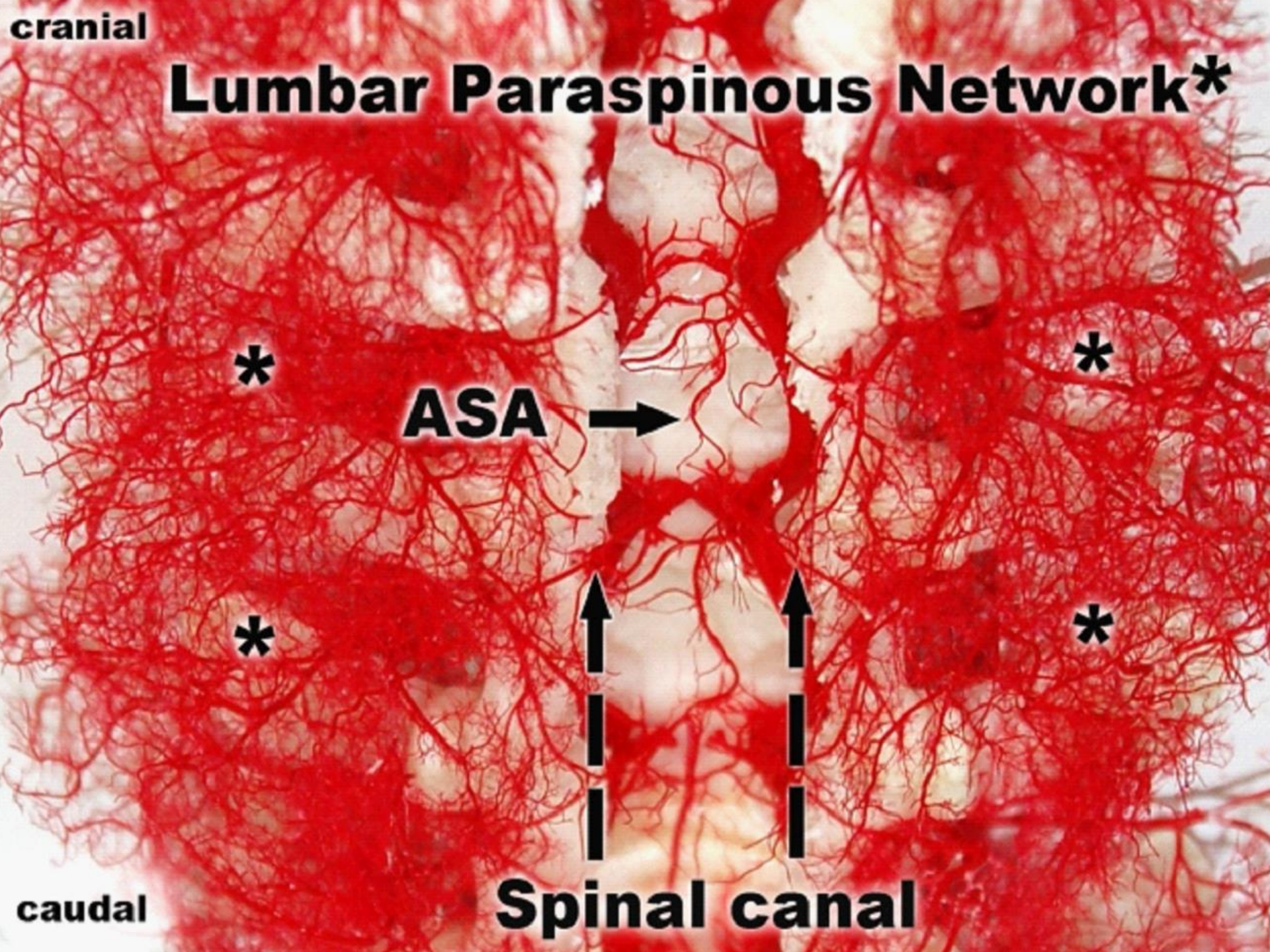
cranial
Lumbar Paraspinous Network*
*
*
ASA
*
*
caudal
Spinal canal


Mag:100
100 µm

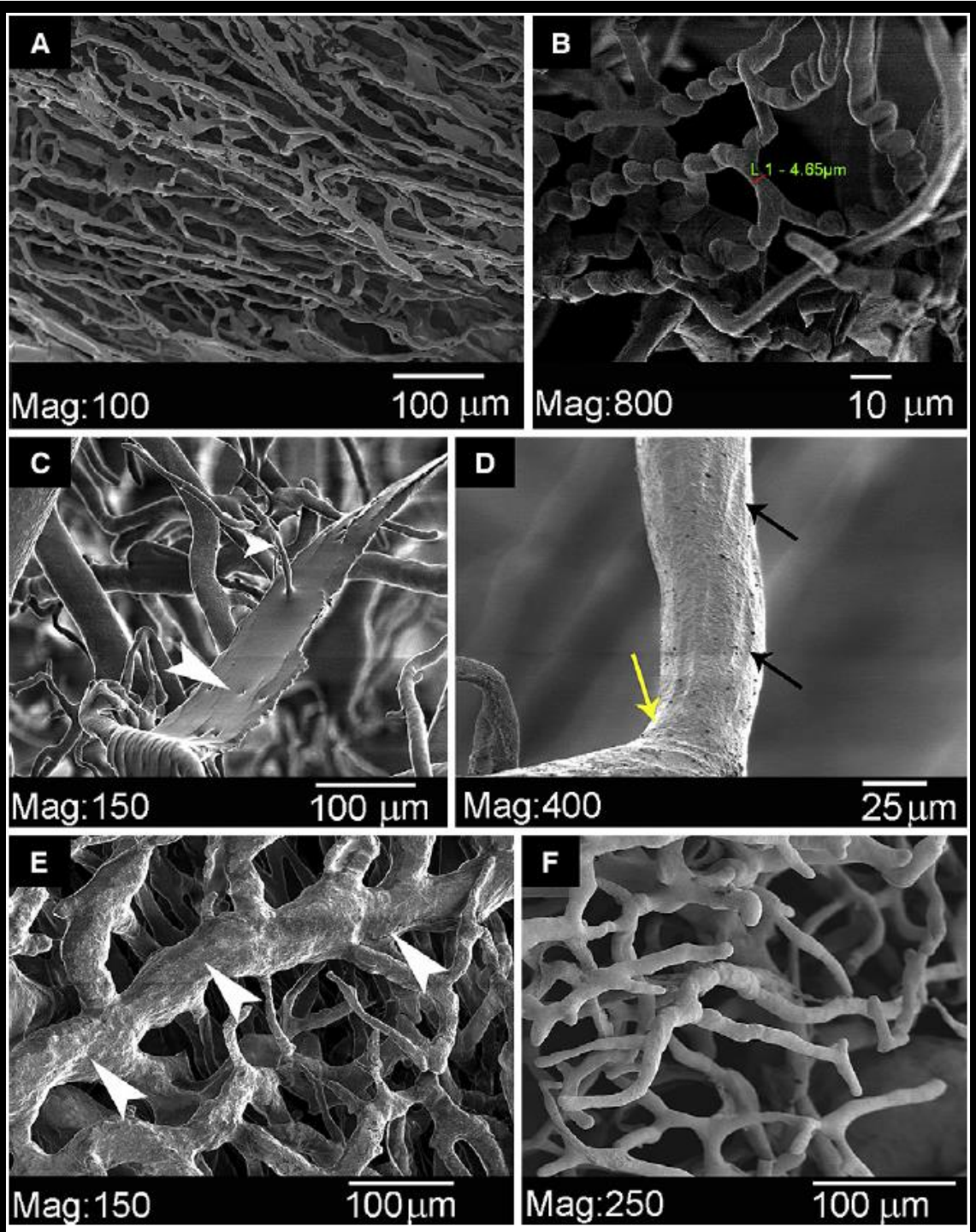
A
Mag:100
100 µm
B
L 1 - 4.65µm
Mag:800
10 µm
C
Mag:150
100 µm
D
Mag:400
25 µm
E
Mag:150
100µm
F
Mag:250
100 µm

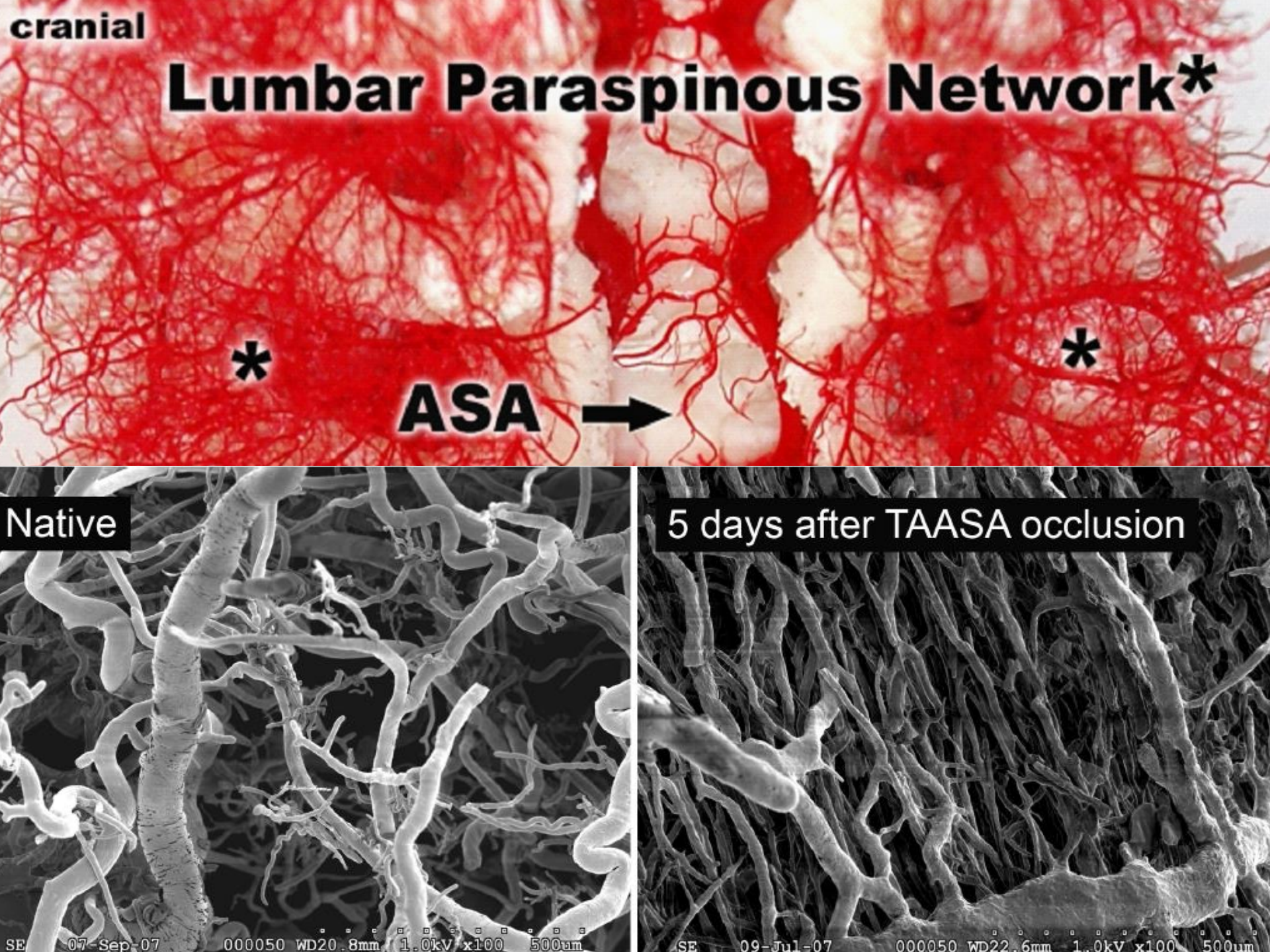
cranial
Lumbar Paraspinous Network*
*
*
ASA
Native
5 days after TAASA occlusion
SE 07-Sep-07 000050 WD20.8mm 1.0kV x100 500um
SE 09-Jul-07 000050 WD22.6mm 1.0kV x100 500um

UNDERSTANDING
THE IMPLICATIONS

Orientation of the *Paraspinous* Collateral Network Arterioles *prior to* and *after* complete SA sacrifice

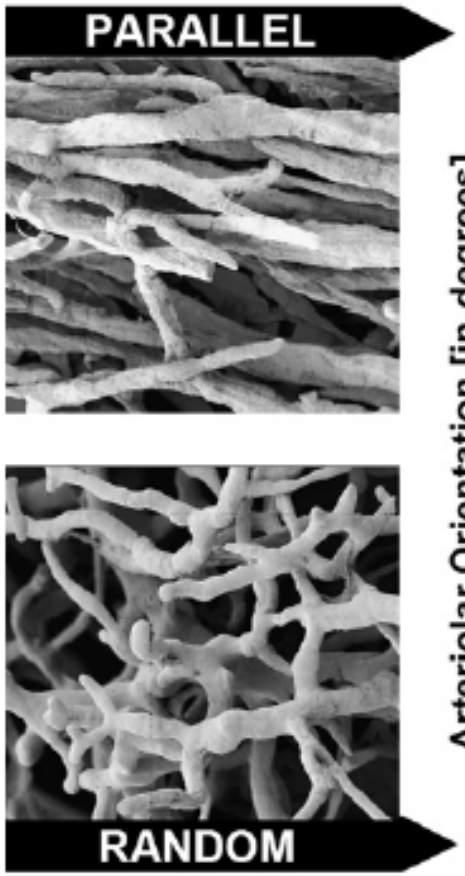

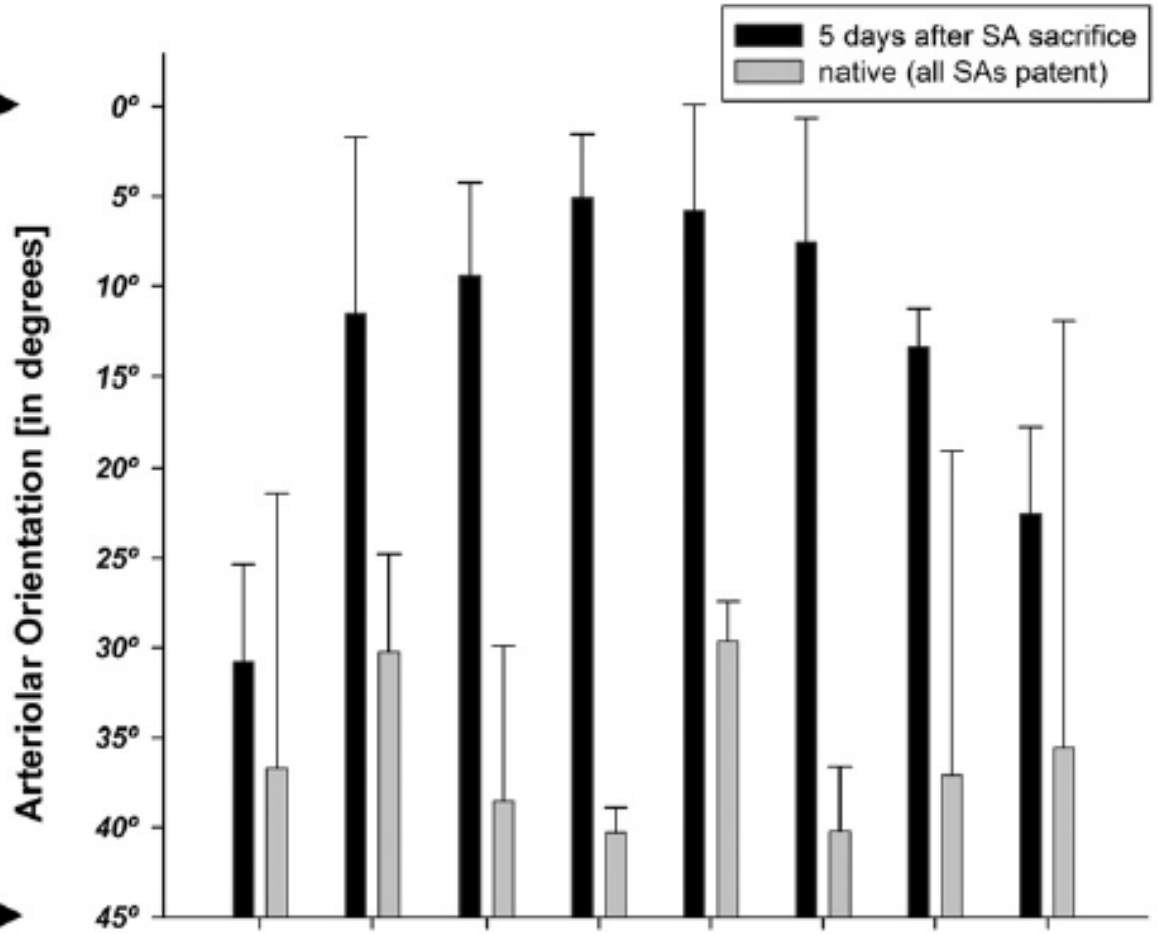

Etz et al., J Thorac Cardiovasc Surg. ***2011*** Apr;141
Etz et al., J Thorac Cardiovasc Surg. ***2015*** Apr;149

MOUNT SINAI SCHOOL OF MEDICINE

UNIVERSITÄT LEIPZIG HERZZENTRUM

Enlargement of lower thoracic and lumbar collaterals

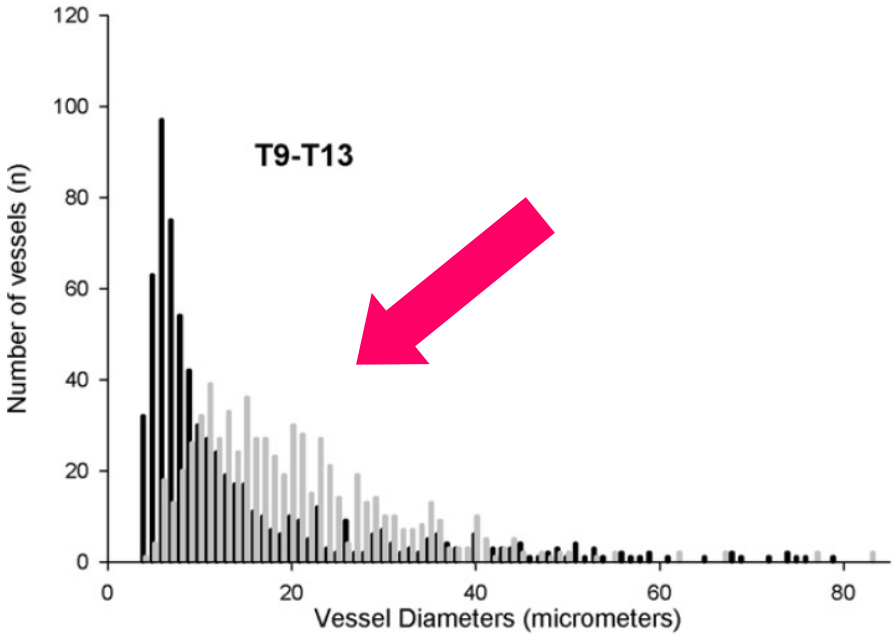

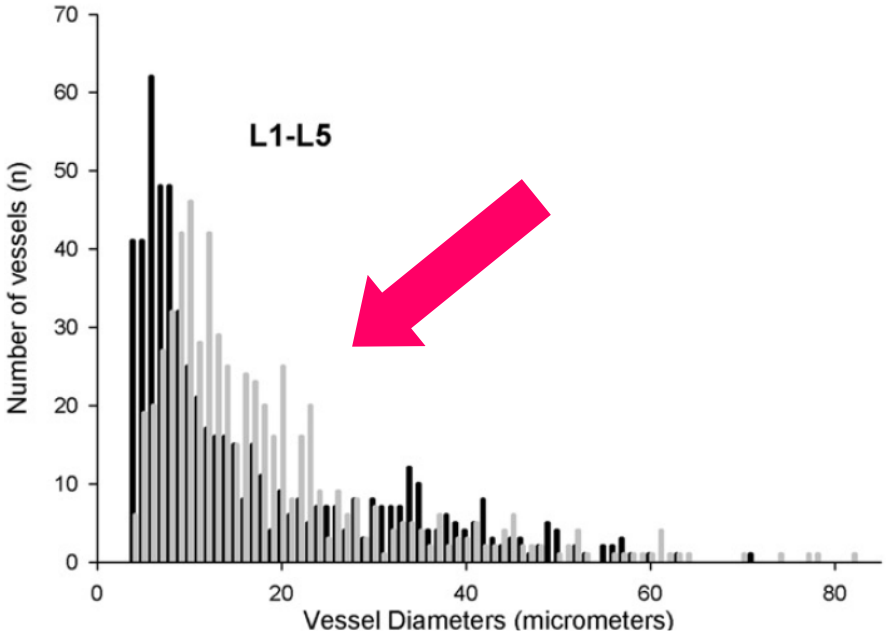

significant changes !

DEVELOPING *A NEW STRATEGY*— **THE STAGED REPAIR**

Experimental solution: *the staged repair*

UNIVERSITÄT LEIPZIG
HERZZENTRUM

ADULT CARDIAC

Experimental Two-Stage Simulated Repair of Extensive Thoracoabdominal Aneurysms Reduces Paraplegia Risk

Stefano Zoli, MD, Christian D. Etz, MD, PhD, Fabian Roder, MS, Robert M. Brenner, MS, Carol A. Bodian, DrPH, George Kleinman, MD, Gabriele Di Luozzo, MD, and Randall B. Griepp, MD

Departments of Cardiothoracic Surgery, Anesthesiology, and Neuropathology, Mount Sinai School of Medicine, New York, New York

Background. In a pig model, we compared spinal cord injury after extensive segmental artery (SA) sacrifice in a single stage with recovery after a two-stage procedure: lumbar artery followed by thoracic SA sacrifice.

Methods. Twenty juvenile Yorkshire pigs were randomly assigned to undergo extensive SA sacrifice at 32°C in a single operation (group 1, n = 10), or thoracic SA ligation 7 days after lumbar artery sacrifice (group 2, n = 10). Spinal cord perfusion pressure (SCPP) was monitored using a catheter placed in the distal stump of L1. Hind limb function was evaluated intraoperatively using motor-evoked potentials and for 5 days postoperatively using a modified Tarlov score.

Results. Motor-evoked potentials were intact in all pigs until 1 hour after surgery. All pigs in group 2 fully recovered hind limb function, whereas 40% in group 1 experienced paraplegia (median Tarlov scores 9 versus 7; $p = 0.004$). Group 1 SCPP fell to 28 ± 6 mm Hg after SA sacrifice, compared with 44 ± 8 mm Hg in group 2 ($p < 0.0001$). After sacrifice of all residual SAs, SCPP in group 2 remained consistently greater than 85% of baseline, significantly higher than group 1 SCPP from end clamping until 72 hours ($p = 0.0002$). Histopathologic analysis showed more severe ischemic damage to the lower thoracic ($p < 0.001$) and lumbar spinal cord ($p = 0.01$) in group 1.

Conclusions. In contrast with the single-stage approach, a two-stage procedure, starting with ligation of six or fewer lumbar SAs, leads to only a mild drop in SCPP and stimulates vascular remodeling, minimizing the impact of subsequent SA sacrifice on spinal cord function. The greater safety of extensive SA sacrifice when undertaken in two stages has important implications for endovascular and hybrid aneurysm repair.

(Ann Thorac Surg 2010;90:722–30)

During the past few decades, considerable effort has been expended in searching for strategies to prevent spinal cord ischemic damage after surgical and endovascular repair of extensive thoracoabdominal (TAAA) aneurysms. A core body temperature of 32°C has been found [1] in experimental settings to be effective in increasing spinal cord ischemic tolerance by reducing metabolic requirements, and almost all aortic surgeons now perform TAAA resection under at least moderate hypothermia. A catheter for cerebrospinal fluid drainage is usually placed during aortic surgery to enhance spinal cord perfusion [2, 3] and, with increasing frequency, even when extensive aortic coverage is carried out with stent grafts [4, 5]. Several perfusion strategies have been reported to be effective in reducing the risk of intraoperative ischemia and hence paraplegia [6], including use of profound hypothermia [7]. However, the belief that reimplantation of intercostal arteries may be the key factor in preventing spinal cord infarction continues to be widespread [8, 9].

We have devoted our efforts to achieving a better understanding of the collateral circulation to optimize its response not only after surgical repair, but also in conjunction with endovascular strategies, in which revascularization of segmental arteries (SAs) is essentially precluded. Our laboratory and clinical observations support the existence of multiple inputs into the anterior spinal artery. This impressive collateral network is able to increase blood flow to the spinal cord when one or another source is reduced, and usually allows serial sacrifice of segmental vessels without significant spinal cord ischemia either during aortic cross-clamping or thereafter. The ability of the collateral circulation to compensate for loss of input is, however, limited. In consequence, acceptably low paraplegia rates are expected for limited aortic resection, but when sacrifice of a large number of intercostal and lumbar arteries is undertaken, the incidence of spinal cord ischemia is still far from ideal in clinical [10] as well as in experimental [11] situations.

Our studies thus far have suggested that the vascular remodeling necessary to restore an adequate spinal cord

Accepted for publication April 12, 2010.

Presented at the Poster Session of the Forty-sixth Annual Meeting of The Society of Thoracic Surgeons, Fort Lauderdale, FL, Jan 25–27, 2010.

Address correspondence to Dr Zoli, Department of Cardiothoracic Surgery, Mount Sinai School of Medicine, One Gustave L. Levy Pl, New York, NY 10029; e-mail: stefanozoli@gmail.com.

0003-4975/$36.00

conventional approach

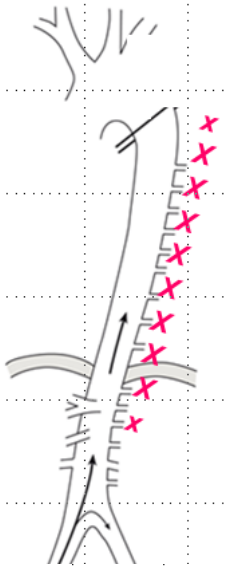

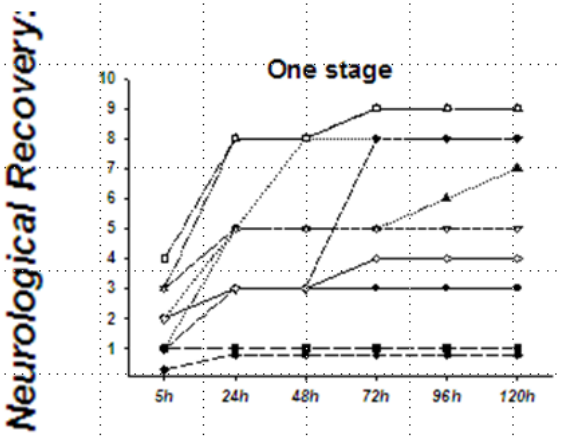

paraplegia rate: 20-30%

staged repair

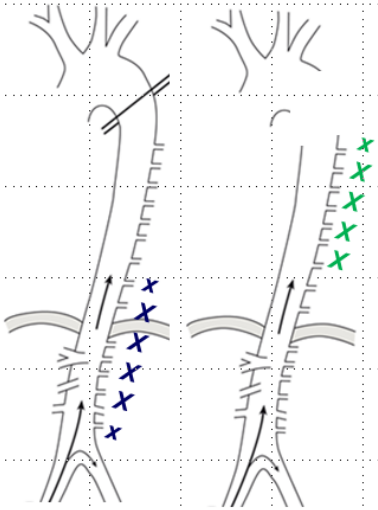

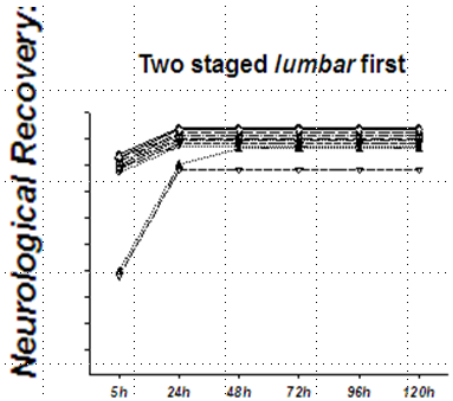

100% recovery!

conventional repair

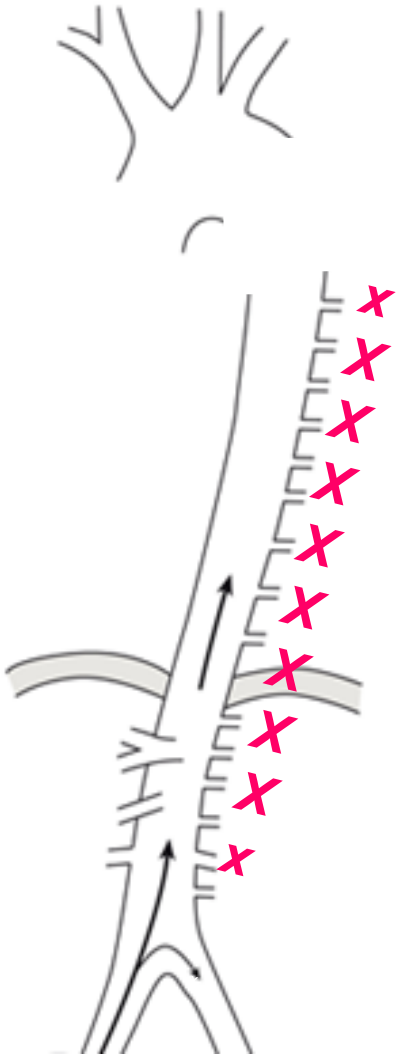

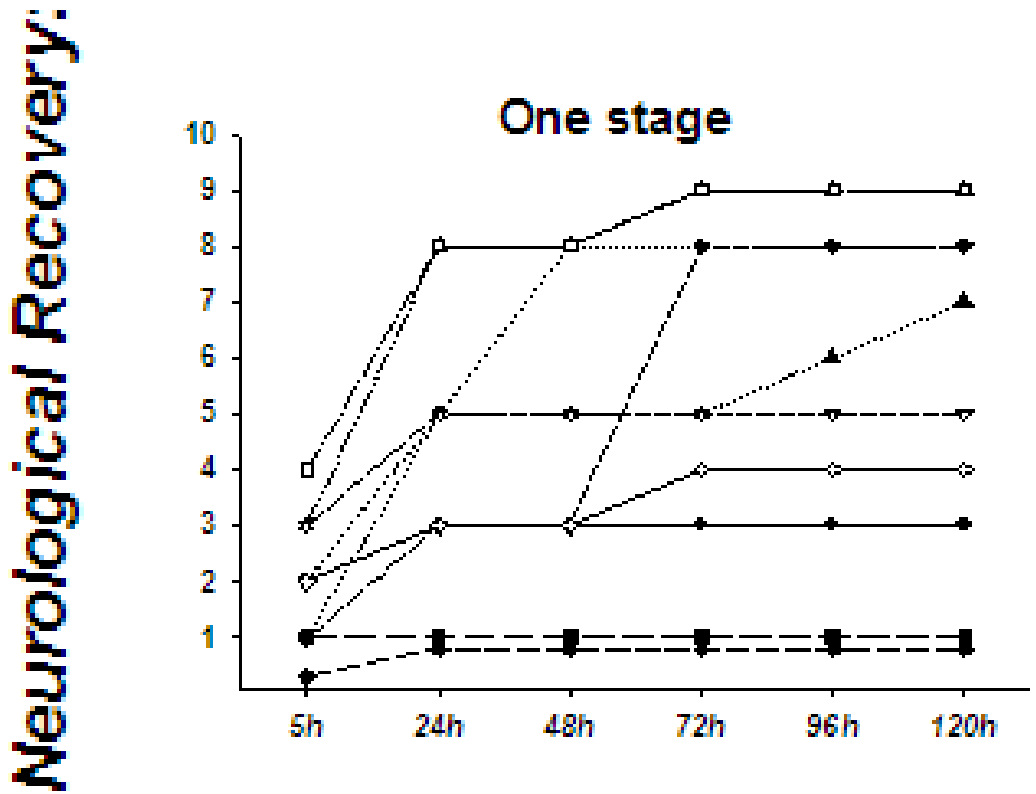

paraplegia rate: 20-30%

MOUNT SINAI SCHOOL OF MEDICINE

UNIVERSITÄT LEIPZIG HERZZENTRUM

staged repair

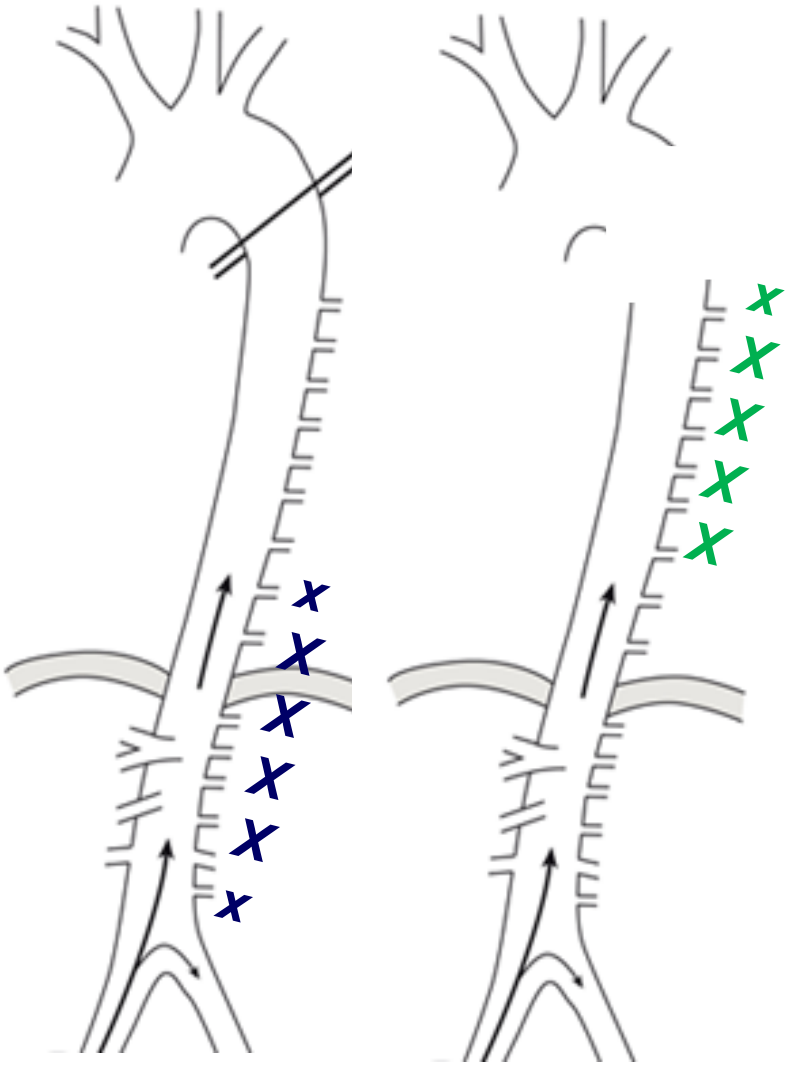

Neurological Recovery:

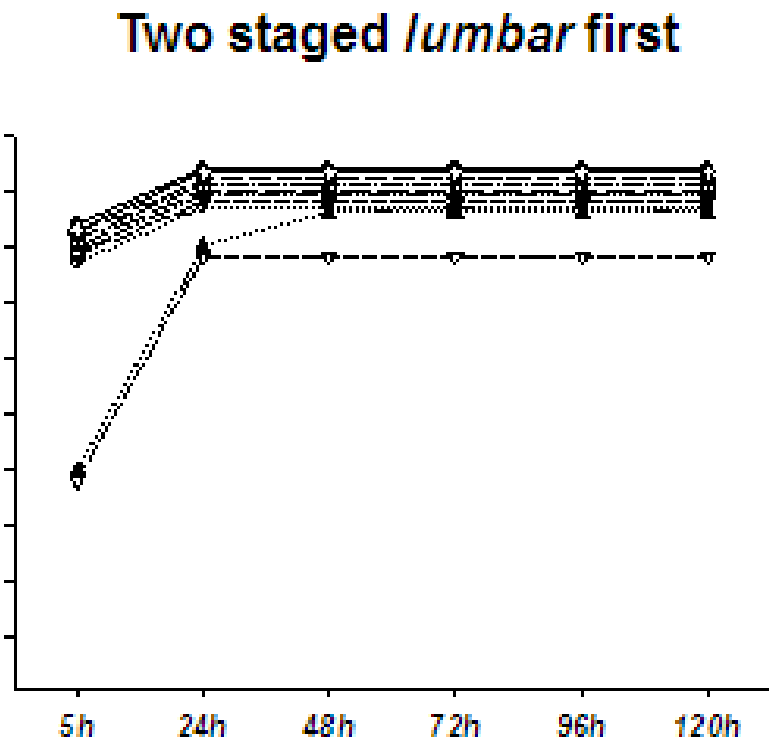

100% recovery!

After total SA Occlusion: regeneration of arterial perfusion in 5 days —

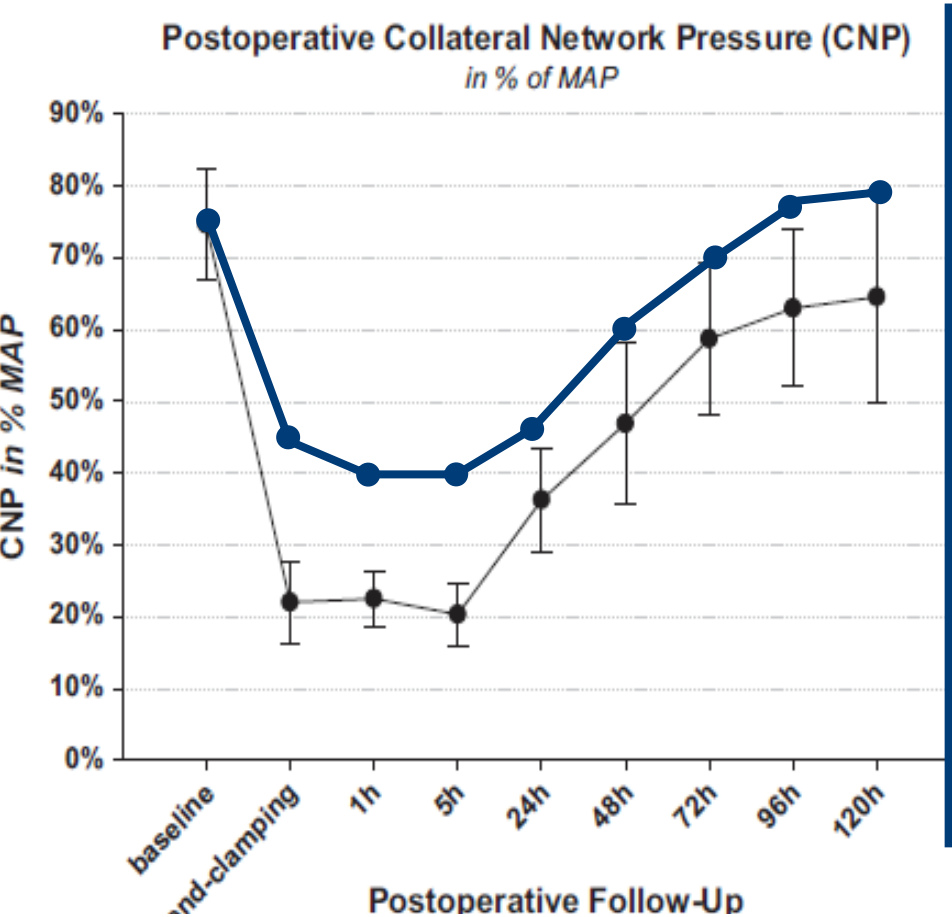

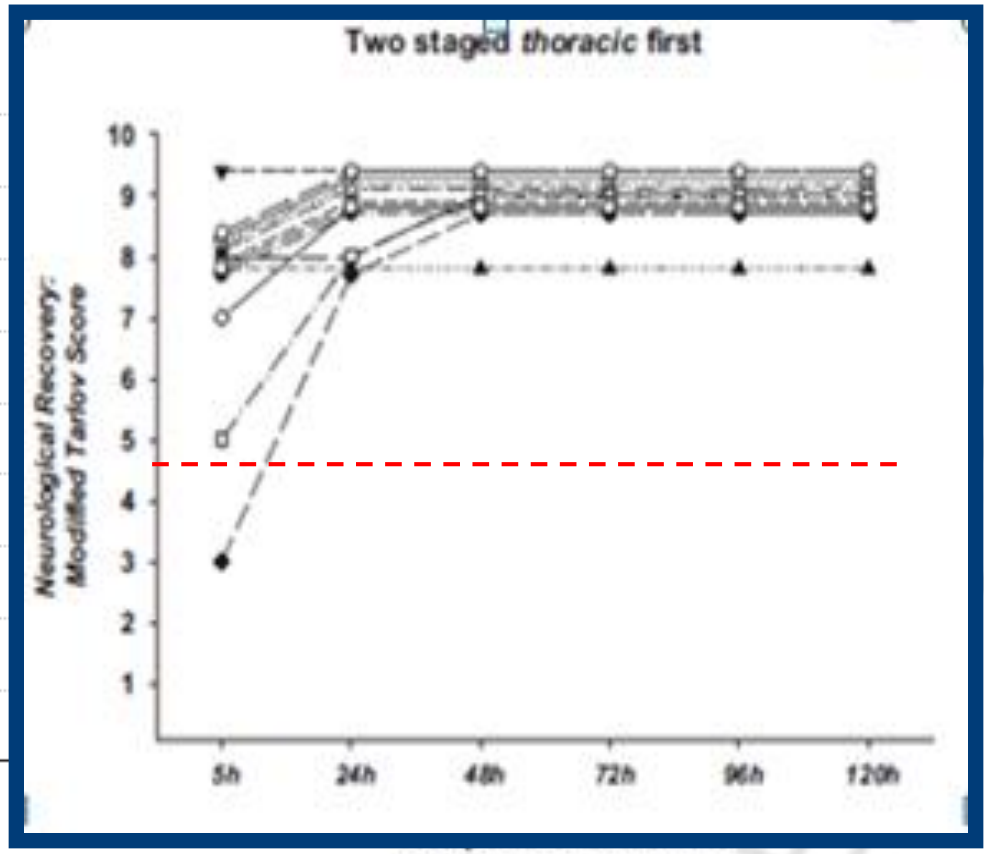

Etz et al. J Thorac Cardiovasc Surg. 2010 Dec;140(6 Suppl):S125-30

ONSET TIME OF POSTOPERATIVE PARAPLEGIA

Concept: Delayed Paraplegia, timing of delayed paraplegia, and clinical support of the "Griepp/Etz Observation"

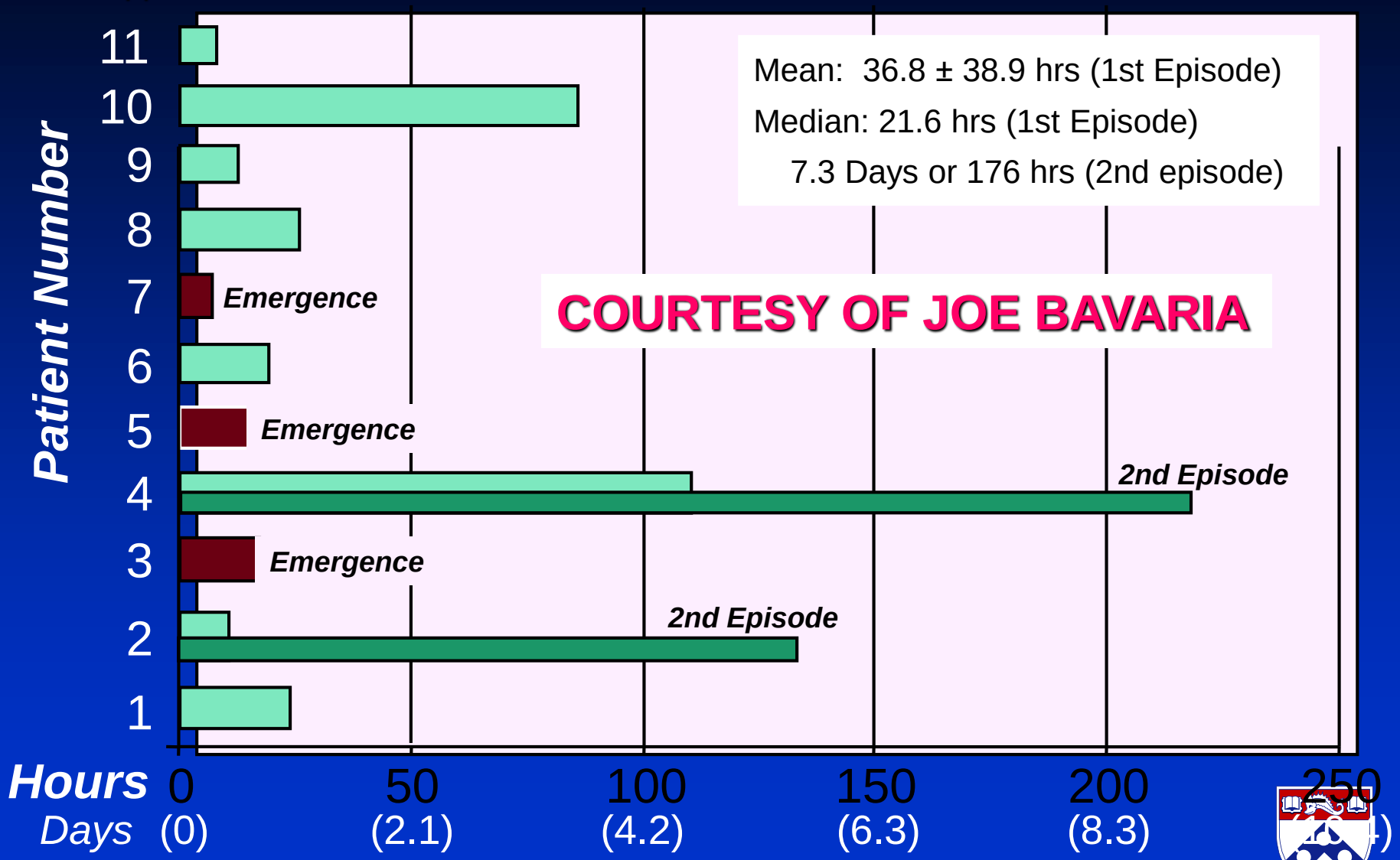

Department of Surgery, University of Pennsylvania Health System

Retrospective clinical data: significant lower incidence of SCI with ‘staged repair’ (= staged occlusion of SAs)

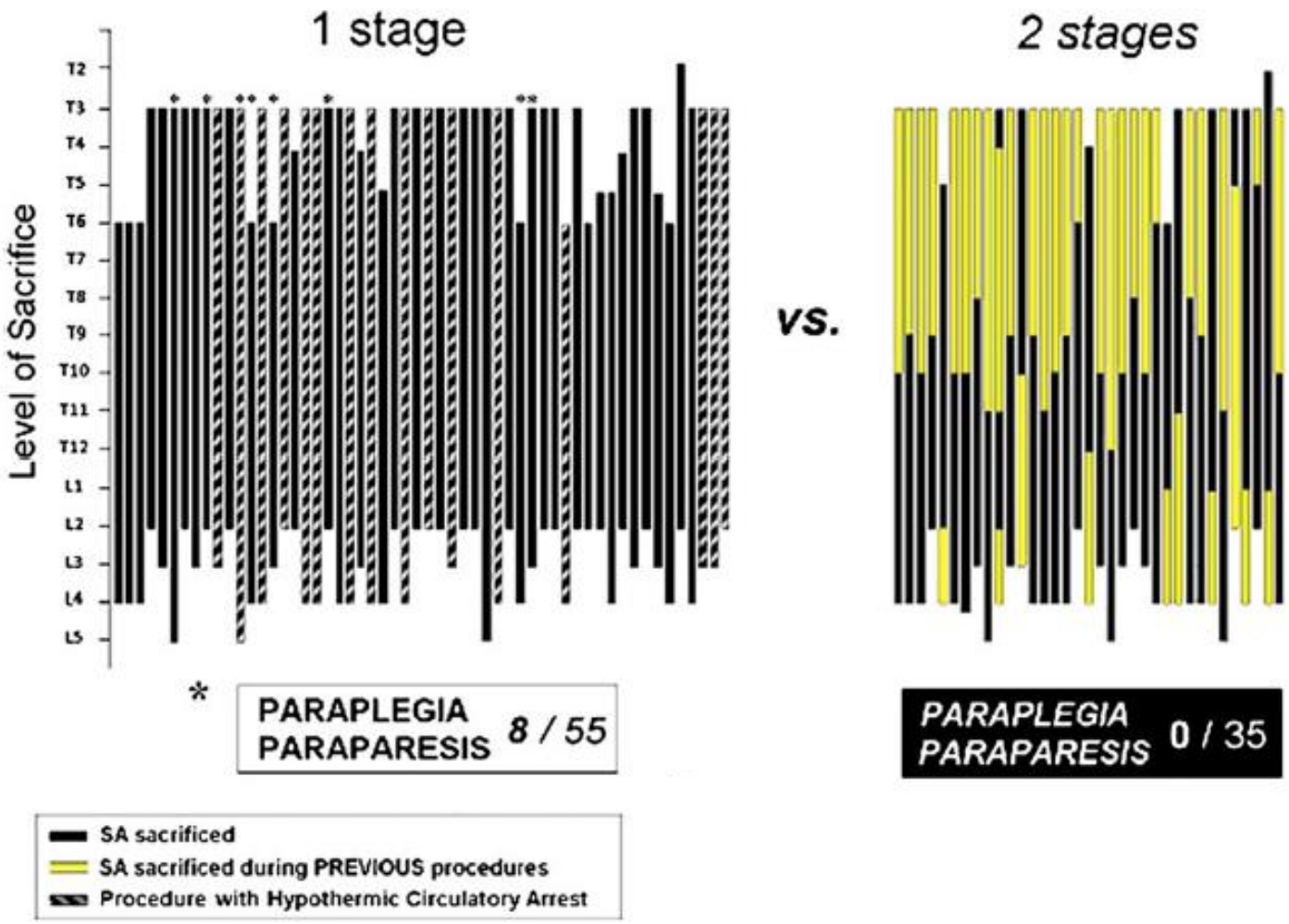

Etz et al. J Thorac Cardiovasc Surg. 2010 Jun;139(6):1464-72.

Eur J Vasc Endovasc Surg (2015) 49, 248–254

Editor's Choice — The Impact of Early Pelvic and Lower Limb Reperfusion and Attentive Peri-operative Management on the Incidence of Spinal Cord Ischemia During Thoracoabdominal Aortic Aneurysm Endovascular Repair

Staged and adjunctive procedures to preserve spinal cord flow in group 2

Following the demonstration of the potentially beneficial effects of a staged repair to encourage spinal cord pre-conditioning during extensive TAAA repair,[11] the thoracic endovascular component was implanted during the first procedure in all cases in which the anatomy was suitable (i.e., when a distal sealing zone with a maximum diameter <42 mm was present). Every effort was made to maintain the perfusion of at least one internal iliac artery (IIA); if required, iliac branched devices were employed. When left subclavian artery (LSA) coverage was deemed necessary for proximal seal, carotid subclavian transposition or bypass was performed as an initial procedure. These "first stage" procedures were performed 6–10 weeks before definitive TAAA repair.

management significantly reduces SCI following type I–III TAAA endovascular repair. With the use of these modified protocols, extensive TAAA endovascular repairs are associated with low rates of SCI.

Article history: Received 24 August 2014, Accepted 25 November 2014, Available online 6 January 2015

Keywords: Endovascular repair, Peri-operative management, Spinal cord ischemia, Thoracoabdominal aortic aneurysm

group 1
conventional endo

14.0% SCI

group 2
+ lower limb perfusion
+ post op maintanance of high blood pressure
+ staged procedure

1.2% SCI

UNIVERSITÄT LEIPZIG
HERZZENTRUM

EXPERIMENTAL ‚PRIMING' OF THE COLLATERAL NETWORK

Hypothesis: Preemptive Conditionig with Minimally Invasive Segmental Artery Coilembolisation (MISACE) may help to prevent SCI

J Thorac Cardiovasc Surg. 2014 January ; 147(1): 220–226. doi:10.1016/j.jtcvs.2013.09.022.

Endovascular Coil Embolization of Segmental Arteries Prevents Paraplegia After Subsequent TAAA Repair – An Experimental Model

S Geisbüsch, MD[1], A Stefanovic[1], JS Koruth, MD[2], HM Lin, SoD[3], S Morgello, MD[4], DJ Weisz, MD[5], RB Griepp, MD[1], and G Di Luozzo, MD[1]

[1]Department of Cardiothoracic Surgery, Mount Sinai Medical Center, New York, NY

[2]Department of Cardiology, Mount Sinai Medical Center, New York, NY

[3]Department of Health Evidence and Policy, Mount Sinai Medical Center, New York, NY

[4]Department of Neuropathology, Mount Sinai Medical Center, New York, NY

[5]Department of Neurology, Mount Sinai Medical Center, New York, NY

Abstract

Objective—To test a strategy for minimizing ischemic spinal cord injury (SCI) following extensive thoracoabdominal aneurysm (TAAA) repair, we occluded a small number of segmental arteries (SAs) endovascularly one week before simulated aneurysm repair in an experimental model.

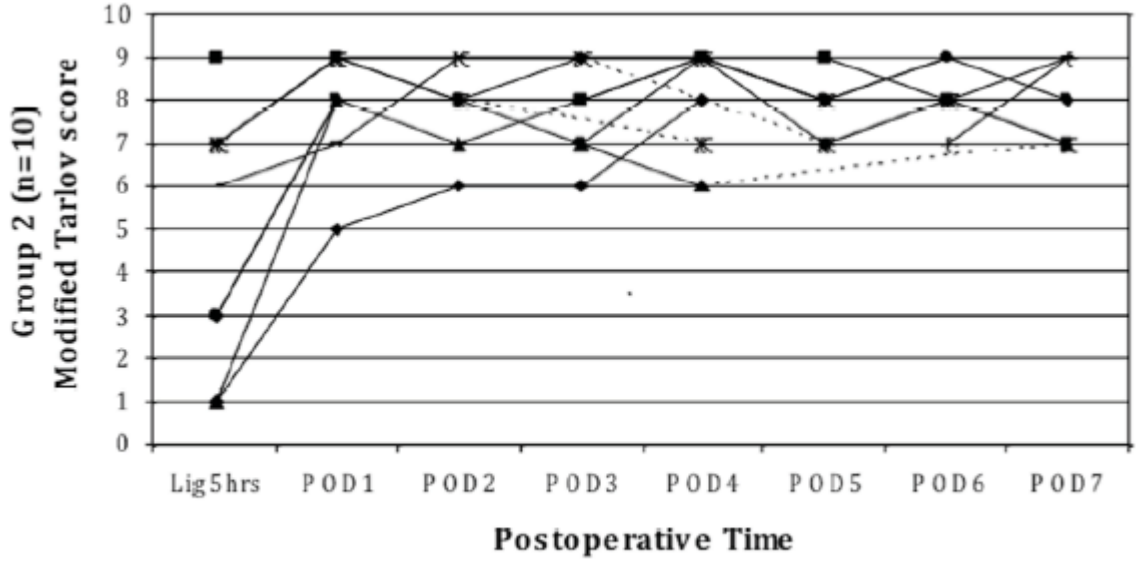

no histologic damage in coiled areas

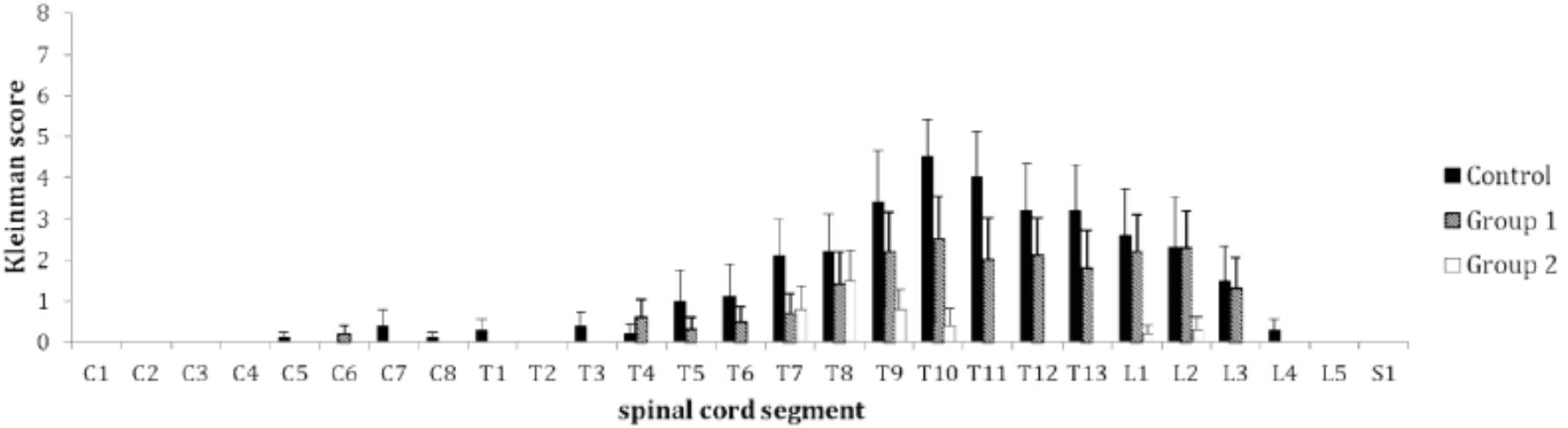

Figure 3. Histological outcome
This figure shows the average Kleinman score per group for each individual level of the spinal cord: higher scores indicate greater histopathological damage, as detailed in the text. Spinal cord damage was most prominent in the T9–T13 region. Almost no necrosis is seen in the coiled region (T11-L3) for Group 2.

Geisbüsch et al.

UNIVERSITÄT LEIPZIG
HERZZENTRUM

zero paraplegia after coil embolization

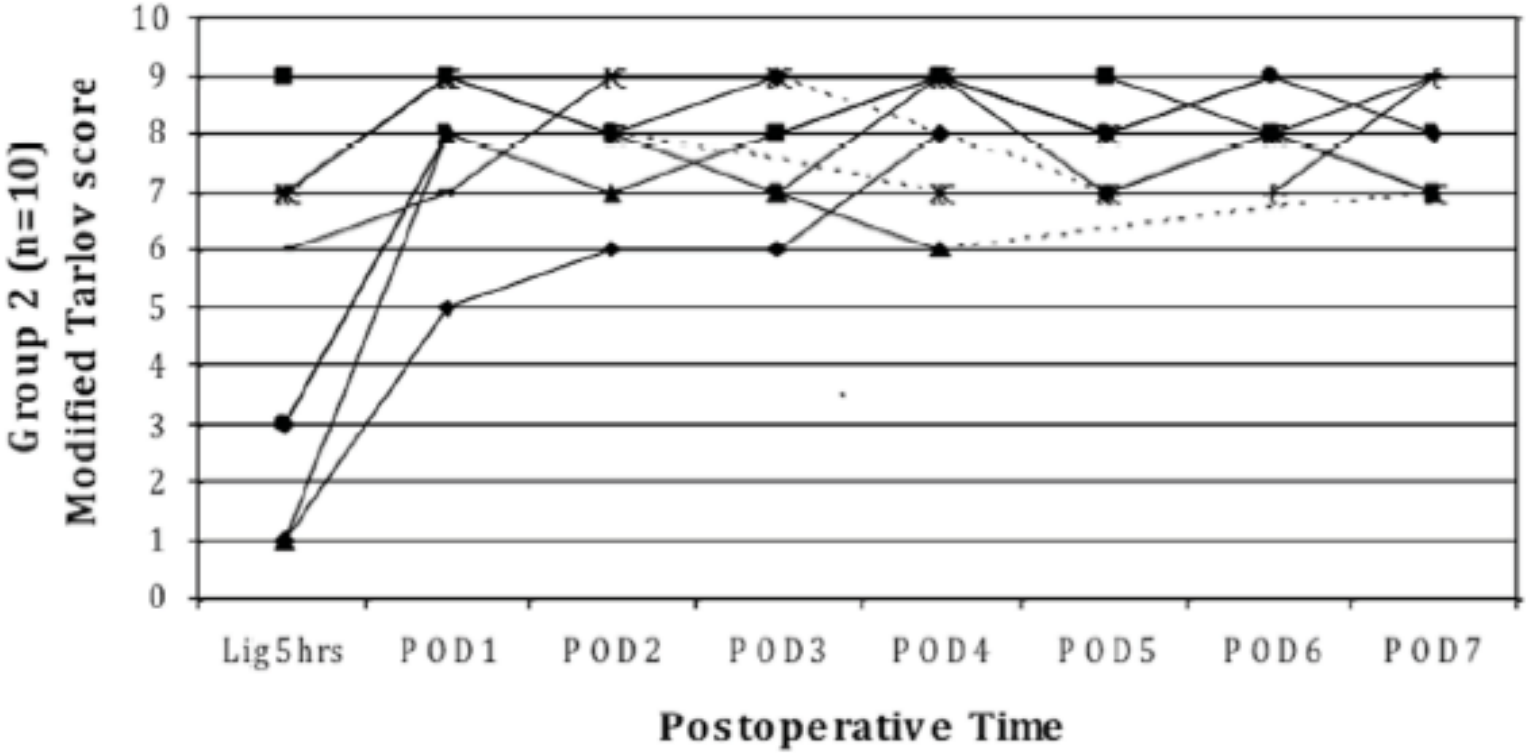

Geisbüsch et al.

UNIVERSITÄT LEIPZIG
HERZZENTRUM

‚FIRST-IN-MAN‘ EXPERIENCE

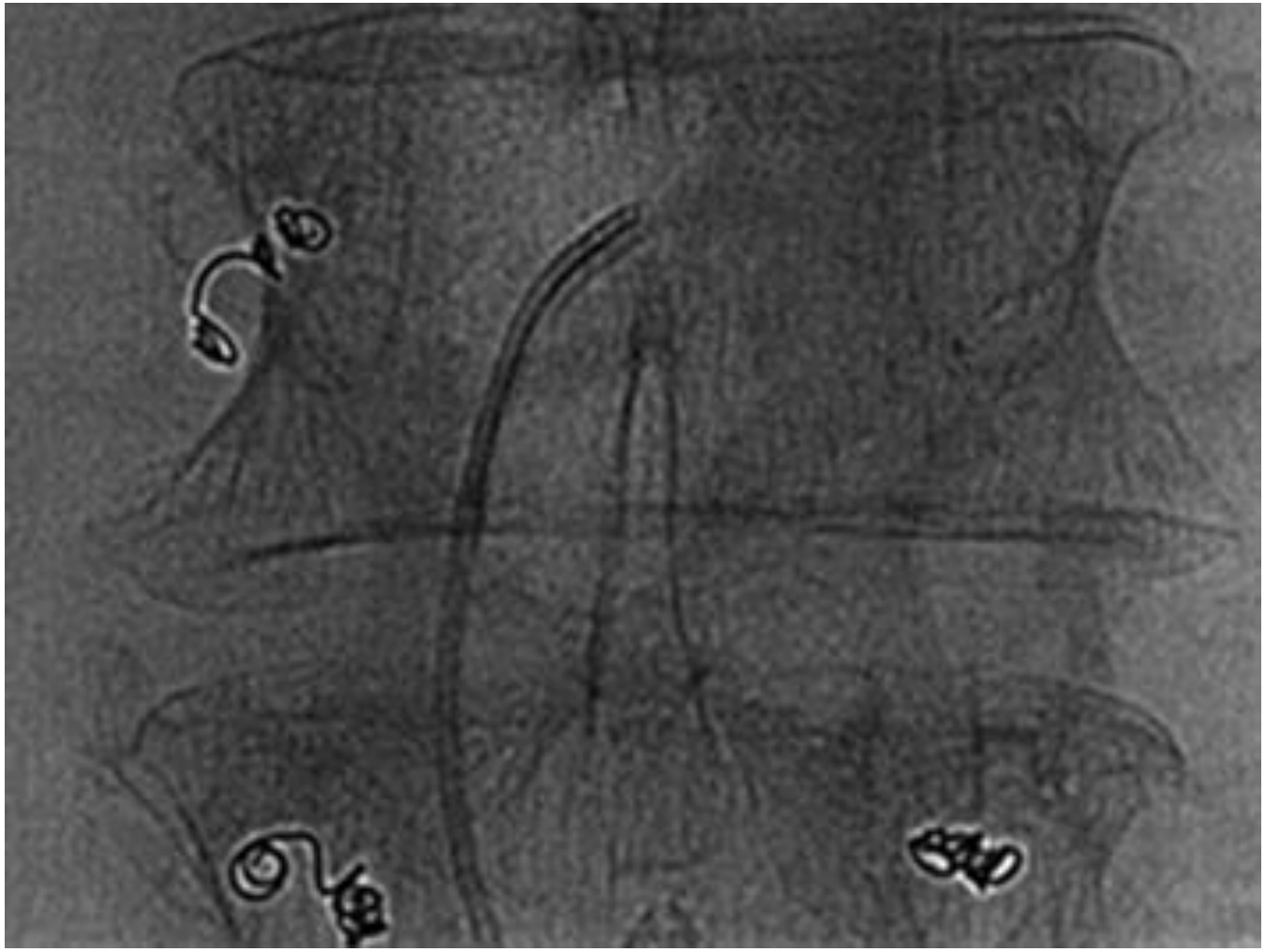

Etz *et al. J Thorac Cardiovasc Surg.* ***2015*** *Apr;149(4):1074-9*

MISACE

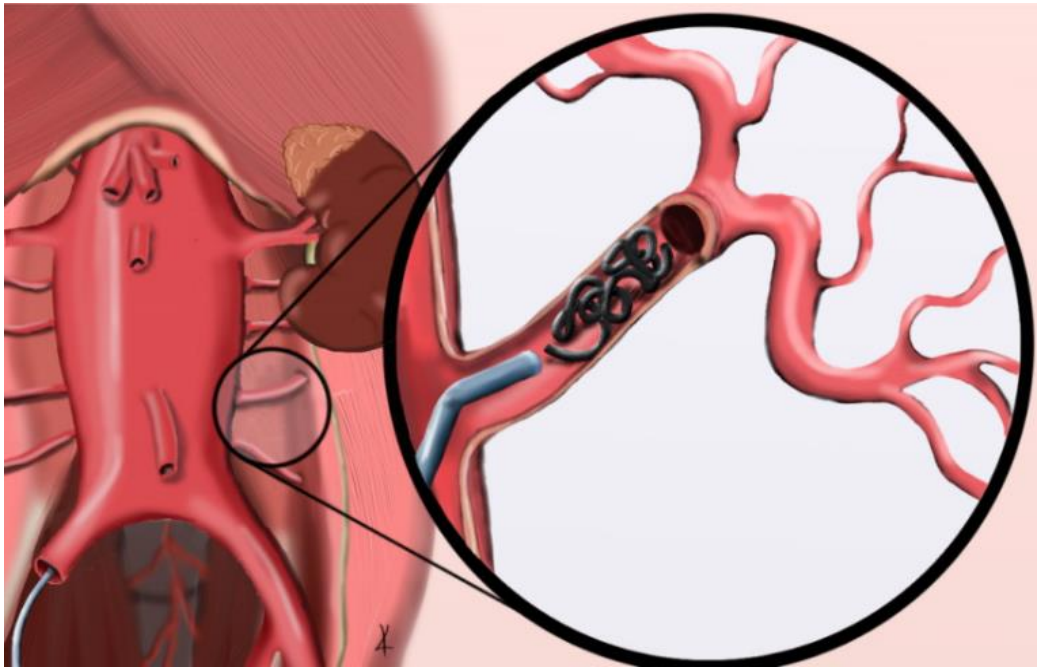

Minimally invasive coil deployment - schematically

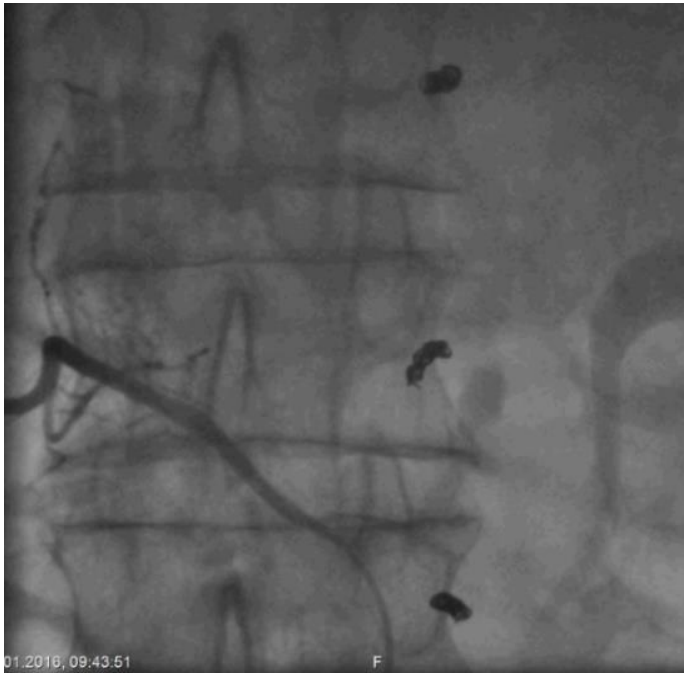

Coil-occluded (right) / patent SA (left)

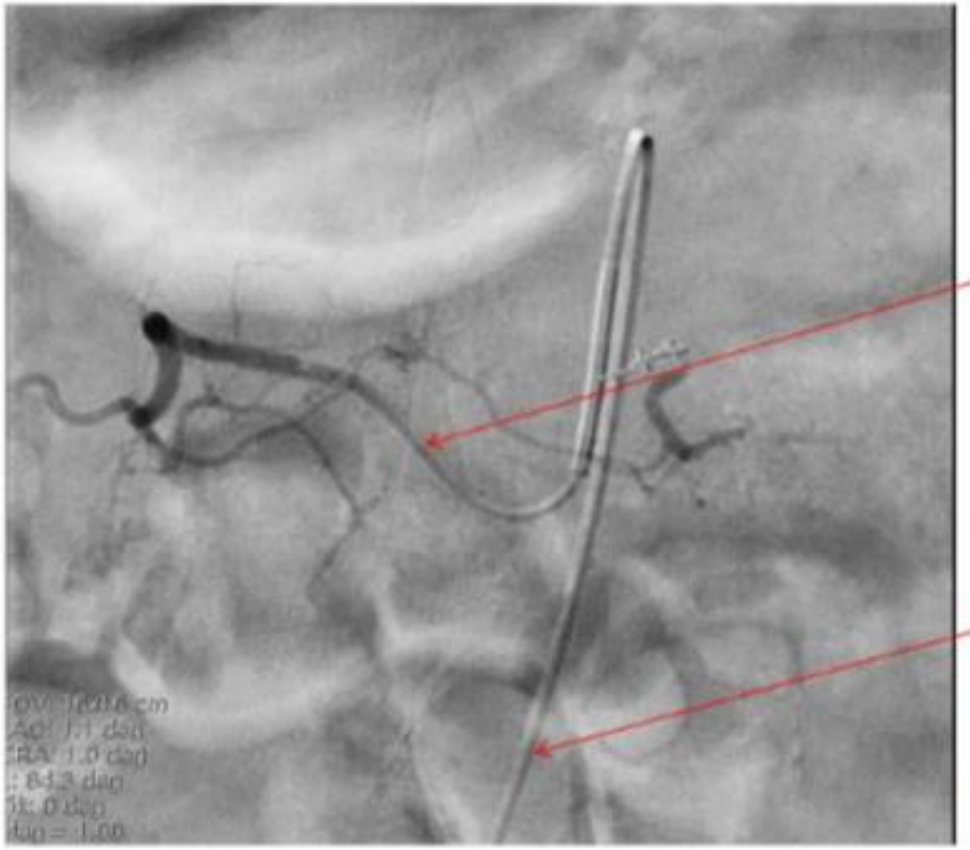

Progreat Microcatheter (Terumo)

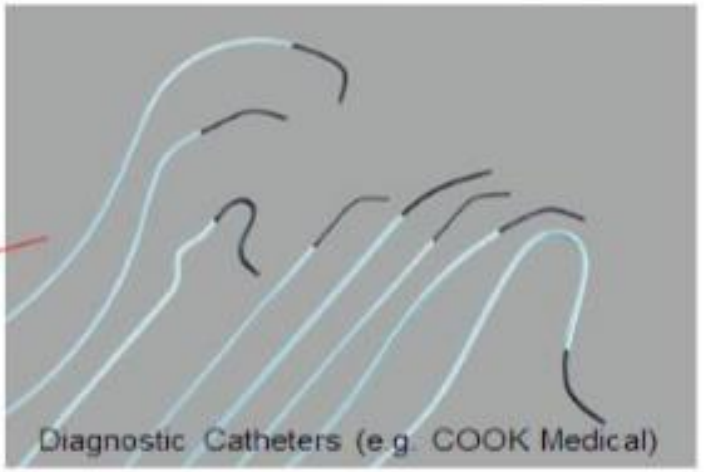

MISACE – pt #1

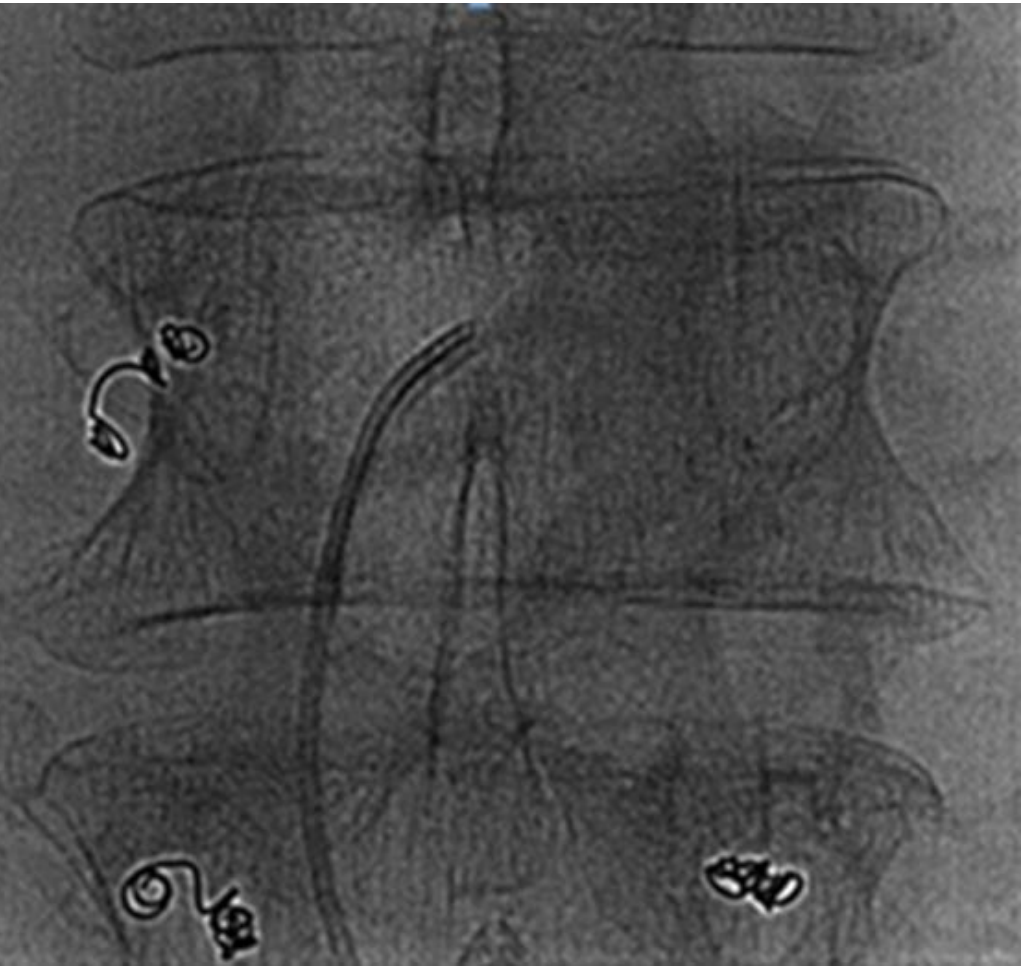

Conventional open repair

as 2nd-stage

- **1-month interval**
- **conventional repair**
- Intra op course uneventful
- no significant back bleeding
- short cross clamp time

discharged home w/o neurological impairment

MISACE – pt #2

UNIVERSITÄT LEIPZIG
HERZZENTRUM

Universitäres Herzzentrum Hamburg

Endovascular repair
2nd-stage

- **8 week interval**
- **Endo repair** with a **four-branched stent-graft** (T-branch, CE-marked, Cook Medical, Bjaeverskov, Denmark) in general anesthesia with adjunctive CSF-drainage
- all remaining open SAs between the T7 and the infrarenal aorta occluded **w/o endoleakage**

discharged home w/o neurologic deficit on POD #8

UNIVERSITÄT LEIPZIG
HERZZENTRUM

Universitäres Herzzentrum Hamburg

UNIVERSITÄT LEIPZIG
HERZZENTRUM
Universitäres Herzzentrum Hamburg

ACD

EDITORIAL COMMENTARY

Setting the stage: Thoracoabdominal aortic aneurysm repair in 2 acts

Grayson H. Wheatley III, MD

‚There are several important breakthroughs relating to managing and preventing spinal cord injury that have been simultaneously brought together with the MISACE technique.‘

‚The first is that optimal perioperative management […] is not enough to prevent cord ischemia.‘

‚The second breakthrough represented by the MISACE technique is the capacity to selectively coil-embolize segmental arteries.‘

to the arterial perfusion of the spinal cord. Once surgeons

of 4 weeks.[3] This interval allows for physiologic recruitment

The second breakthrough represented by the MISACE technique is the capacity to selectively coil-embolize

concept of staging TAAA repairs, both open and endo-

from coil-embolizing a unilateral segmental artery. Moreover, once the vessel is selectively cannulated, it is important to preserve as much of the collateral network as possible by only occluding the ostium of the segmental artery. These techniques are not within the realm of most aortic surgeons and frequently multidisciplinary collaboration is required.

2. Etz CD, Kari FA, Mueller CS, Brenner RM, Lin HM, Griepp RB. The collateral network concept: remodeling of the arterial collateral network after experimental segmental artery sacrifice. *J Thorac Cardiovasc Surg*. 2011;141:1029-36.
3. Etz CD, Debus ES, Mohr WF, Kobel T. First in man endovascular pre-conditioning of the paraspinal collateral network by segmental artery coil-embolization to prevent ischemic spinal cord injury. *J Thorac Cardiovasc Surg*. 2015;149:1074-9.

CREATING EVIDENCE
RCT ‚PAPAartis‘ starting in 2017

Paraplegia Prevention in Aortic Aneurysm Repair by Thoracoabdominal Staging with ‘Minimally-Invasive Segmental Artery Coil-Embolization (MISACE)’:

A Randomized Controlled Multicentre Trial (PAPA_ARTiS)

Trial duration	First patient in to last patient out (months): 40 Duration of the entire trial (months): 46 Recruitment period (months): 24

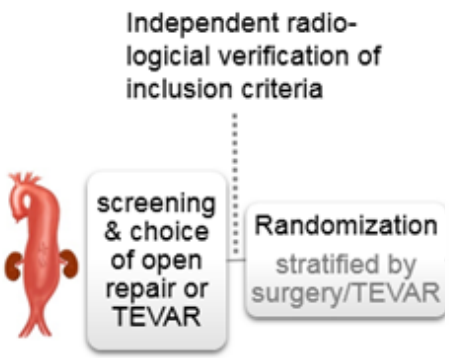

	Efficacy: In the control arm success is expected in 75% of patients compared to 90% in the experimental (MISACE staging) arm. Description of the primary efficacy analysis and population: Mixed logistic regression
Sample size	To be assessed for eligibility: **n = 450** To be assigned to the trial: **n = 306** To be analysed: **n = 160 (interim 1), 220 (interim 2), 275 (final)**
	Secondary endpoints: Analysis of binary outcomes will be analogous to the primary analysis. ICU time will be analysed with a linear mixed model. Re-operation and endo-leak will be considered for the subgroups of surgery/TEVAR respectively.

PAPA_ARTiS **EUROPE** – Horizon 2020 funded with 6.3M €

1. CH: Bern
2. DE: Freiburg
3. DE: Hamburg
4. DE: Leipzig
5. FR: Bordeaux
6. FR: Lille
7. IT: Bologna
8. IT: Milan
9. NL: Maastricht
10. PL: Zabrze
11. SE: Malmö
12. SE: Örebro
13. UK: Liverpool
14. US: Houston
15. US: Philadelphia

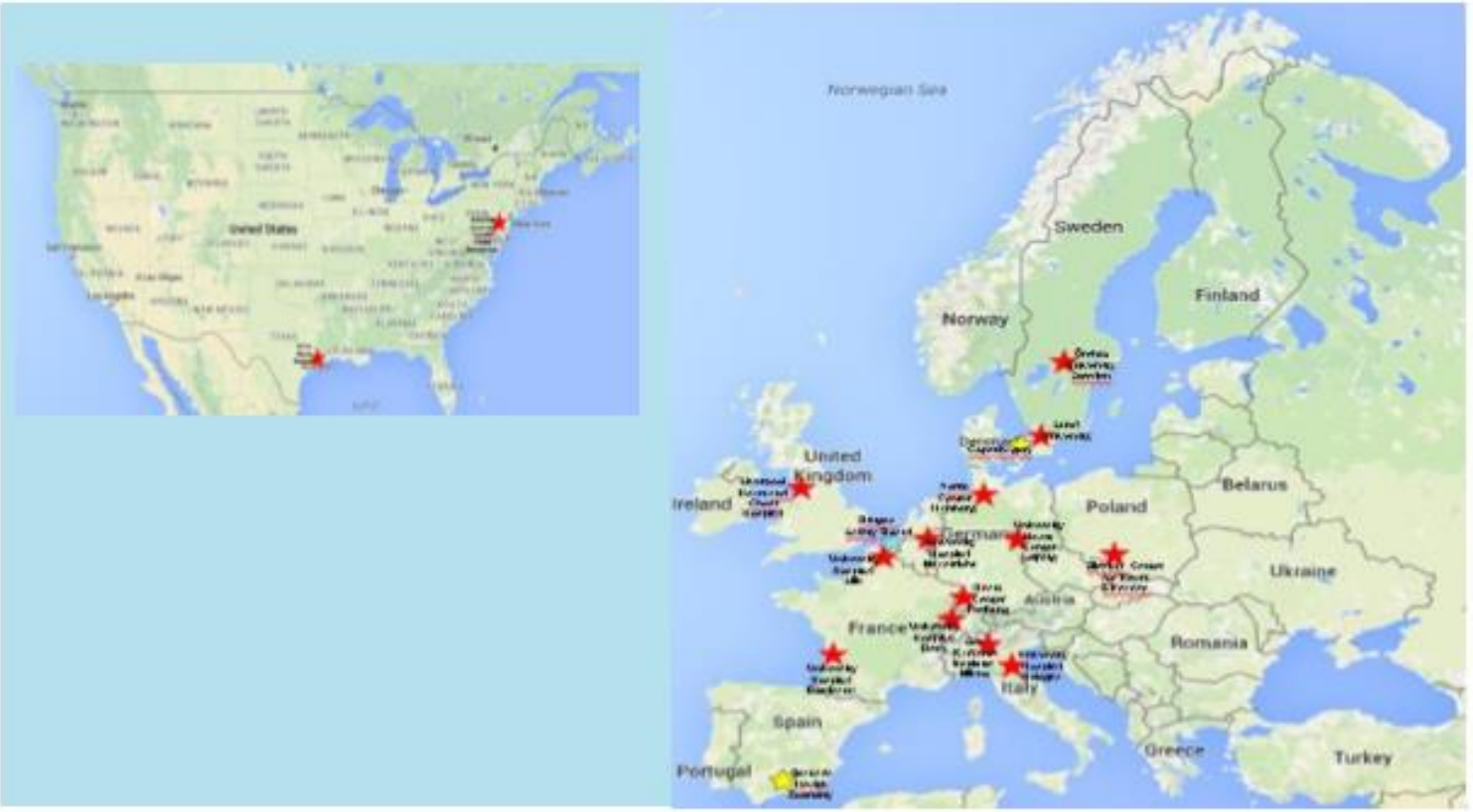

Figure 10 - Participating centres PAPA-ARTiS (EU, Switzerland and the US). Red stars represent recruitment centres and the yellow stars represent the radiology core lab (Copenhagen, WP6) and the health economics group (Grenada, WP3).

starting in 2017

UNIVERSITÄT LEIPZIG
HERZZENTRUM

PAPA_ARTiS **EUROPE**

Side project #1 – Near-Infrared real-time Monitoring of the Collateral Network (real-time cnNIRS)

Experimental setup

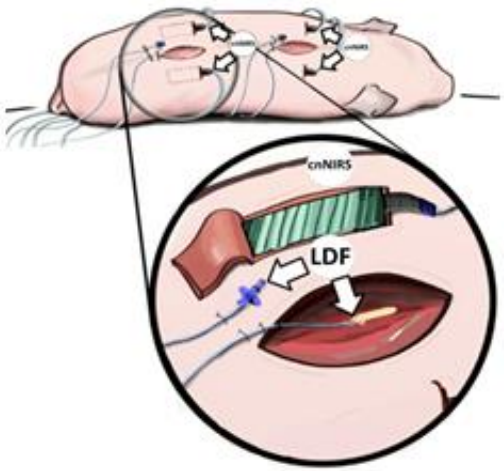

Non-invasive cnNIRS

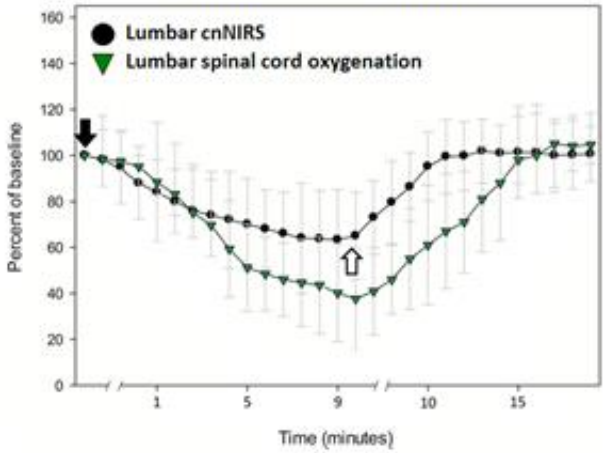

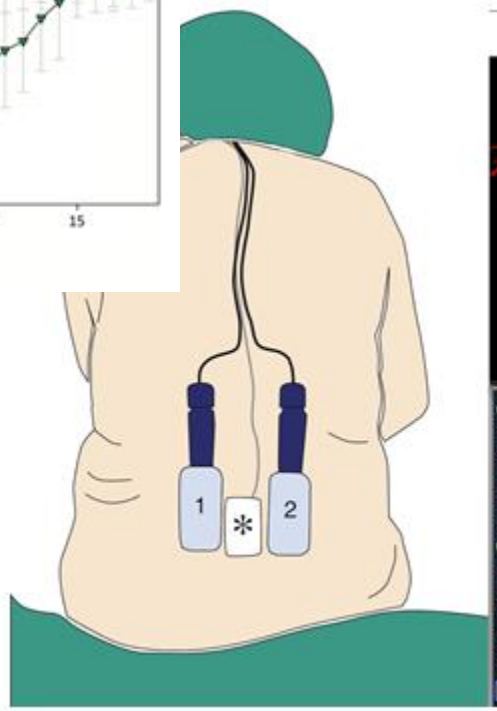

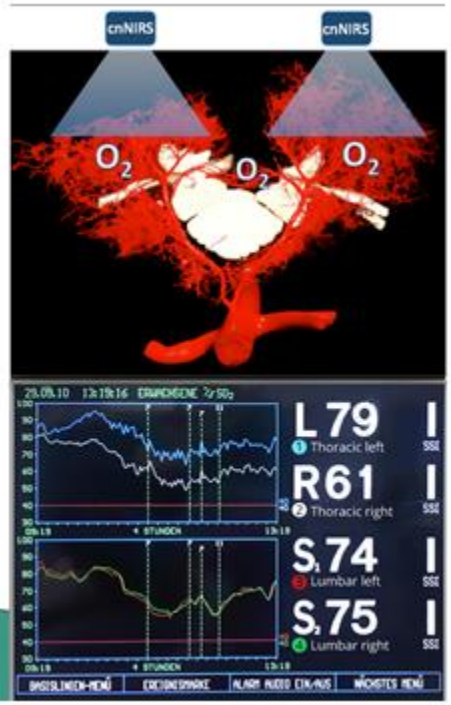

UNIVERSITÄT LEIPZIG
HERZZENTRUM

PAPA_ARTiS **EUROPE**

Side project #3 ICCAS: Patient-based individual modeling of Paraspinal Collateral Network Perfusion after Segmental Artery Occlusion (Pim-PaP)

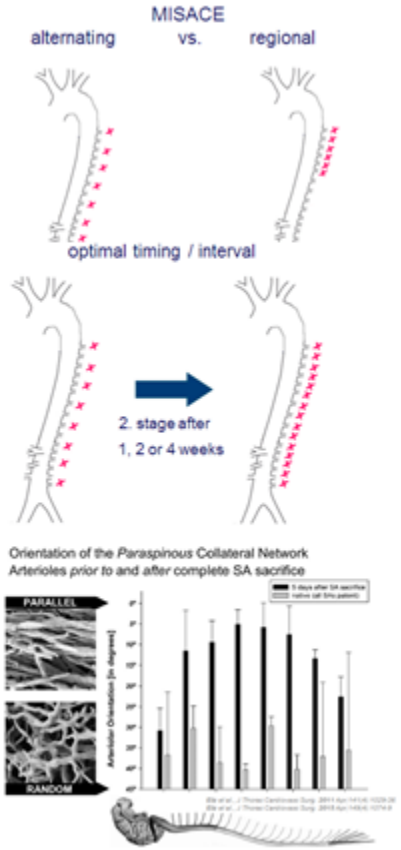

spin labeled 4D MRI

UNIVERSITÄT LEIPZIG
HERZZENTRUM

DISCUSSION

INCIDENCE

Inzidenz der Paraplegie Endo / Stentgraft

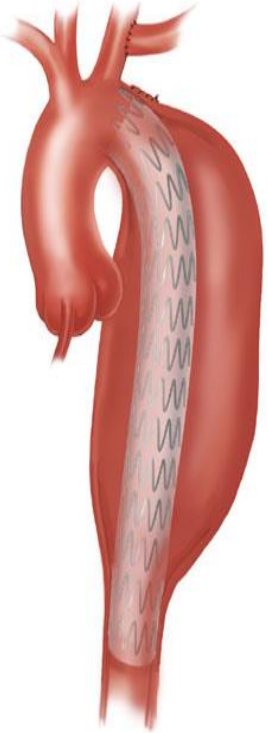

endo	Year	N	DTA	Type I	Type II	Type III	Type IV
Greenberg et al.[3] **	2008	352	1%	10%	**19%**	5%	3%
Gravereaux et al.[4]	2001	53	5.7%	#	#	#	#
Conrad et al.	2008	105	7%	#	#	#	#
Bavaria et al.[5]	2007	140	3%	#	#	#	#

** "***The severity of the SCI*** *(paraplegia versus paraparesis) and the potential for recovery did not differ between treatment modalities … **SCI was more commonly noted immediately after OPEN REPAIR** (29% versus 13%) **and in a delayed presentation** (up to 6 days) **after ER"***

UNIVERSITÄT LEIPZIG HERZZENTRUM

Inzidenz der Paraplegie offene Chirurgie

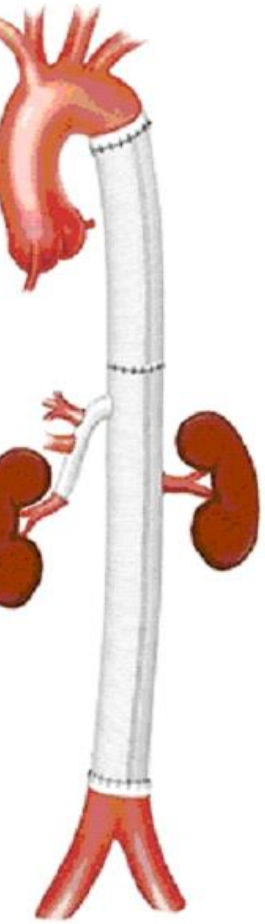

Open Surgery	year	N	DTA	**Type I**	**Type II**	**Type III**	**Type IV**
Greenberg et al	2008	372	1%	14%	**22%**	10%	2%
Conrad et al	2008	471	7%	24%	**20%**	13%	2%
Fehrenbacher	2010	343	1%	4.3%	**5.4%**	3.1%	0%
Coselli et al.	2007	2286	#	3.3%	**6.3%**	2.6%	1.4%
Bavaria et al	2007	94	14%	#	#	#	#
Zoli et al	2010	609	2.3%	2.5%	11.5%	3.9%	2.2%
Sundt et al	2011	99	3%	0%	0%	0%	0%
Schepens et al	2009	571		Paraplegia 5.3%, paraparesis 3%			

UNIVERSITÄT LEIPZIG HERZZENTRUM

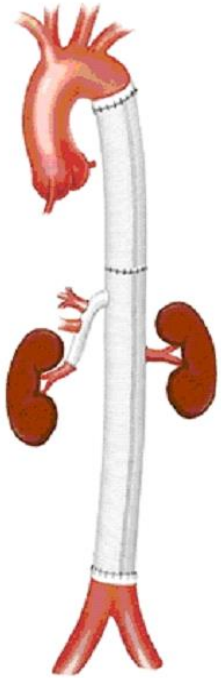

open repair

year	N	DTA	Type I	Type II	Type III	Type IV
2008	372	1%	**14%**	**22%**	10%	2%
2008	471	7%	**24%**	**20%**	13%	
2010	343	1%	**4.3%**	**5.4%**	3.1%	
2007	2286	#	**3.3%**	**6.3%**	2.6%	1.4%
2007	94	14% $$	#	#	#	#
2010	609	2.3%	2.5%	11.5%	3.9%	2.2%
2011	99	3% ##	0%	0%	0%	0%
2009	571	#	Paraplegia 5.3%, paraparesis 3%			

=

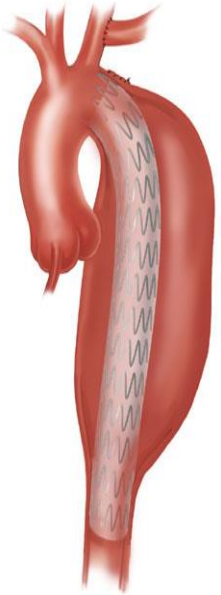

endovascular

Year	N	DTA	Type I	Type II	Type III	Type IV
2008	352	1%	10%	**19%**	5%	3%
2001	53	5.7%	#	#	#	#
2008	105	7%	#	#	#	#
2007	140	3%	#	#	#	#

!

Aortic X-clamping vs. Segmental Artery Occlusion

UNIVERSITÄT LEIPZIG HERZZENTRUM

MISACE –
side effects and Cx

CONCLUSIONS

1. staged preconditioning to significantly reduce iatrogenic SCI after TAAA-repair — now clinically available
2. much safer treatment with only 1-2 sessions in the cath lab
3. reduction of backbleeding through SAs during open repair reducing steal and shortening OR times
4. reduction of type II endoleakage after endo repair

X-clamping

ischemic Spinal Cord Injury

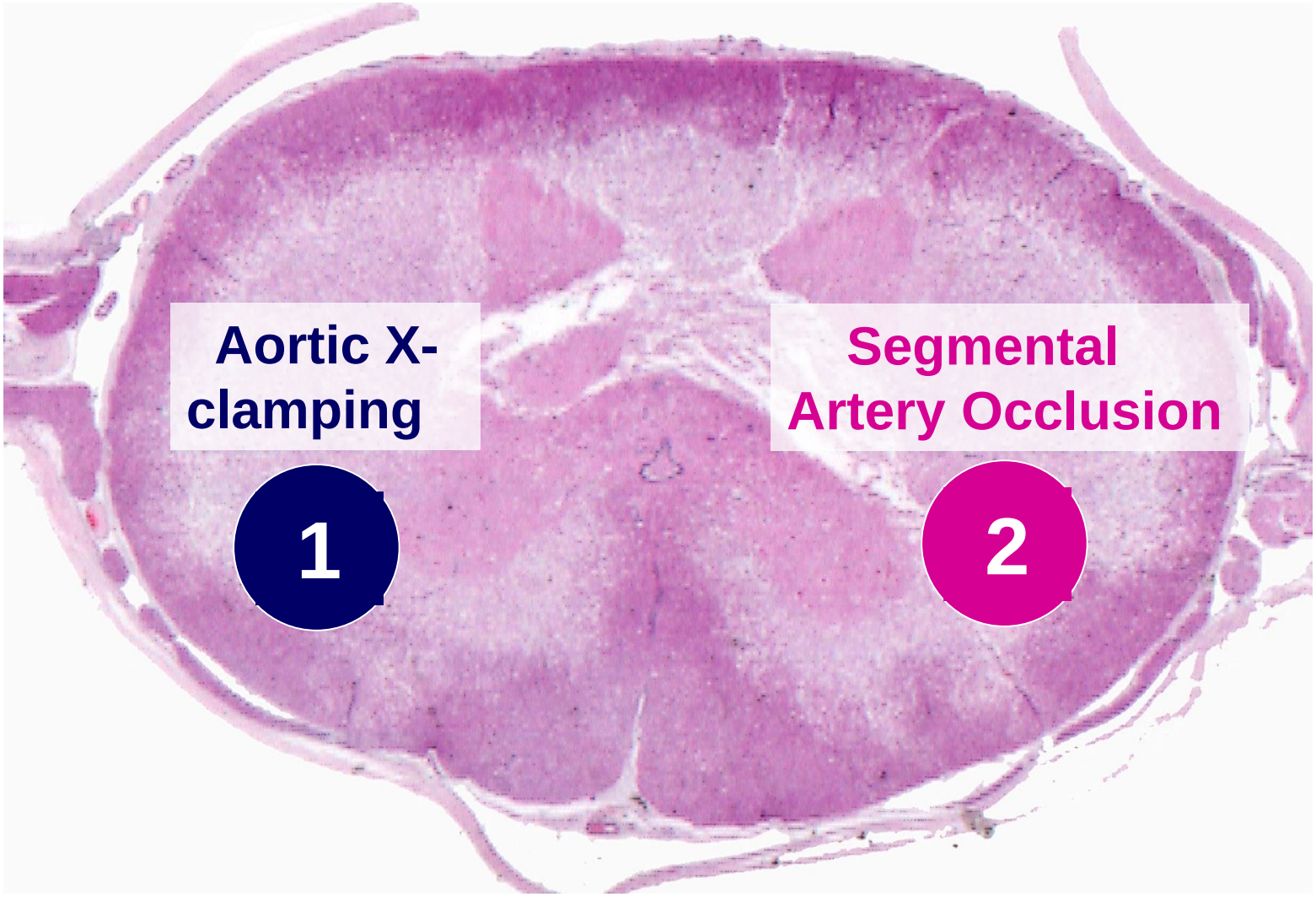

Aortic X-clamping

→ open TAA/A repair

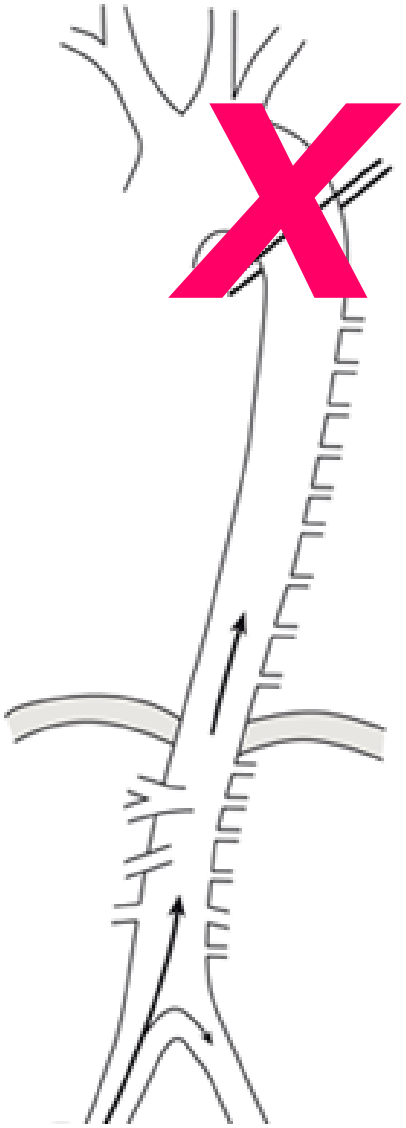

SPINAL CORD BLOOD FLOW

prior to, *during* and after SCP @ 28ºC

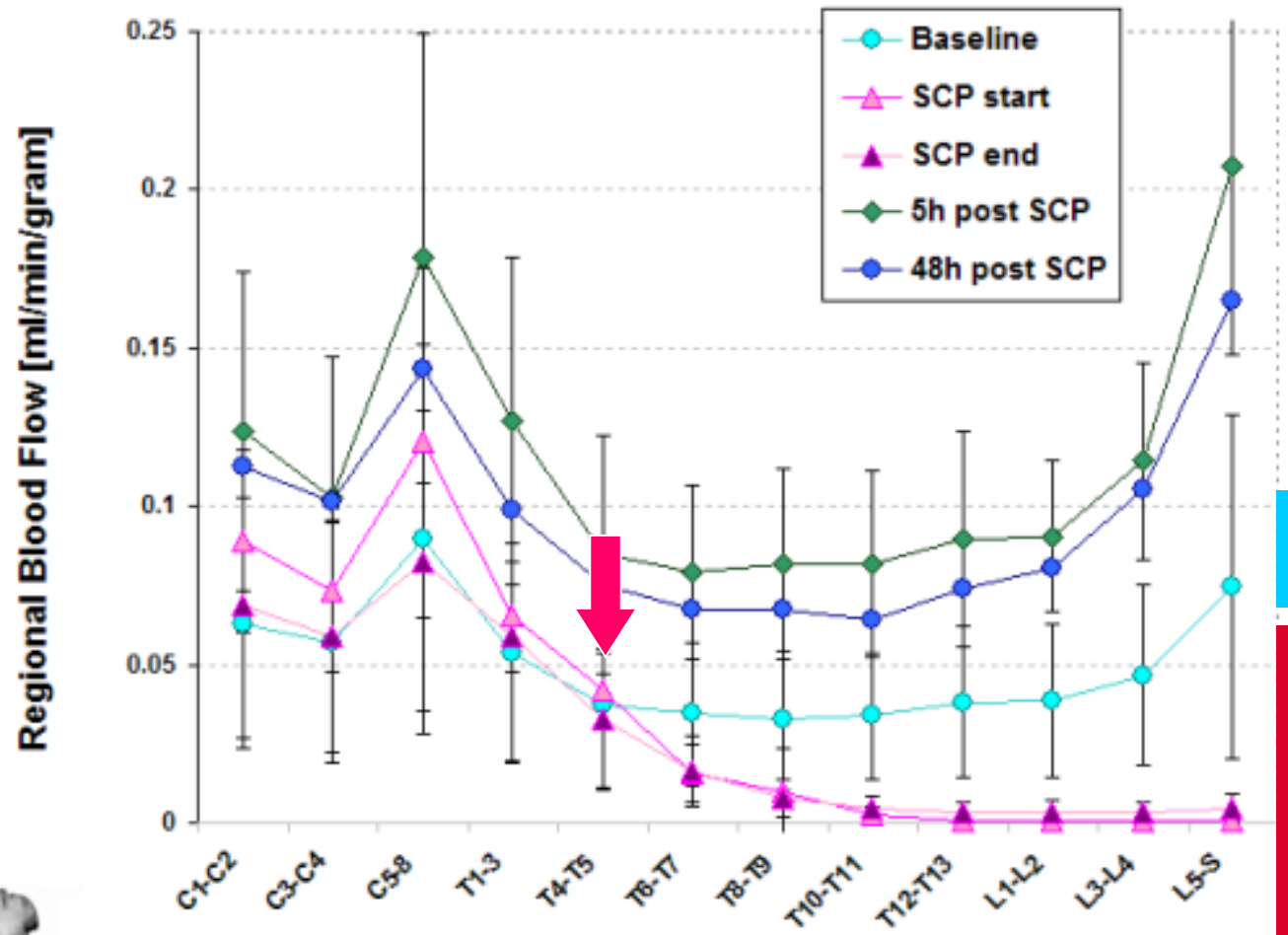

baseline flow

desc X-clamp:

NO flow

below T_8

MOUNT SINAI SCHOOL OF MEDICINE

UNIVERSITÄT LEIPZIG HERZZENTRUM

UNKNOWN

open questions to be clarified

2 Bestimmung des optimalen Okklusionsmusters

Hypothese: alternierend schnellere Arteriogenese (besser als regional)

Okklusion

alternierend (N=10) vs. regional (N=10)

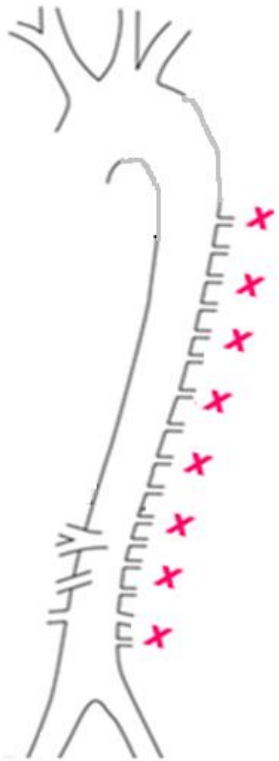

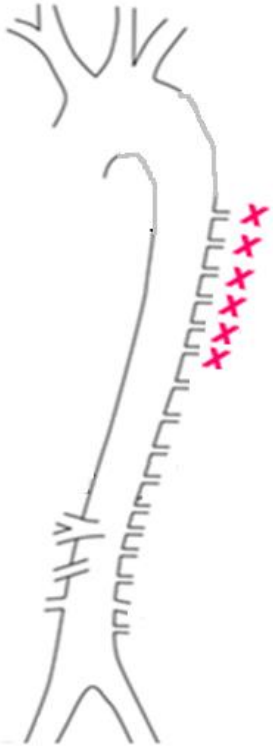

Perfusionsdruck – Blutfluß – Ultrastruktur im Verlauf

3 Optimales Timing / Intervall ?

2. Stufe nach

5, 10 oder 20 Tagen

(je N=10)

Etz *et al. J Thorac Cardiovasc Surg.* ***2008*** *Feb;135(2):324-30*
Etz *et al., J Thorac Cardiovasc Surg.* ***2011*** *Apr;141(4):1029-36*
Etz *et al., J Thorac Cardiovasc Surg.* ***2015*** *Apr;149(4):1074-9*

4 Optimales Monitoringverfahren / Validierung Tiermodell

Hypothese: Regionale Nahinfrarot Spektroskopie (NIRS) korreliert mit Kollateral Perfusion / spinaler Oxigenierung *in Echtzeit*

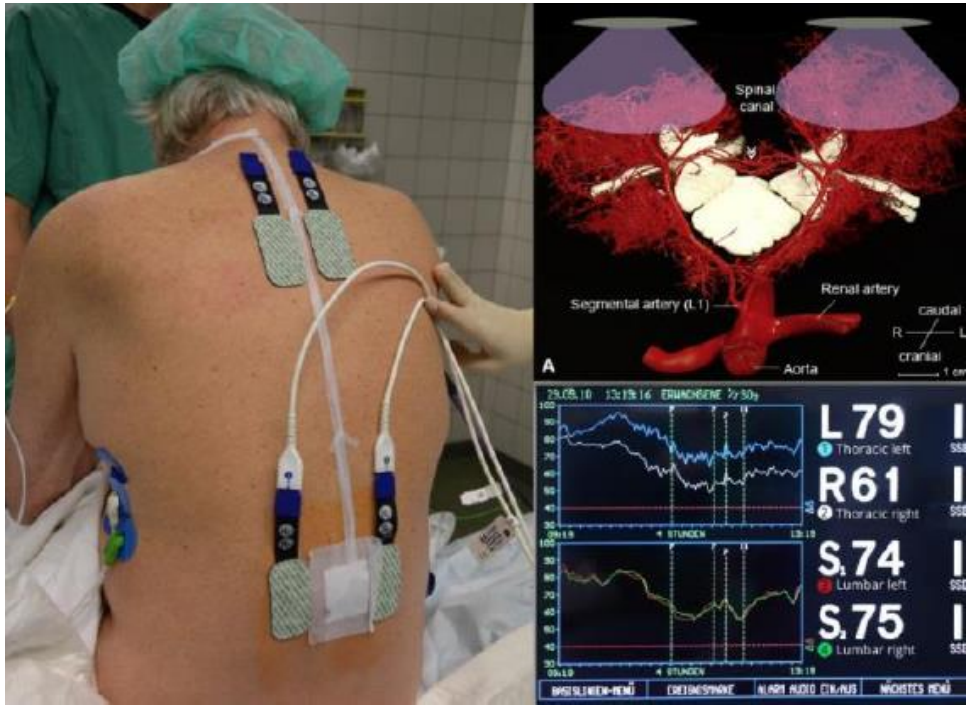

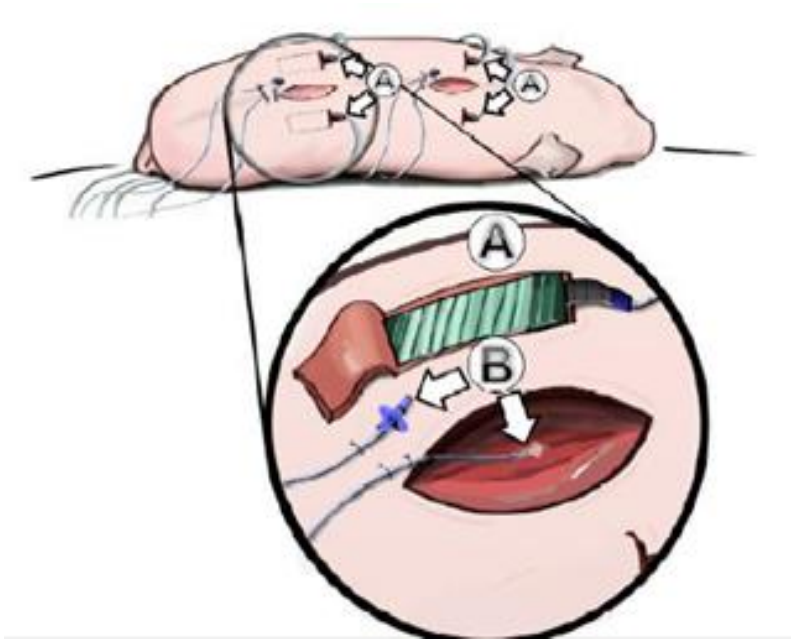

Etz *et al., Eur J Vasc Endovasc Surg.* ***2013*** *Dec;46(6):651-6*
Etz *et al., Eur J Cardiothorac Surg.* ***2015*** *Jun;47(6):943-57*

DIRECT SCPP MONITORING

ADULT CARDIAC

Direct Spinal Cord Perfusion Pressure Monitoring in Extensive Distal Aortic Aneurysm Repair

Christian D. Etz, MD, PhD, Gabriele Di Luozzo, MD, Stefano Zoli, MD, Ricardo Lazala, MD, Konstadinos A. Plestis, MD, Carol A. Bodian, DrPH, and Randall B. Griepp, MD

Departments of Cardiothoracic Surgery and Anesthesiology, Mount Sinai School of Medicine, New York, New York

Background. Although maintenance of adequate spinal cord perfusion pressure (SCPP) by the paraspinal collateral network is critical to the success of surgical and endovascular repair of descending thoracic and thoracoabdominal aortic aneurysms, direct monitoring of SCPP has not previously been described.

Methods. A catheter was inserted into the distal end of a ligated thoracic segmental artery (SA) (T6 to L1) in 13 patients, 7 of whom underwent descending thoracic and thoracoabdominal aortic aneurysm repair using deep hypothermic circulatory arrest. Spinal cord perfusion pressure was recorded from this catheter before, during, and after serial SA sacrifice, in pairs, from T3 through L4, at 32°C. Somatosensory and motor evoked potentials were also monitored during SA sacrifice and until 1 hour after cardiopulmonary bypass. Target mean arterial pressure was 90 mm Hg during SA sacrifice and after nonpulsatile cardiopulmonary bypass, and 60 mm Hg during cardiopulmonary bypass.

Results. A mean of 9.8 ± 2.6 SAs were sacrificed without somatosensory and motor evoked potential loss. Spinal cord perfusion pressure fell from 62 ± 12 mm Hg (76% ± 11% of mean arterial pressure) before SA sacrifice to 53 ± 13 mm Hg (58% ± 15% of mean arterial pressure) after SA clamping. The most significant drop occurred with initiation of nonpulsatile cardiopulmonary bypass, reaching 29 ± 11 mm Hg (46% ± 18% of mean arterial pressure) before deep hypothermic circulatory arrest. Spinal cord perfusion pressure recovered during rewarming to 40 ± 14 mm Hg (51% ± 20% of mean arterial pressure), and further within the first hour of reestablished pulsatile flow. Somatosensory and motor evoked potentials returned in all patients intraoperatively. Recovery of SCPP began intraoperatively, and in 5 patients with prolonged monitoring, continued during the first 24 hours postoperatively. All but 1 patient, who had remarkably low postoperative SCPPs and experienced paraparesis, regained normal spinal cord function.

Conclusions. This study supports experimental data showing that SCPP drops markedly but then recovers gradually during the first several hours after extensive SA sacrifice. Direct monitoring may help prevent a fall of SCPP below levels critical for spinal cord recovery after surgery and endovascular repair of descending thoracic and thoracoabdominal aortic aneurysms.

(Ann Thorac Surg 2009;87:1764–74)

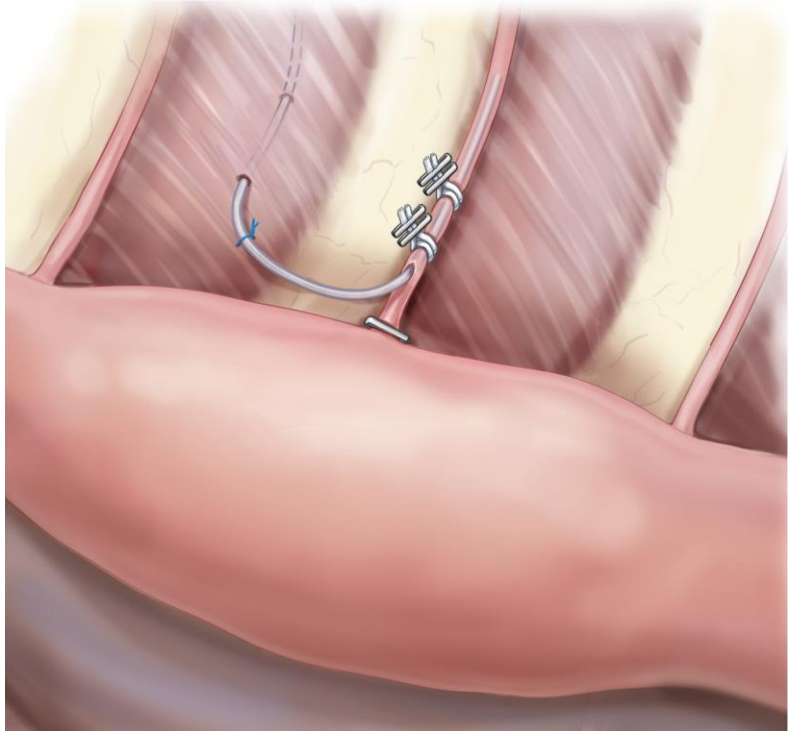

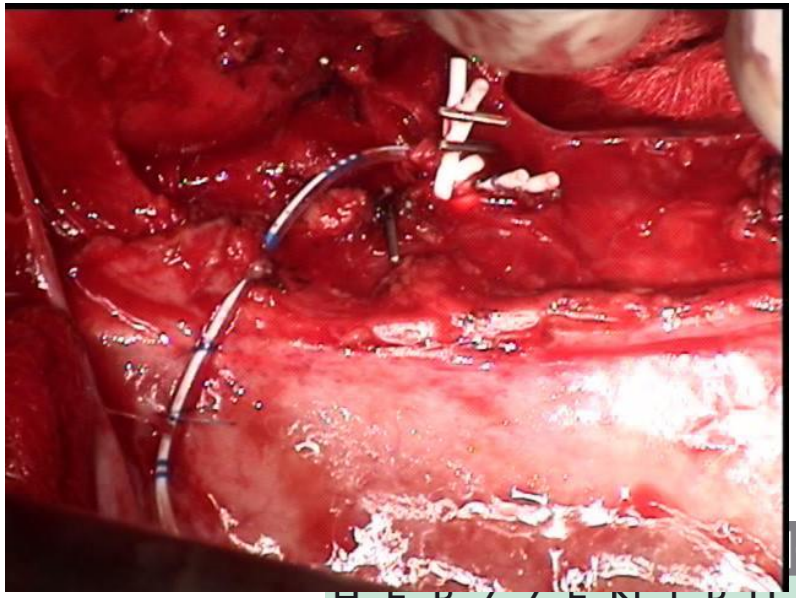

Paraplegia remains the most devastating complication after repair of extensive descending thoracic (DTA) and thoracoabdominal aortic aneurysms (TAAA). The maintenance of adequate spinal cord perfusion pressure (SCPP) is critical to the success of open and endovascular repair of DTAs and TAAAs to prevent spinal cord ischemia when blood flow to the segmental arteries (SAs) is interrupted.

Monitoring of spinal cord function using motor (MEP) or somatosensory evoked potentials (SSEP) is widely accepted in the assessment of intraoperative spinal cord viability during aortic procedures, but is an indirect measurement of the adequacy of spinal cord perfusion [1–6]. If MEPs or SSEPs diminish, the response usually involves anesthetic and hemodynamic maneuvers to improve spinal cord perfusion—chiefly by increasing mean arterial pressure (MAP) and improving cerebrospinal fluid (CSF) drainage—but the assessment of the efficacy of these measures is likewise indirect. It is possible that inadequate spinal cord perfusion may occur even when MEP and SSEP monitoring shows no cause for alarm, and that a more direct, sensitive way of monitoring spinal cord perfusion could be helpful intraoperatively, although the presence of intact MEP and SSEP already provides considerable reassurance of adequate intraoperative spinal cord perfusion.

A recent retrospective study of our clinical cases has suggested, however, that spinal cord vulnerability to inadequate perfusion is likely to be highest not during operation, but in the early postoperative period, and that inadequate perfusion resulting in spinal cord injury may occur with systemic pressures below the individual patient's usual blood pressure even though those systemic pressures fall within limits usually regarded as normal

Accepted for publication Feb 24, 2009.

Presented at the Fifty-fifth Annual Meeting of the Southern Thoracic Surgical Association, Austin, TX, Nov 5–8, 2008.

Address correspondence to Dr Etz, Department of Cardiothoracic Surgery, Mount Sinai School of Medicine, One Gustave L. Levy Place, New York, NY 10029; e-mail: christian.etz@mountsinai.org.

Published by Elsevier Inc

0003-4975/09/$36.00
doi:10.1016/j.athoracsur.2009.02.101

SCPP-CATH PLACEMENT

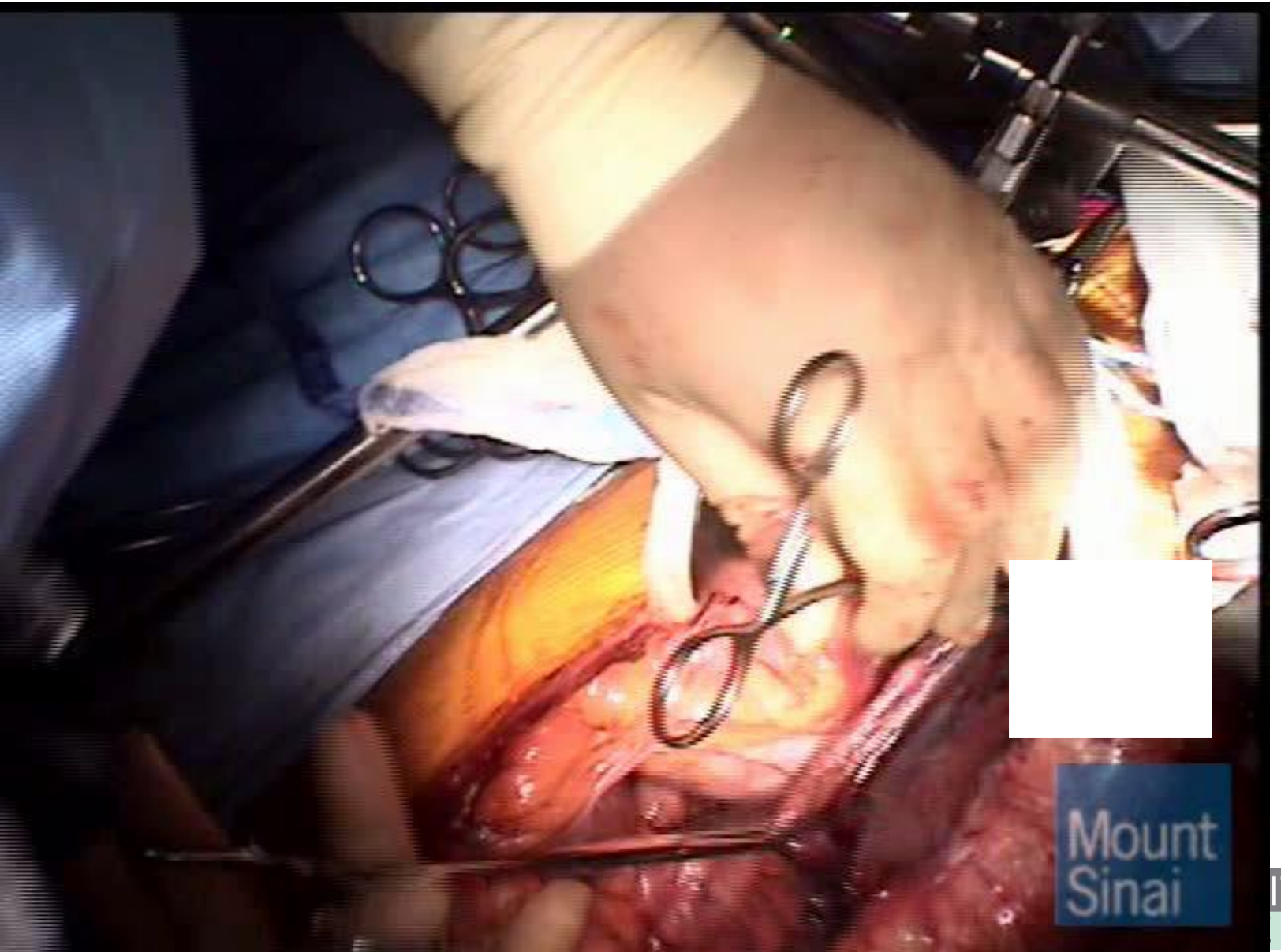

ITÄT LEIPZIG
ENTRUM

SCPP = CN pressure – CSF pressure

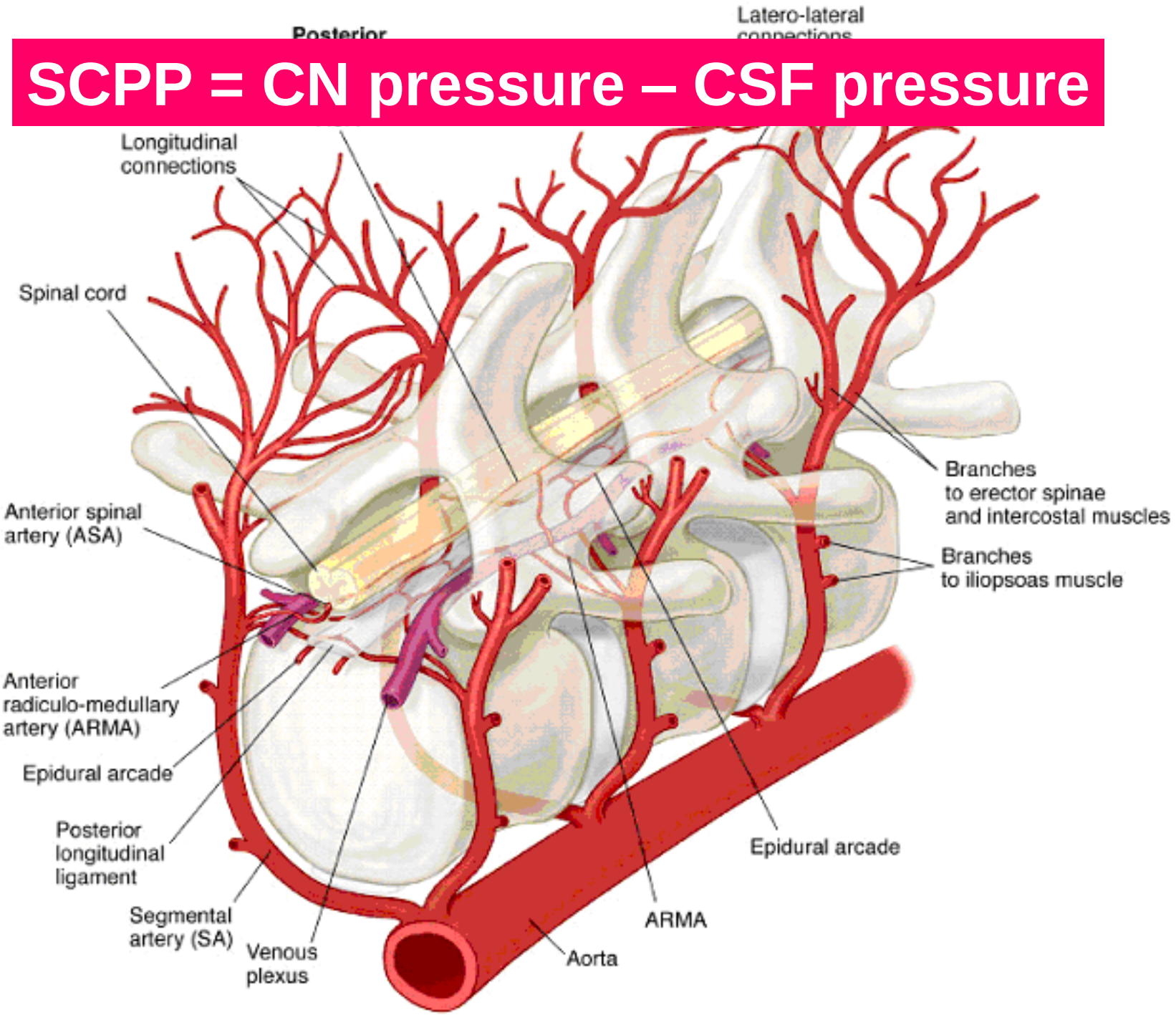

SCPP = CN pressure – CSF pressure

Five patients 9 ± 3 SA sacrificed

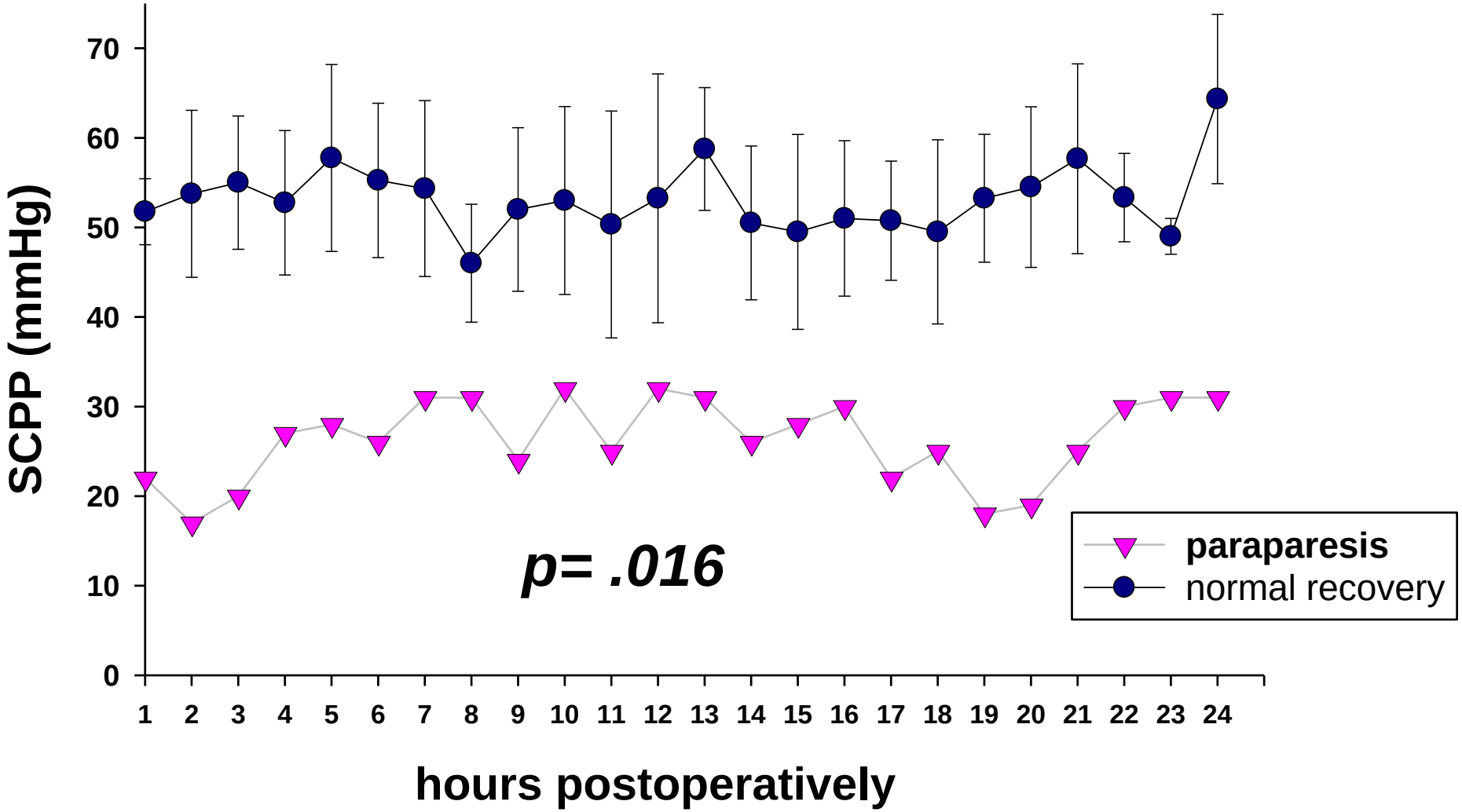

UNIVERSITÄT LEIPZIG
HERZZENTRUM

CN NIRS

Detection of ischemic spinal cord injury during and after extensive open or endovascular TAA/A repair utilizing SSEP and/or MEP monitoring: invasive and expensive

Spinal cord monitoring

Modality						
SSEP	-	-	-	+	-	-
MEP	-	-	-	+	+	-
Direct SCPP	-	+	+	+	+	-
Laser Doppler	-	+	+	+	+	-
cnNIRS	+	+	+	+	+	+

SSEP= Somatosensory evoked potentials; MEP=Motor evoked potentials
SCPP=Spinal cord perfusion pressure; cnNIRS=near-infrared spectroscopy of the collateral network

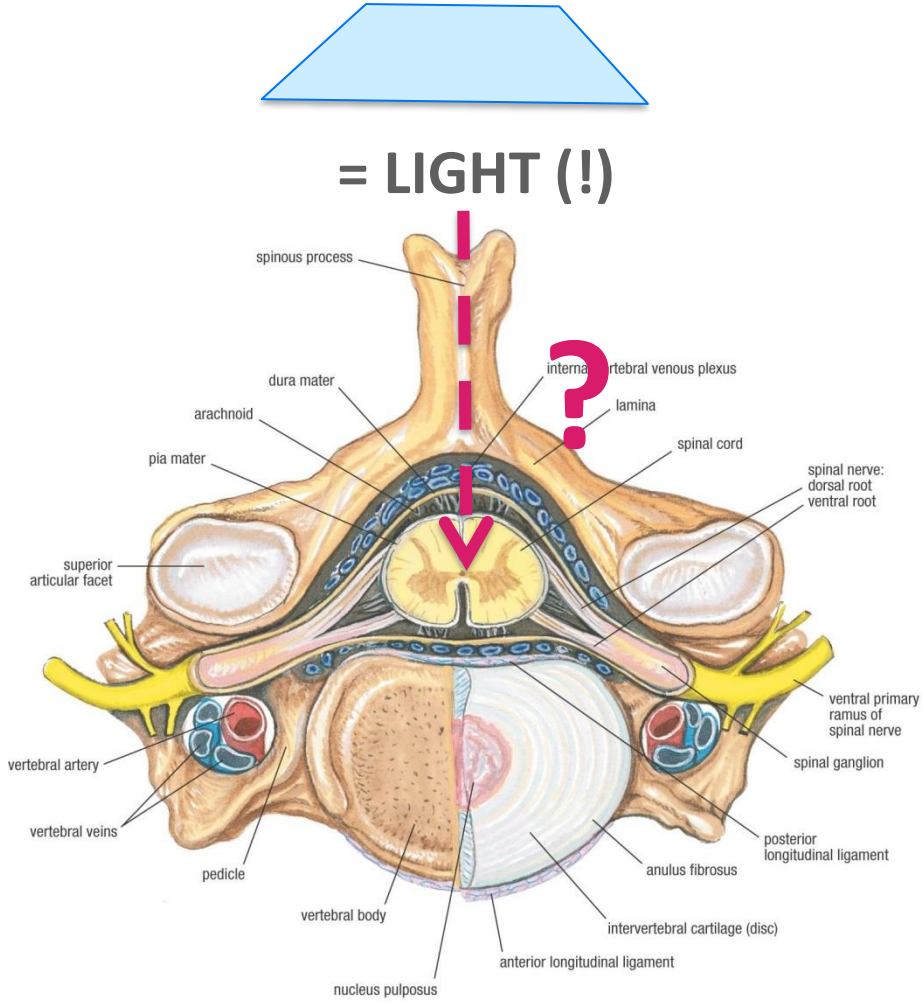
= LIGHT (!)
spinous process
dura mater
arachnoid
pia mater
superior articular facet
vertebral artery
vertebral veins
pedicle
vertebral body
nucleus pulposus
lamina
spinal cord
spinal nerve: dorsal root ventral root
ventral primary ramus of spinal nerve
spinal ganglion
posterior longitudinal ligament
anulus fibrosus
intervertebral cartilage (disc)
anterior longitudinal ligament

Collateral Network

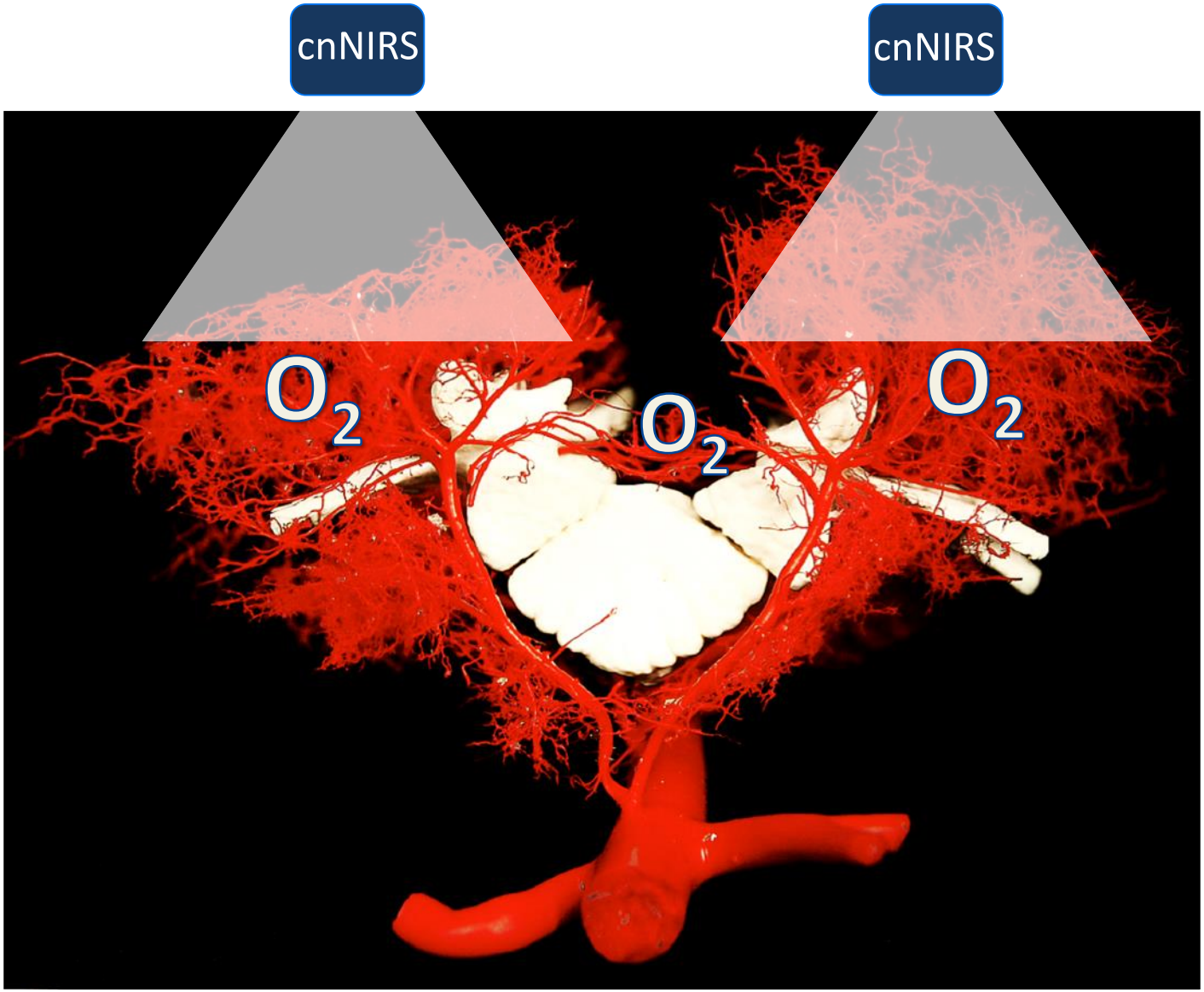

Image from J Thorac Cardiovasc Surg. 2011, The Collateral Network Concept: A Reassessment of the Anatomy of Spinal Cord Perfusion

FIRST IN-MAN SERIES

Near-infrared Spectroscopy Monitoring of the Collateral Network Prior to, During, and After Thoracoabdominal Aortic Repair: A Pilot Study

C.D. Etz [a,b,*,d], K. von Aspern [a,d], S. Gudehus [c], M. Luehr [a], F.F. Girrbach [a], J. Ender [c], M. Borger [a], F.W. Mohr [a]

[a] Department of Cardiac Surgery, University of Leipzig, Heart Center Leipzig, Saxony, Germany
[b] Department of Cardiothoracic Surgery, Mount Sinai School of Medicine, New York, NY, USA
[c] Department of Anesthesiology, University of Leipzig, Heart Center Leipzig, Saxony, Germany

① **Lumbar cnNIRS** sensitive to X-clamping & distal perfusion

① **Diminished** lumbar **cnNIRS** = postoperative **SCI***

Eur J Vasc Endovasc Surg. 2013; * comparing patients with and without postoperative spinal cord injury

HYPOTHESIS

Perfusion & oxygenation of the **collateral network** directly **reflects spinal cord** microcirculation?

Can **cnNIRS depict spinal cord oxygenation?**

Experimental setup

- ✧ Sev
- ✧ Sub
  T5/6
- ✧ Dire
  oxyg

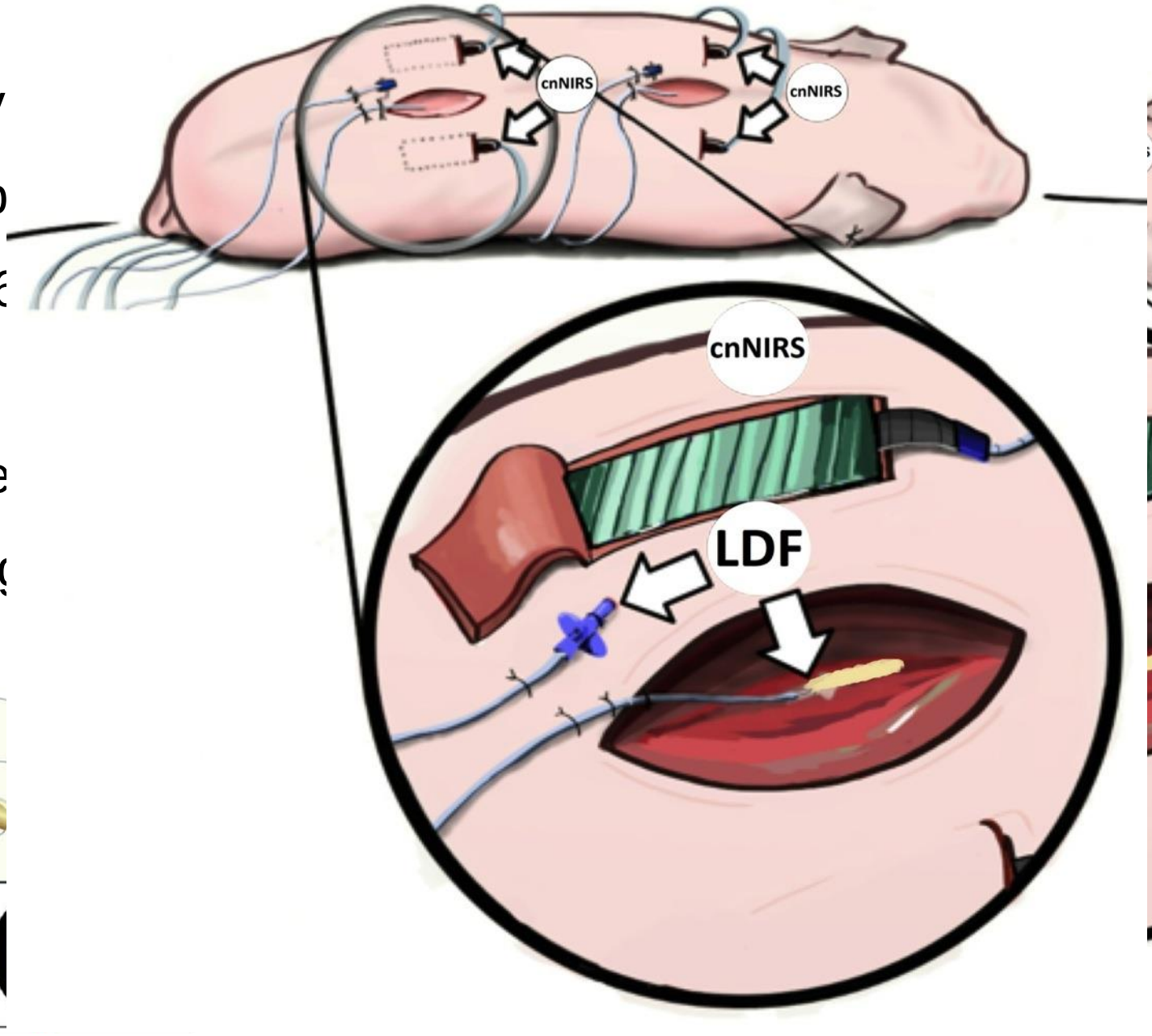

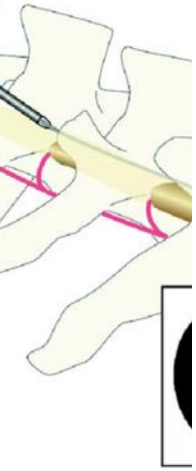

Experimental Sequence

- ✧ **Baseline**
- ✧ **X-clamping** (ischemia: 8 min.)
- ✧ **Clamp release** (recovery)

} consecutively 4 times

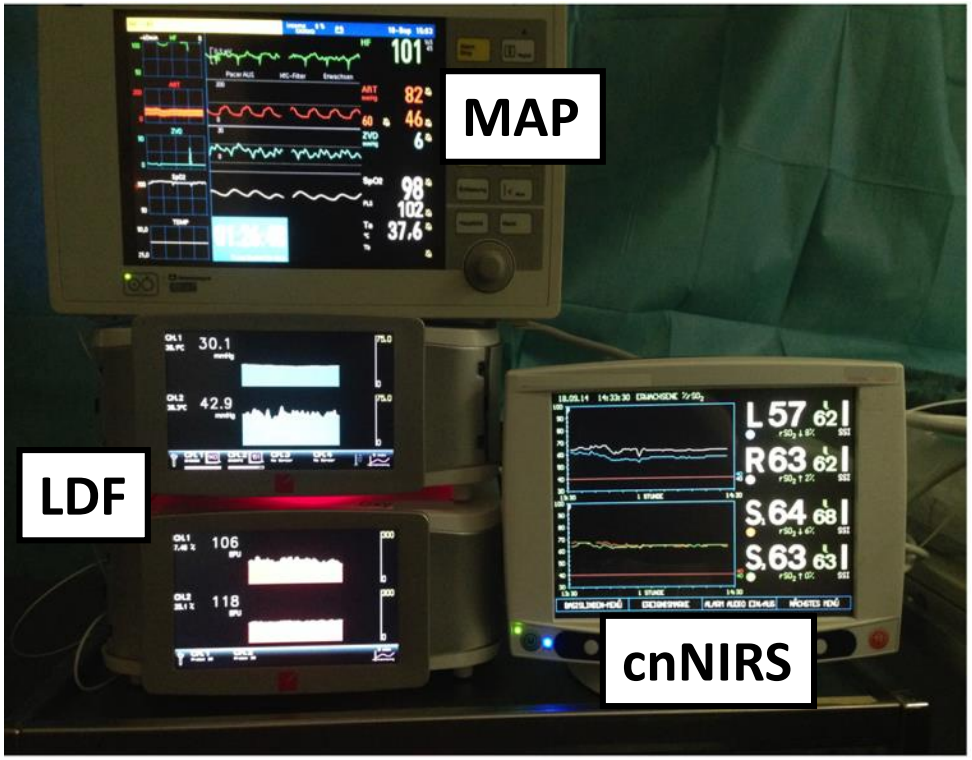

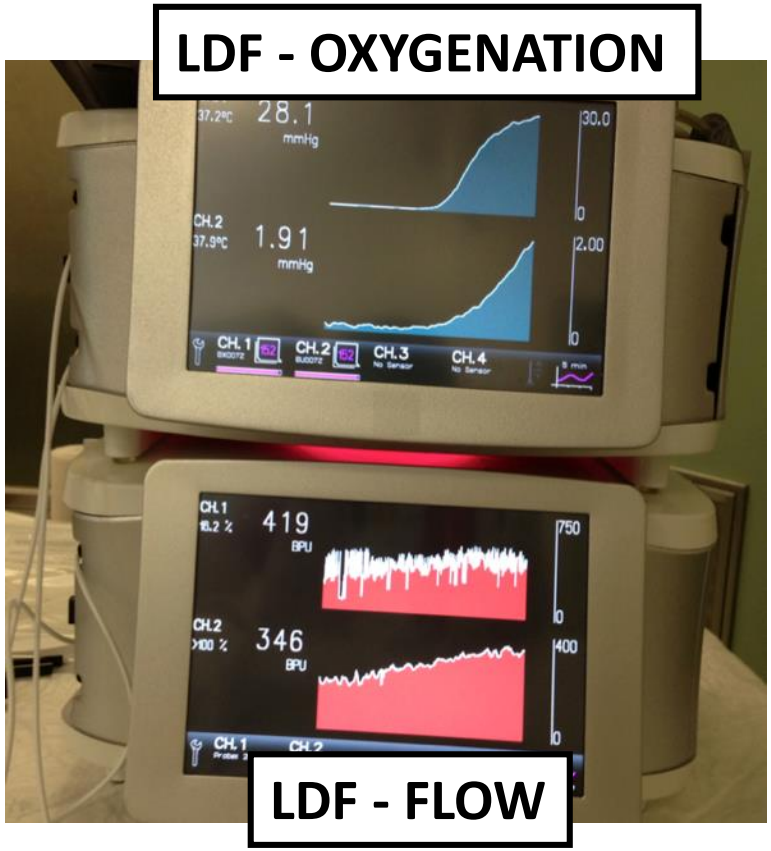

Direct Invasive Laser Doppler (LDF)

Collateral Network

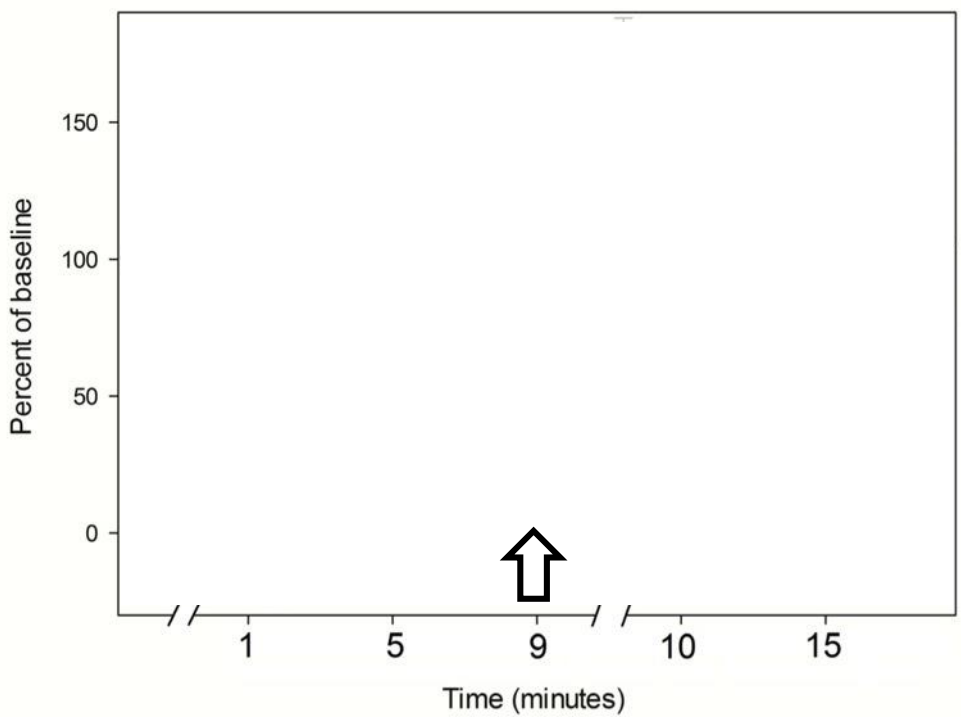

Spinal Cord

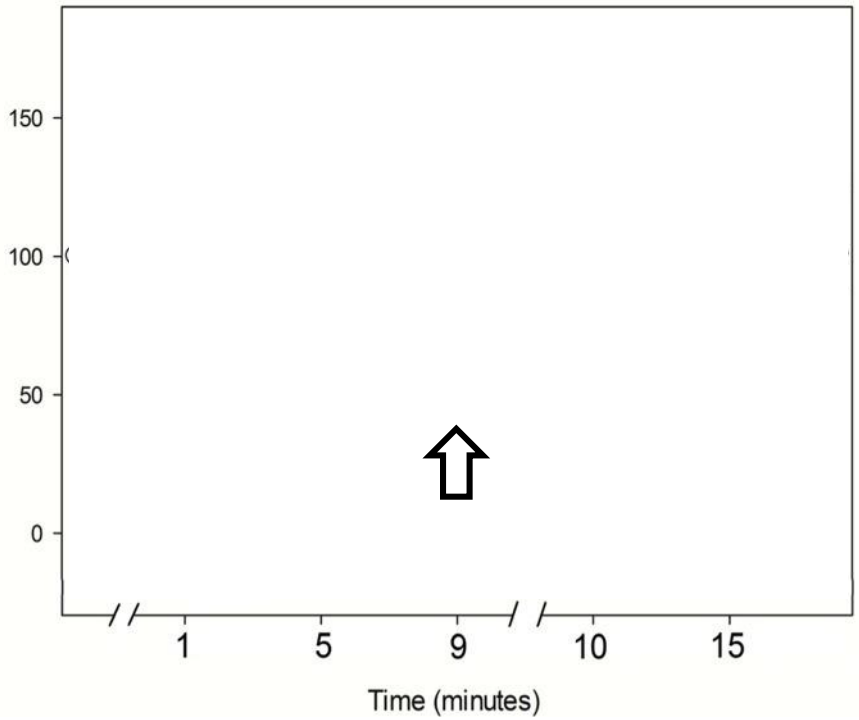

Oxygenation

Flo
w

X-clamp

Clamp release

Direct Invasive Laser Doppler (LDF)

Collateral Network

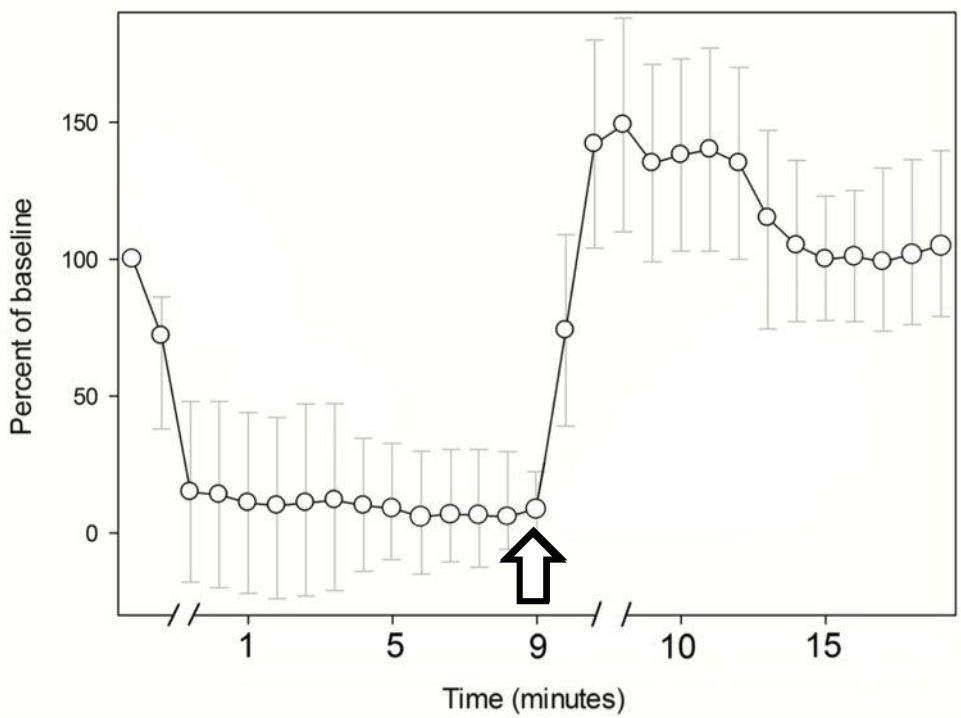

Spinal Cord

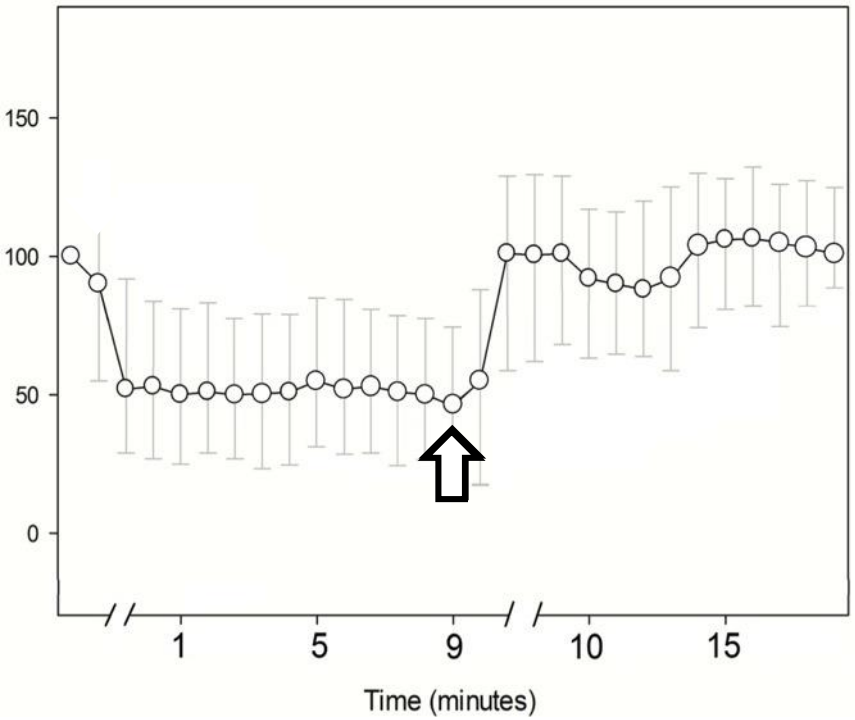

Oxygenation

Flow

X-clamp

Clamp release

HYPOTHESIS: oxygenation of the **CN = spinal cord**? ☑

Collateral Network vs. Spinal Cord

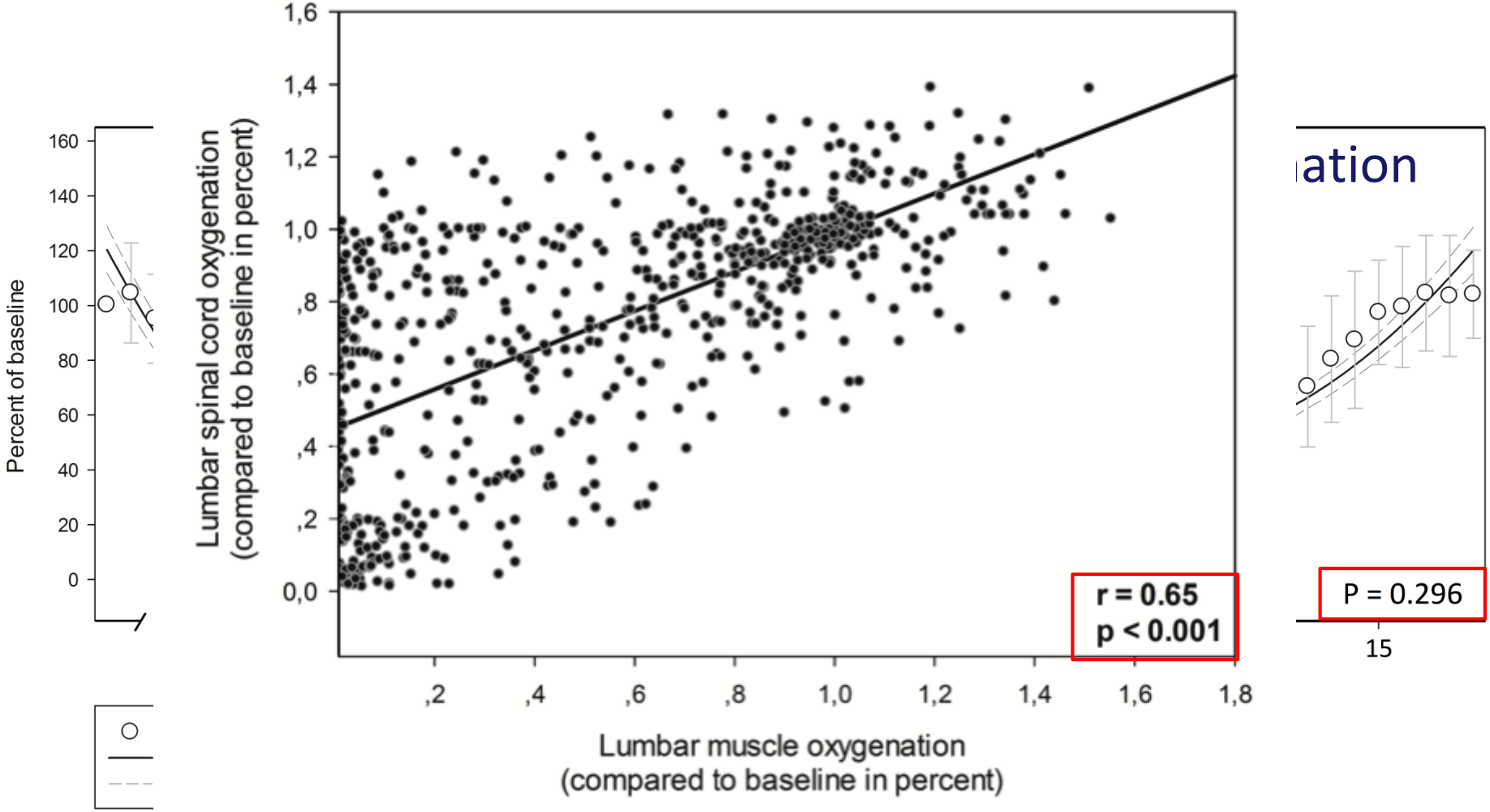

Paraspinous **CN** oxygenation directly reflects **spinal cord** tissue oxygenation

Non-invasive cnNIRS

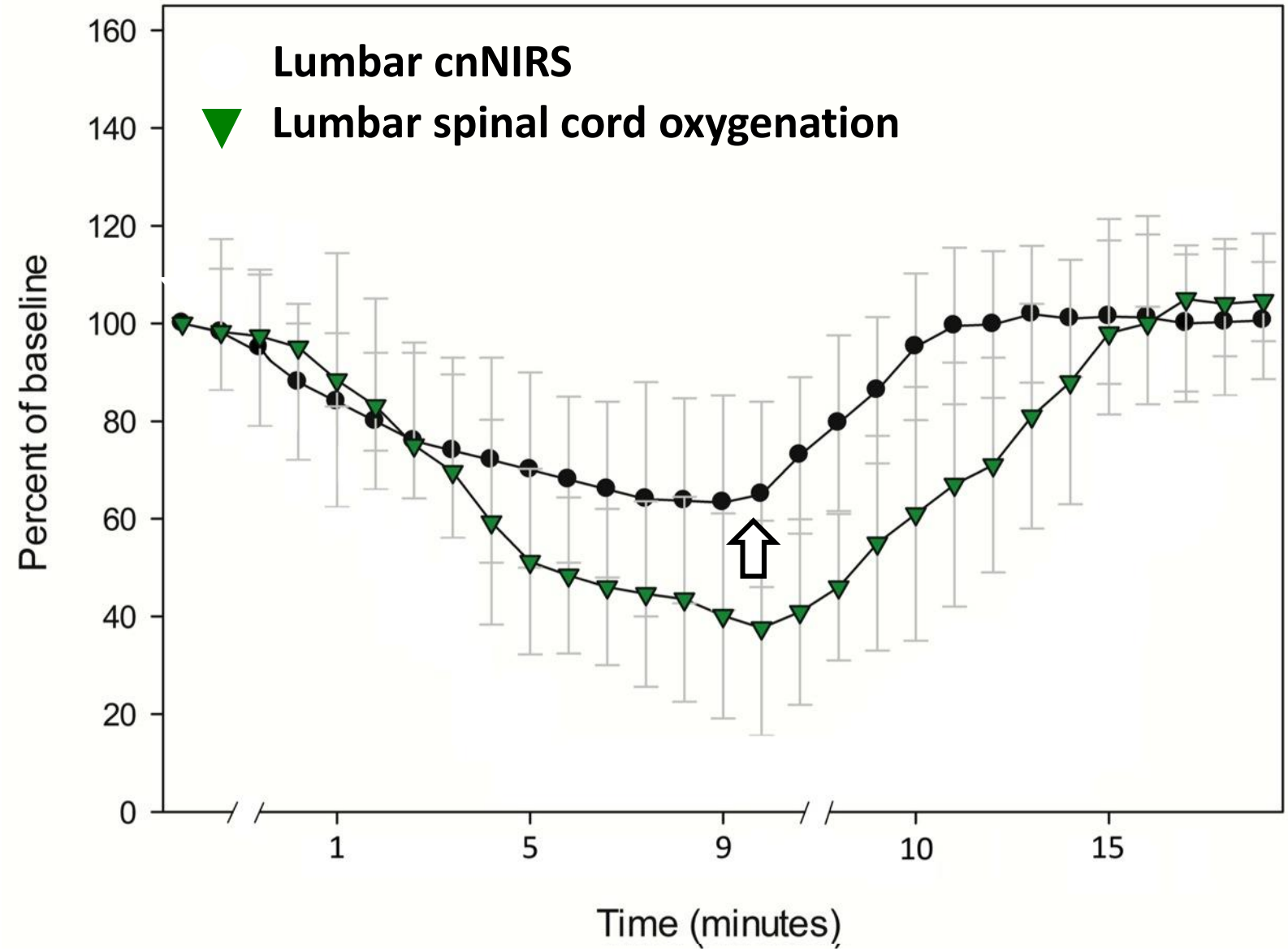

Question: lumbar **cnNIRS** = **Spinal cord** oxygenation? ☑

cnNIRS vs. Spinal Cord Oxygenation

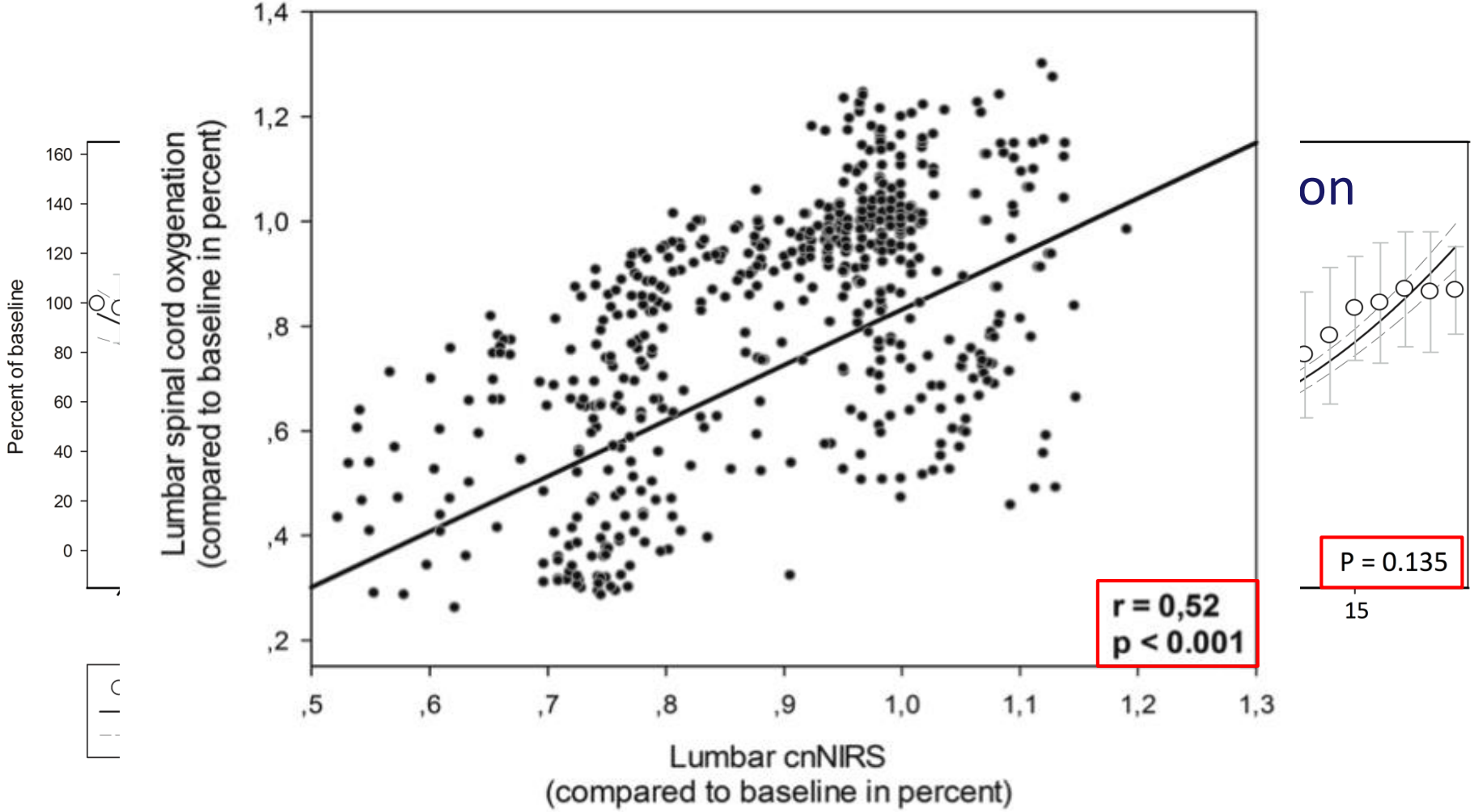

lumbar **cnNIRS** directly reflects **spinal cord** tissue oxygenation

Conclusions

① **CN** oxygenation reflects **spinal cord** oxygenation

① **Lumbar cnNIRS** reflects **spinal cord** oxygenation

Lumbar cnNIRS is an effective tool to non-invasively monitor spinal cord oxygenation

BP MANAGEMENT

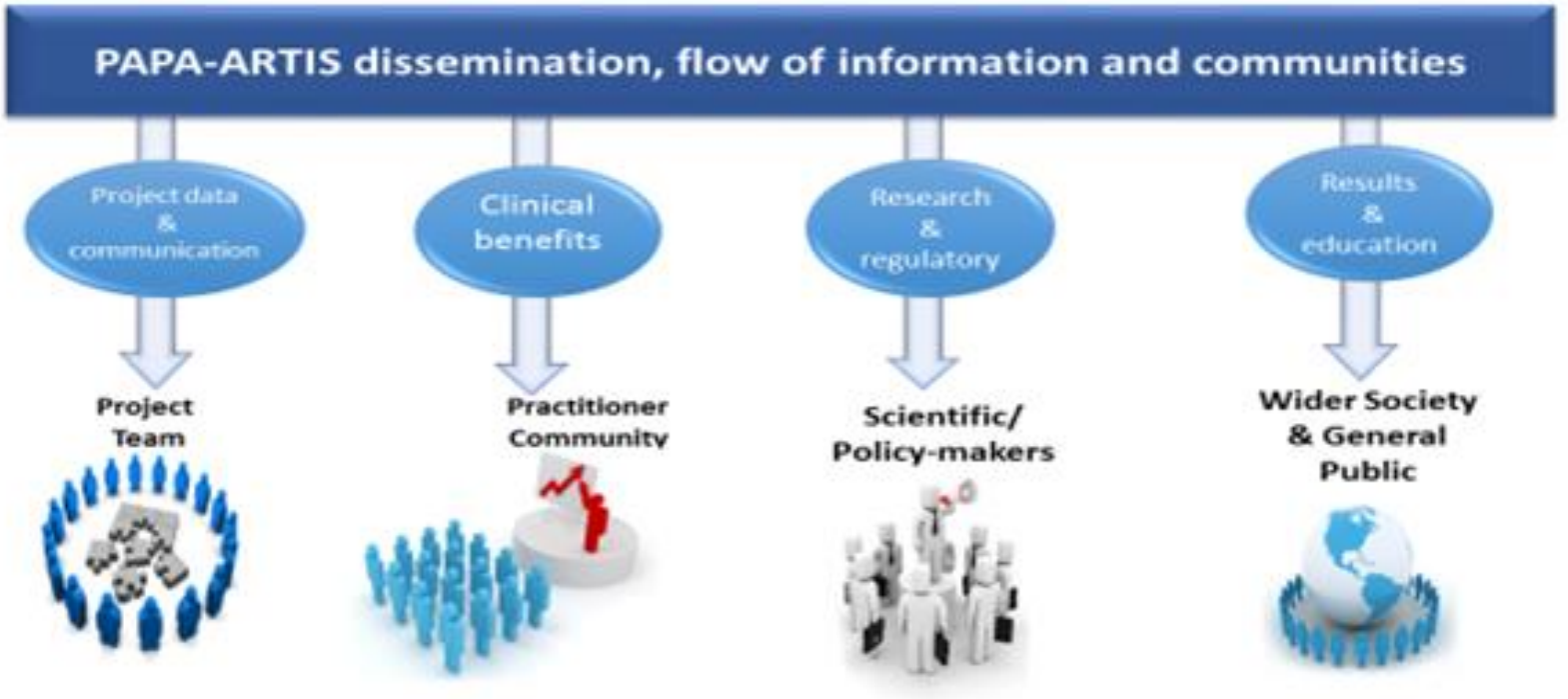

UNIVERSITÄT LEIPZIG
HERZZENTRUM

Ultimate goal: Translation of the ‚staged repair' concept

into ***clinical practice*** *for* ***ZERO PARAPLEGIA***