University Heart Center Hamburg

GERMAN AORTIC CENTER HAMBURG

Chronic Aortic Dissection:

How To Deal With The False Lumen

Tilo Kölbel, Sebastian Debus, Fiona Rohlffs, Nikos Tsilimparis

German Aortic Center, Hamburg
University Heart Center
University Hospital Eppendorf

AORTIC LIVE 2016
October 17–18, 2016
Philharmonie Essen, Germany

Disclosures

* Research-grants, travelling, proctoring speaking-fees, IP with Cook.
* Consulting with Philips

FL-Aneurysm in Chronic AD

Long-Term Predictors of Descending Aorta Aneurysm Change in Patients With Aort

Jong-Min Song, MD, PHD,* Sung-Doo Kim, M

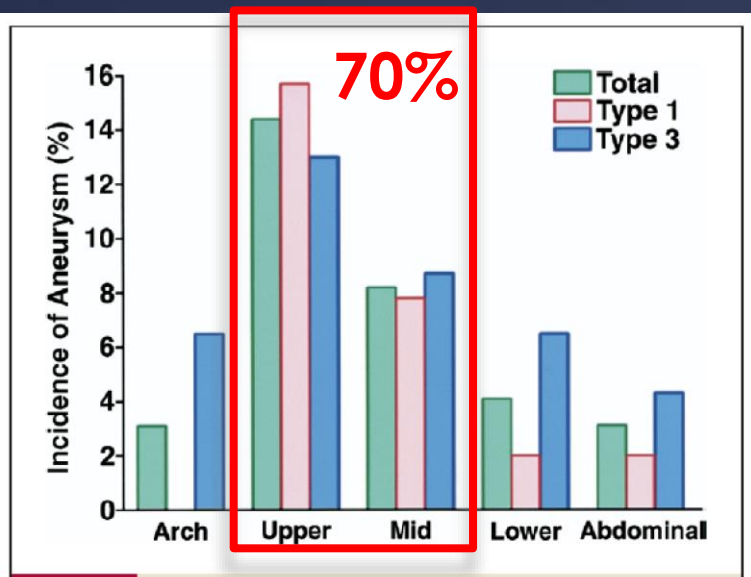

Figure 1 Incidence of Distal Aorta Aneurysm

Incidences of aneurysm at the aortic arch; upper, mid, and lower descending thoracic aorta; and abdominal aorta in patients with type 1 and type 3 aortic dissection.

Song et al. 2007; JACC 50:799-804

Open Surgery for CTBAD

Systematic Review

Open surgical repair for chronic type B aortic dissection: a systematic review

David H. Tian[1], Ramesh P. De Silva[1], Tom Wang[1], Tristan D. Yan[1,2]

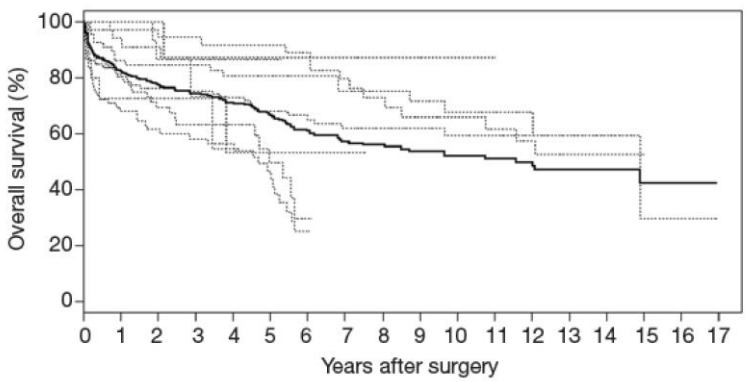

Figure 1 Overall survival based on reconstructed individual patient data. Data of 458 patients from seven studies were reconstructed and presented. Dotted lines represents Kaplan-Meier curves of individual studies, while the solid line represents aggregate reconstructed survival data of the entire cohort.

19 studies, n=970, 58y mean age

- 30d mortality: 11%
- Stroke: 6%, SCI: 5%, CNI: 8%
- 3/10y survival: 74/50%
- Conclusion:
  „poorer compared to TEVAR“

Tian et al. 2014; Ann Cardiothorac Surg 3:340-50

TEVAR in Chronic Type B

Efficacy of thoracic endovascular stent repair for chronic type B aortic dissection with aneurysmal degeneration

Salvatore T. Scali, MD,[a] Robert J. Feezor, MD,[a] Catherine K. Chang, MD,[a] David H. Stone, MD,[c] Philip J. Hess, MD,[b] Tomas D. Martin, MD,[b] Thomas S. Huber, MD, PhD,[a] and Adam W. Beck, MD,[a]
Gainesville, Fla; and Lebanon, NH

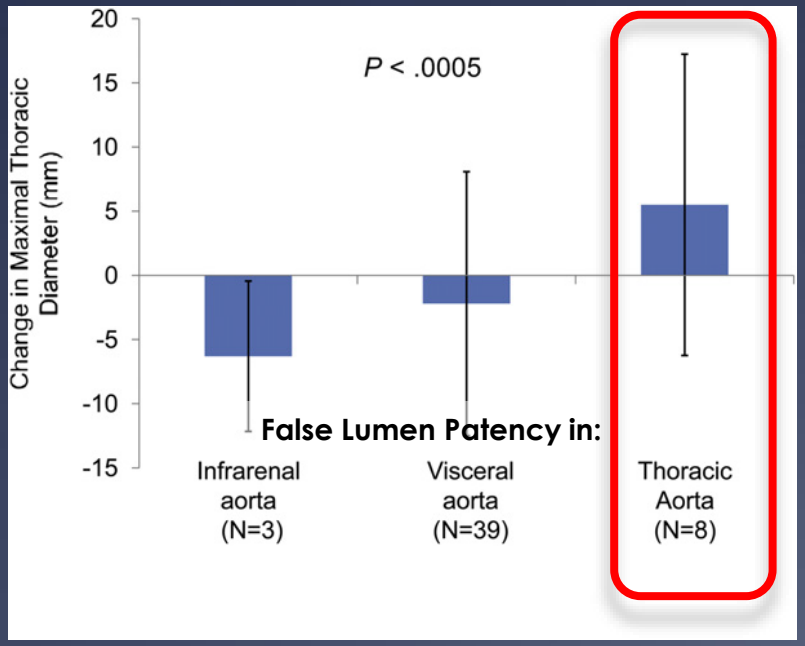

- 2004-2011
- n=80, 26 months FU
- TEVAR for type B and residual AD
- LSA-coverage 75%, 24% debranching
- Median 16 (1-74) months.
- 35% FL-expansion during FU (!)

Scali et al. 2013; J Vasc Surg. 58:10-7

TEVAR in Chronic Type B

Predictors of Outcome after Endovascular Repair for Chronic Type B Dissection

K. Mani [a,d,*], R.E. Clough [a,b], O.T.A. Lyons [a,c], R.E. Bell [a], T.W. Carrell [a,b], H.A. Zayed [a], M. Waltham [a,c], P.R. Taylor [a,b]

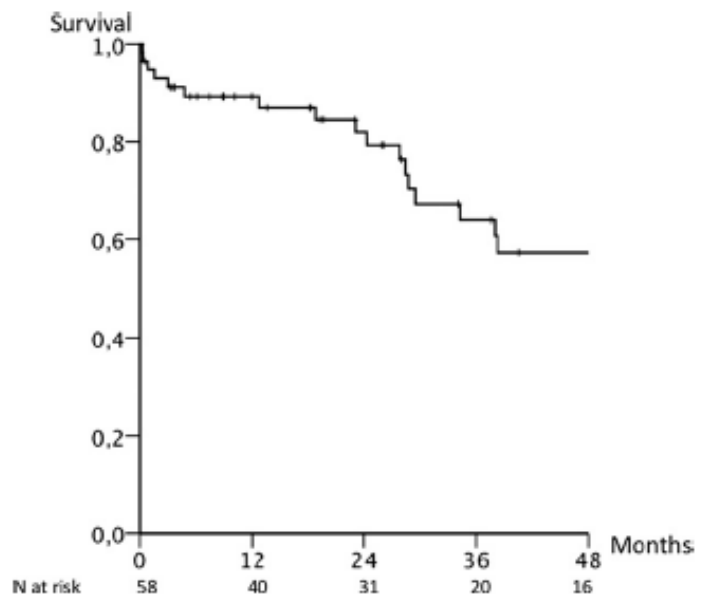

Figure 2. Kaplan–Meier analysis of survival after endovascular intervention for chronic type B dissection.

- 2000-2010
- N=58, 38 months FU
- TEVAR for chronic type B (>14days)
- Perioperative mortality 5.2%
- 3 year mortality 36%

Mani et al. 2012; Eur J Vasc Endovasc Surg 43: 386-91

TEVAR in Chronic Type B

Predictors of Outcome after Endovascular Repair for Chronic Type B Dissection

K. Mani [a,d,*], R.E. Clough [a,b], O.T.A. Lyons [a,c], R.E. Bell [a], T.W. Carrell [a,b], H.A. Zayed [a], M. Waltham [a,c], P.R. Taylor [a,b]

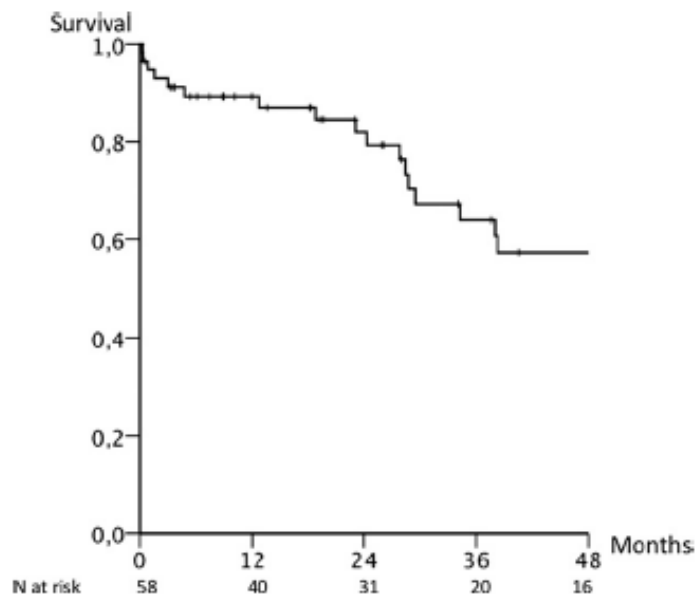

Figure 2. Kaplan–Meier analysis of survival after endovascular intervention for chronic type B dissection.

Cox regression analysis of factors related to mortality in patients with mid-term followup.

Parameters	Odds ratio	*P*-value	95% CI	
Age, per year	1.08	0.04	1.00	1.17
Female vs male	0.01	0.03	0.00	0.64
Urgent vs elective	0.59	0.60	0.08	4.33
Maximal aortic diameter pre-intervention, per cm	0.92	0.82	0.43	1.95
Increase in aortic size, per cm	2.70	0.01	1.23	5.96

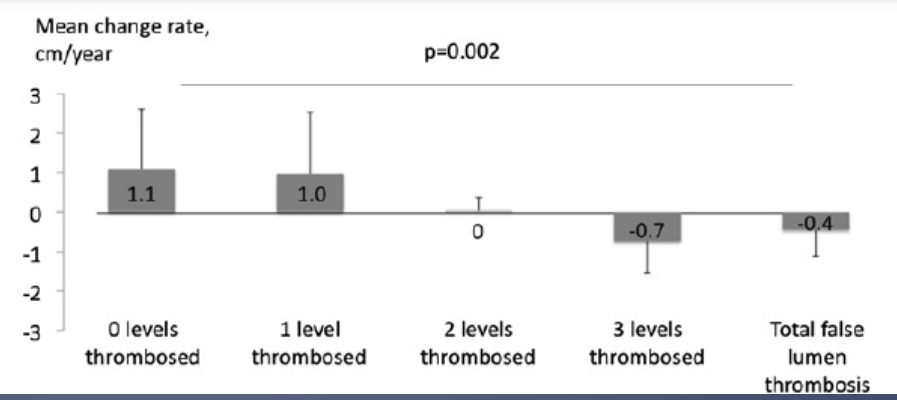

Mani et al. 2012; Eur J Vasc Endovasc Surg 43: 386-91

TEVAR in Chronic Type B

Predictors of Outcome after Endovascular Repair for Chronic Type B Dissection

K. Mani [a,d,*], R.E. Clough [a,b], O.T.A. Lyons [a,c], R.E. Bell [a], T.W. Carrell [a,b], H.A. Zayed [a], M. Waltham [a,c], P.R. Taylor [a,b]

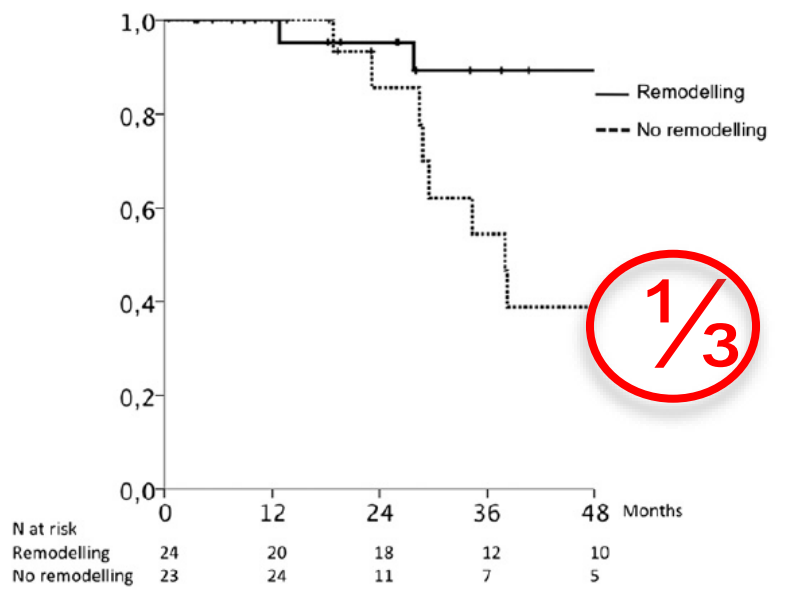

Figure 5. Kaplan–Meier analysis of survival based on remodelling of the aorta after endovascular intervention for chronic type B dissection.

False Lumen Perfusion

↓

No Aortic Remodelling

↓

Death

Mani et al. 2012; Eur J Vasc Endovasc Surg 43: 386-91

Failure to Remodel in Chronic Dissection

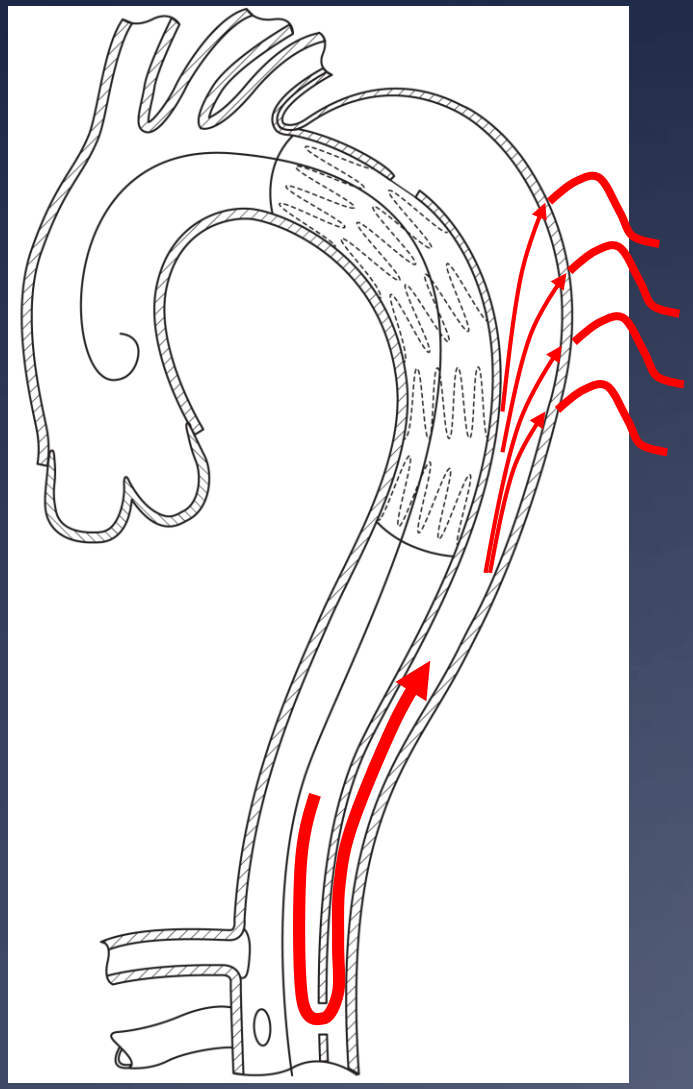

- Perfusion and pressure unchanged in false lumen
- Presence of Intercostals originating from false lumen
- False lumen back flow to Intercostals
- FL-TAA in 1/3 of TEVAR-patients!

Open Fenestration

Distal Landing Zone Open Fenestration Facilitates Endovascular Elephant Trunk Completion and False Lumen Thrombosis

Eric E. Roselli, MD, Edgardo Sepulveda, MD, Akshat C. Pujara, BA, Jahanzaib Idrees, BS, and Edward Nowicki, MD

Department of Thoracic and Cardiovascular Surgery, Heart and Vascular Institute, Cleveland Clinic, Cleveland, Ohio

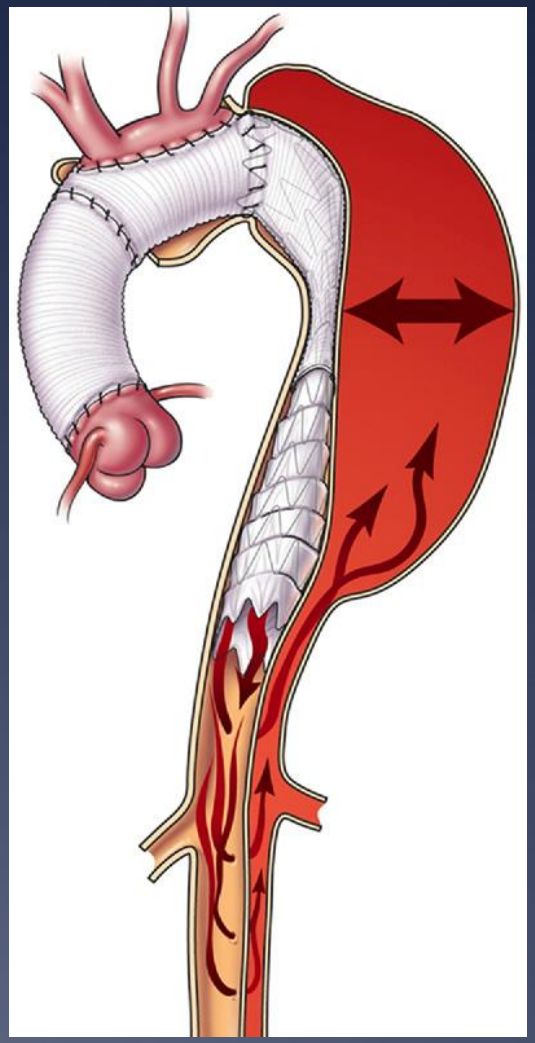

- 2007-2011; n=24
- Open first stage elefant trunc + fenestration of descending aorta
- Endovascular second stage completion
- Survival 92% @ 2years

Roselli et al. 2011, Ann Thorac Surg 92: 2078-84

Open Fenestration

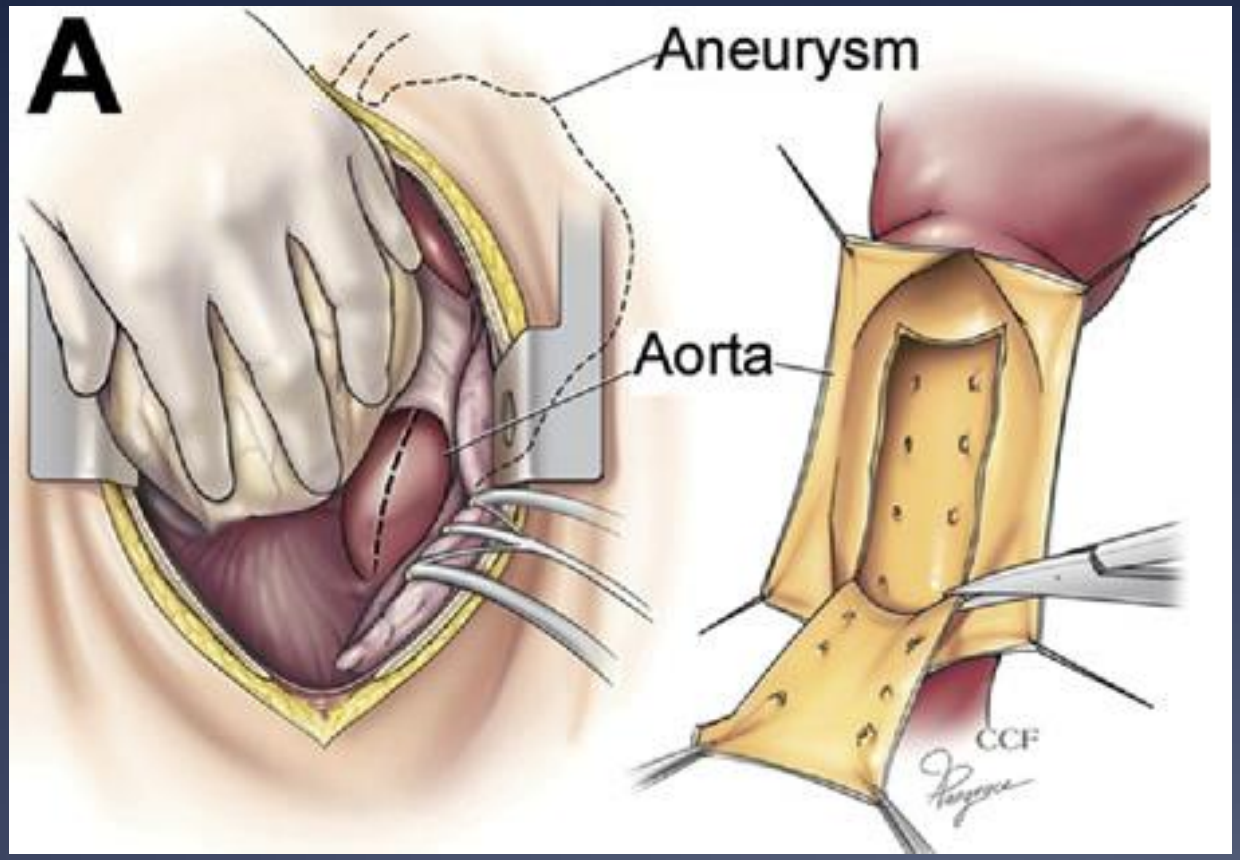

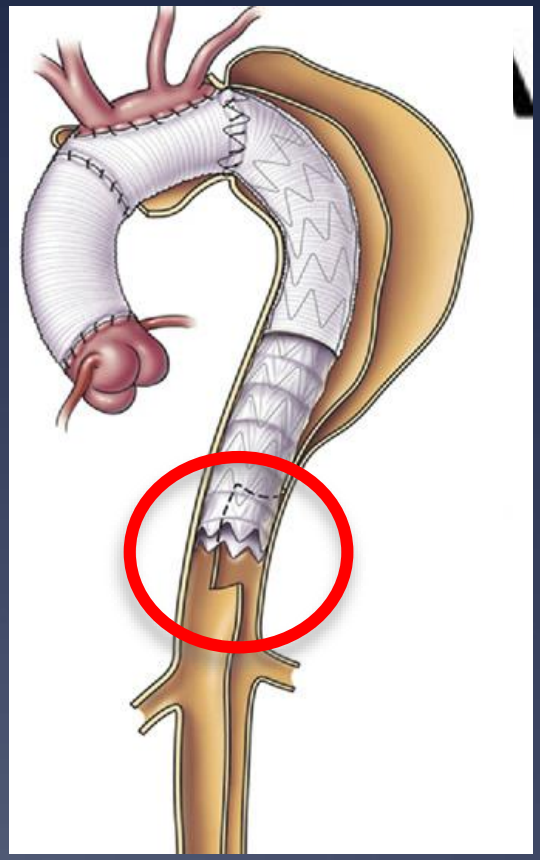

Roselli et al. 2011, Ann Thorac Surg 92: 2078-84

Direct False Lumen Occlusion

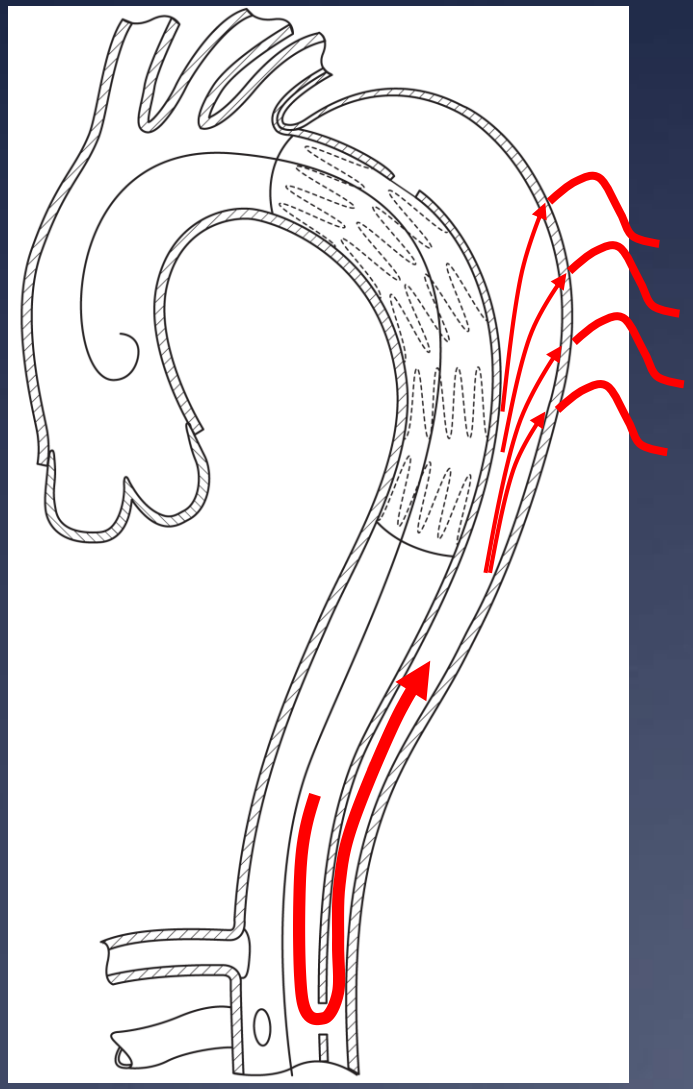

Direct False Lumen Occlusion

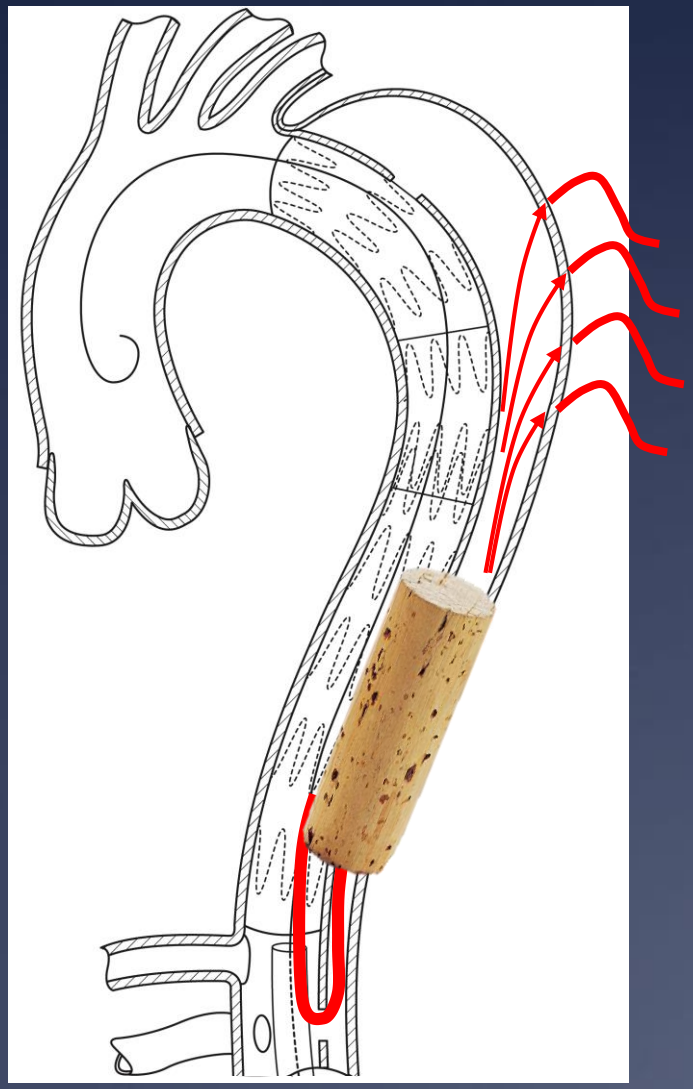

- TEVAR-extension to CA
- Embolisation or Knickerbocker
- Seperates aortic FL-compartments!
- Does not restrict further distal techniques like fenestrated EVAR

Filters, Balloons, Thrombin

How to Exclude the Dilated False Lumen in Patients After a Type B Aortic Dissection? The Cork in the Bottleneck

Maartje C. Loubert, MD[1]; Victor P.M. van der Hulst, MD, PhD[3]; Cees De Vries, MD[3]; Kees Bloemendaal, MD[2]; and Anco C. Vahl, MD, PhD[1]

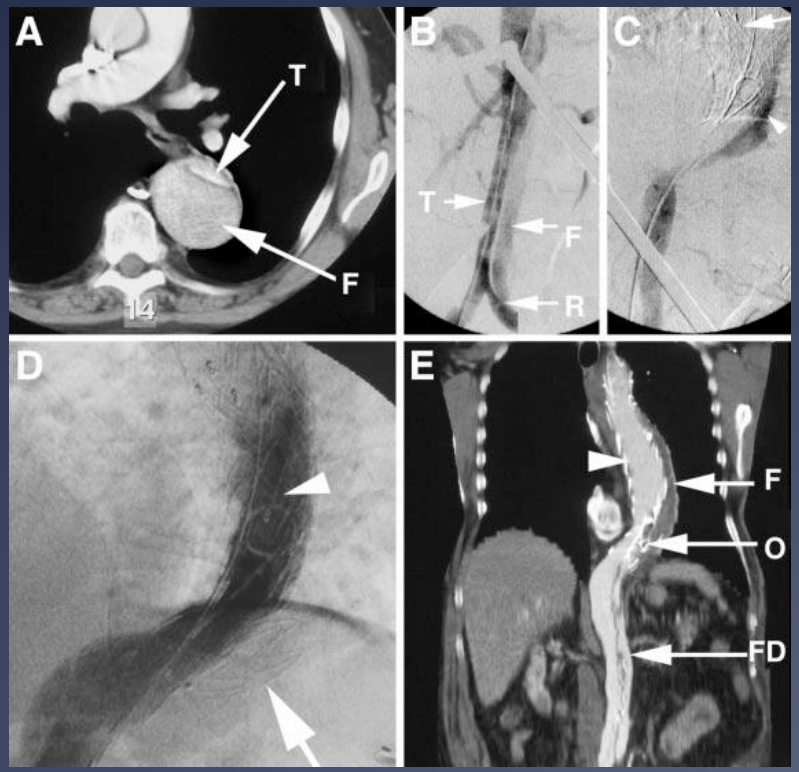

- 2 Cases

1. FL-TAA-occlusion with:
   - 2 Greenfield filters
   - 6 detachable balloons
   - 5ml thrombin
2. FL-TAA-occlusion with:
   - 24mm Talent occluder

Loubert et al. 2003; J Endovasc Ther 10: 244-8

Coils, Plugs, Glue

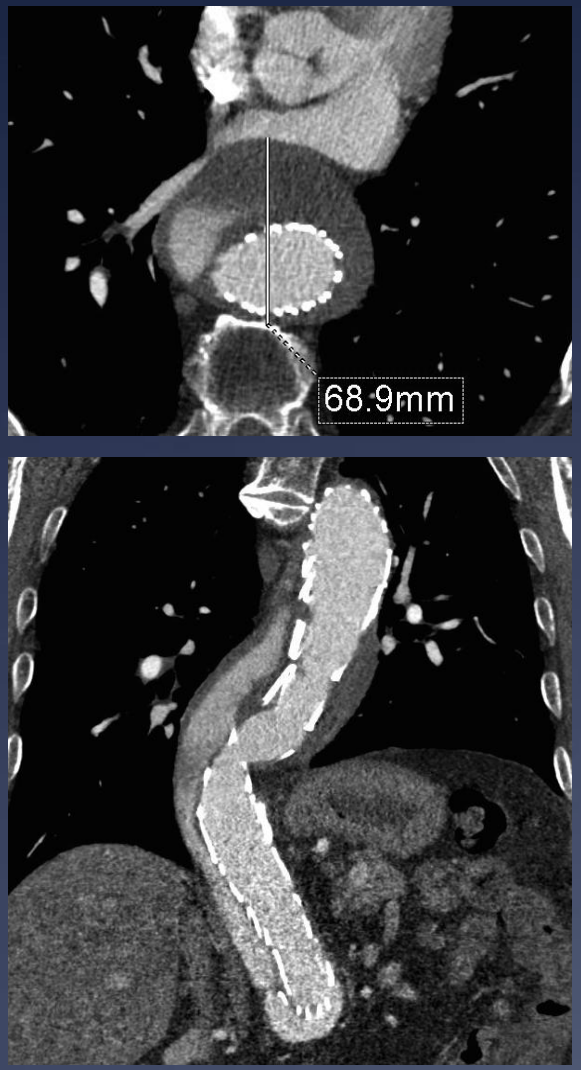

Preop. CT

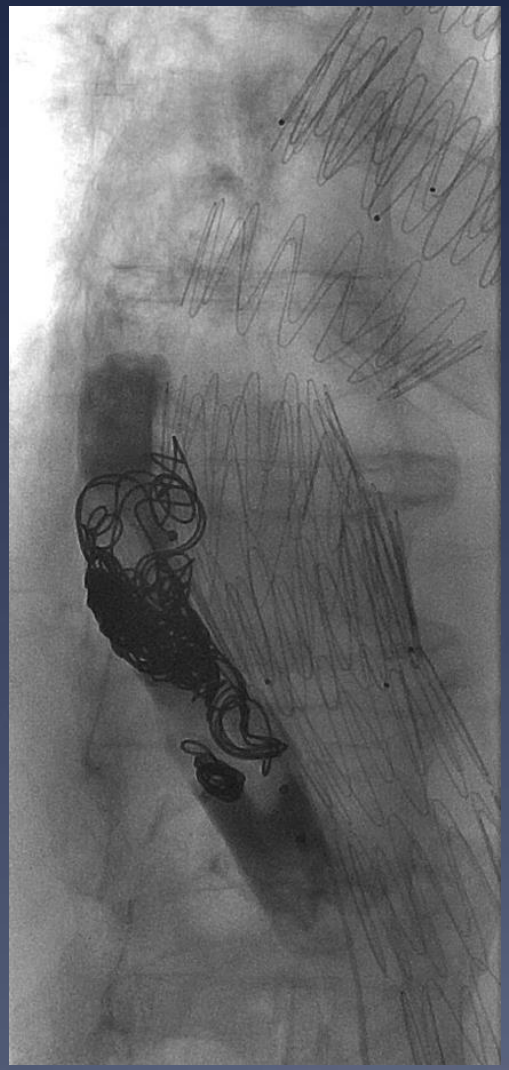

Intervention

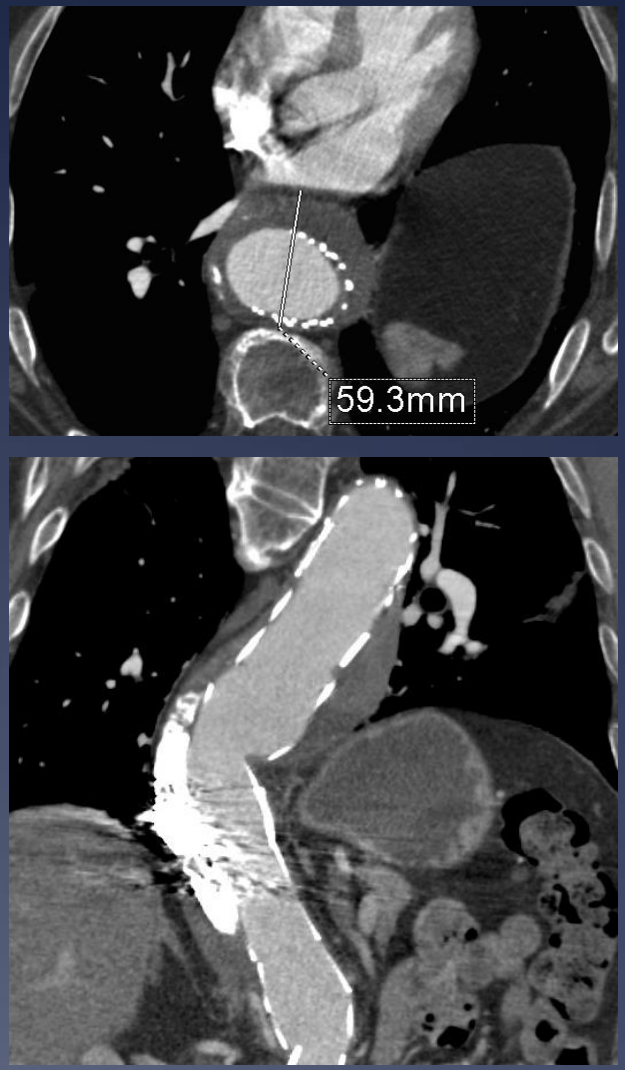

Postop. CT

Iliac Occluder

Outcomes after false lumen embolization with covered stent devices in chronic dis

Jahanzaib Idrees, MD, Eric E. Roselli, MD, Susan Shafii
Bruce W. Lytle, MD, *Cleveland, Ohio*

Maximum Diameter: 24mm!

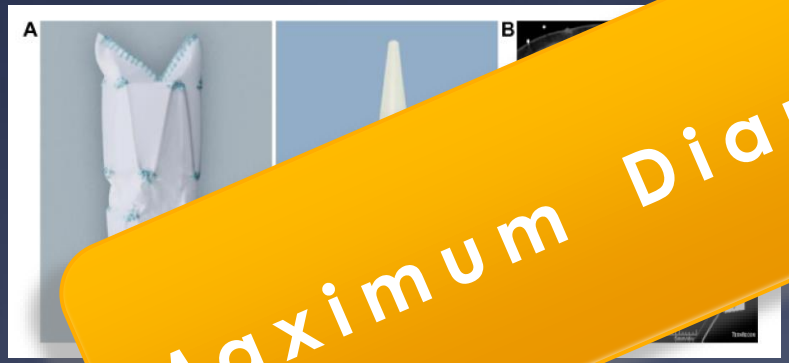

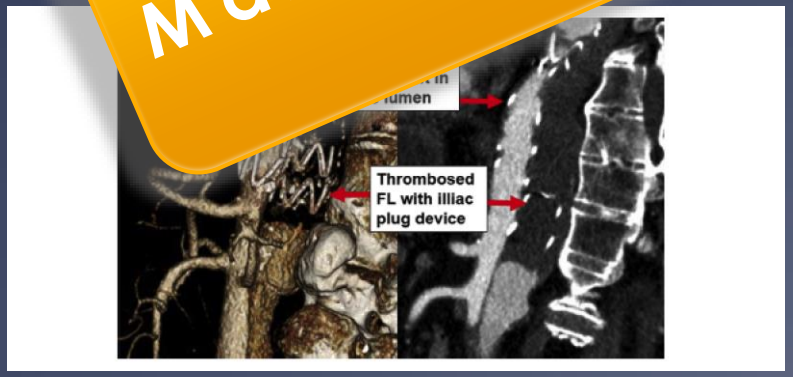

	Outcome[a] *(N = 21)*
30-day mortality	1 (4.7)
Follow-up, median months	26 (2-42)
Aortic rupture	0
Complete thrombosis after index embolization	15 (71)
Partial thrombosis	6 (29)
Endovascular reintervention (re-embolization)	4 (19)
Complete thrombosis after further embolization	19 (90)
Failure of thrombosis	0
Reduction in postoperative max descending diameter	13 (62)
Shrinkage, median mm	4.6 (0.2-27)

Idrees et al. 2014; J Vasc Surg 60:1507-13

Candy-Plug

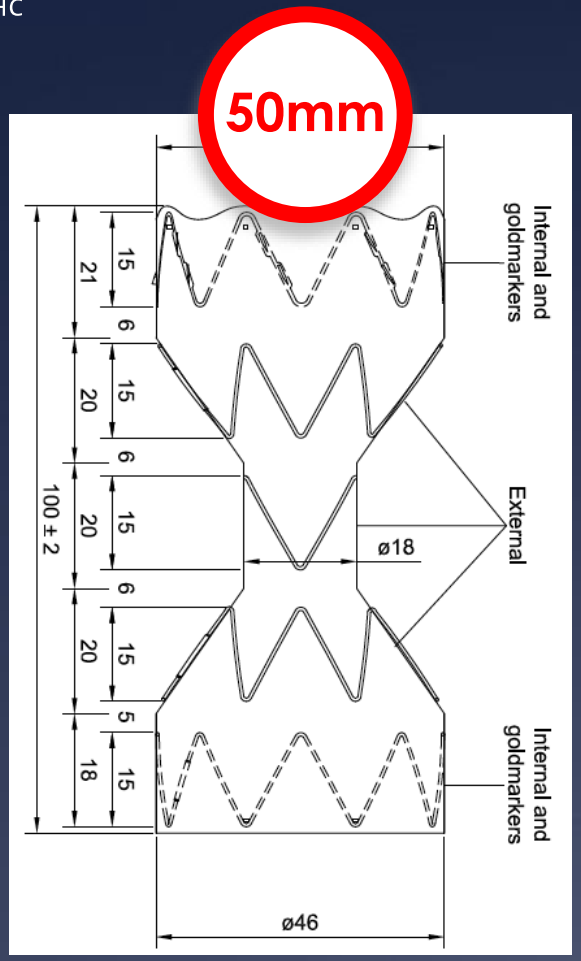



22mm Amplatzer plug II

22mm ZIP iliac-occluder

Kölbel et al. 2013; J Endovasc Ther 20: 484-9

Candy-Plug

October 2013 January 2014 January 2016

Candy-Plug

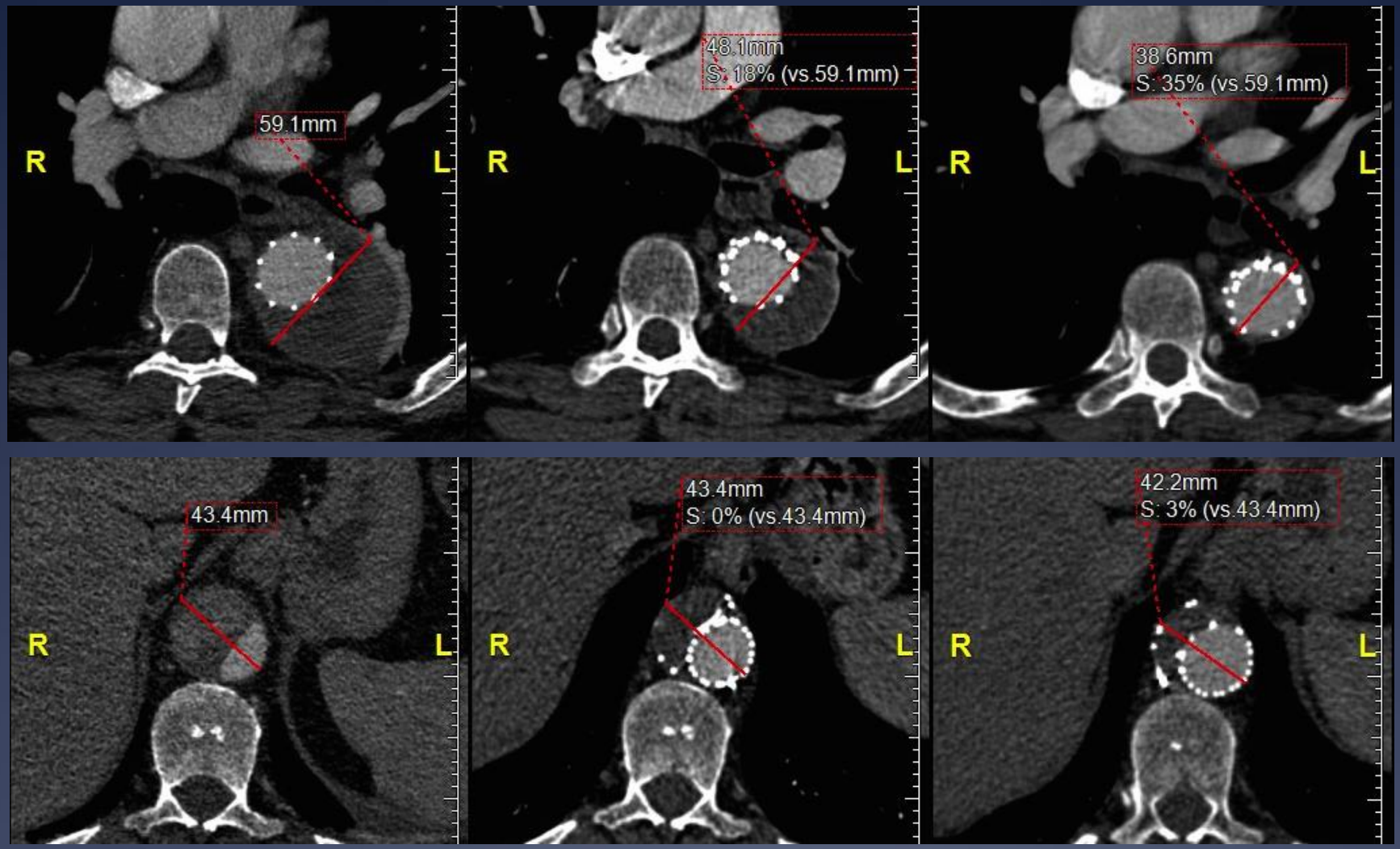

October 2013 January 2014 January 2016

Candy-Plug

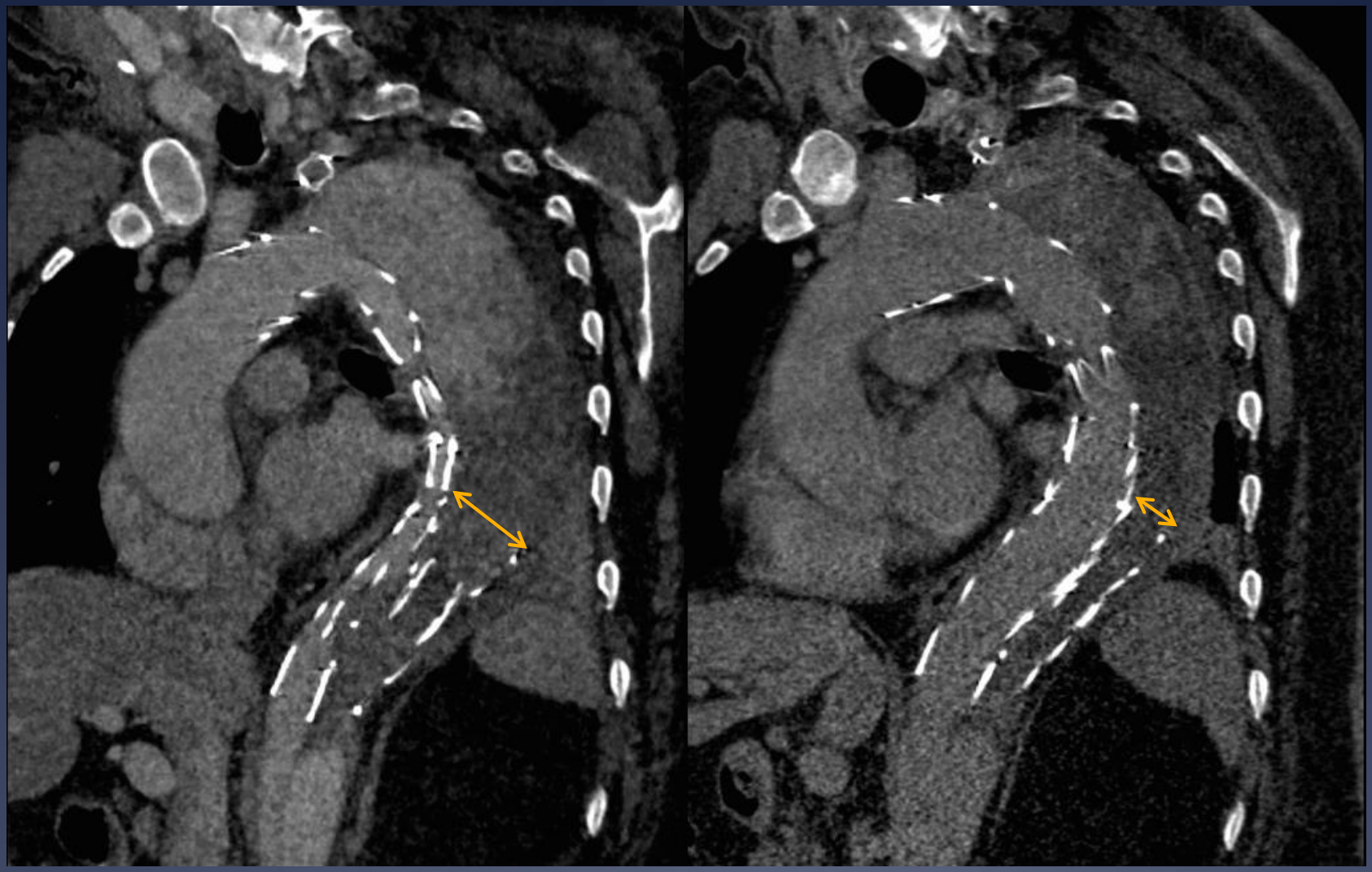

February 2016

July 2016

Candy-Plug

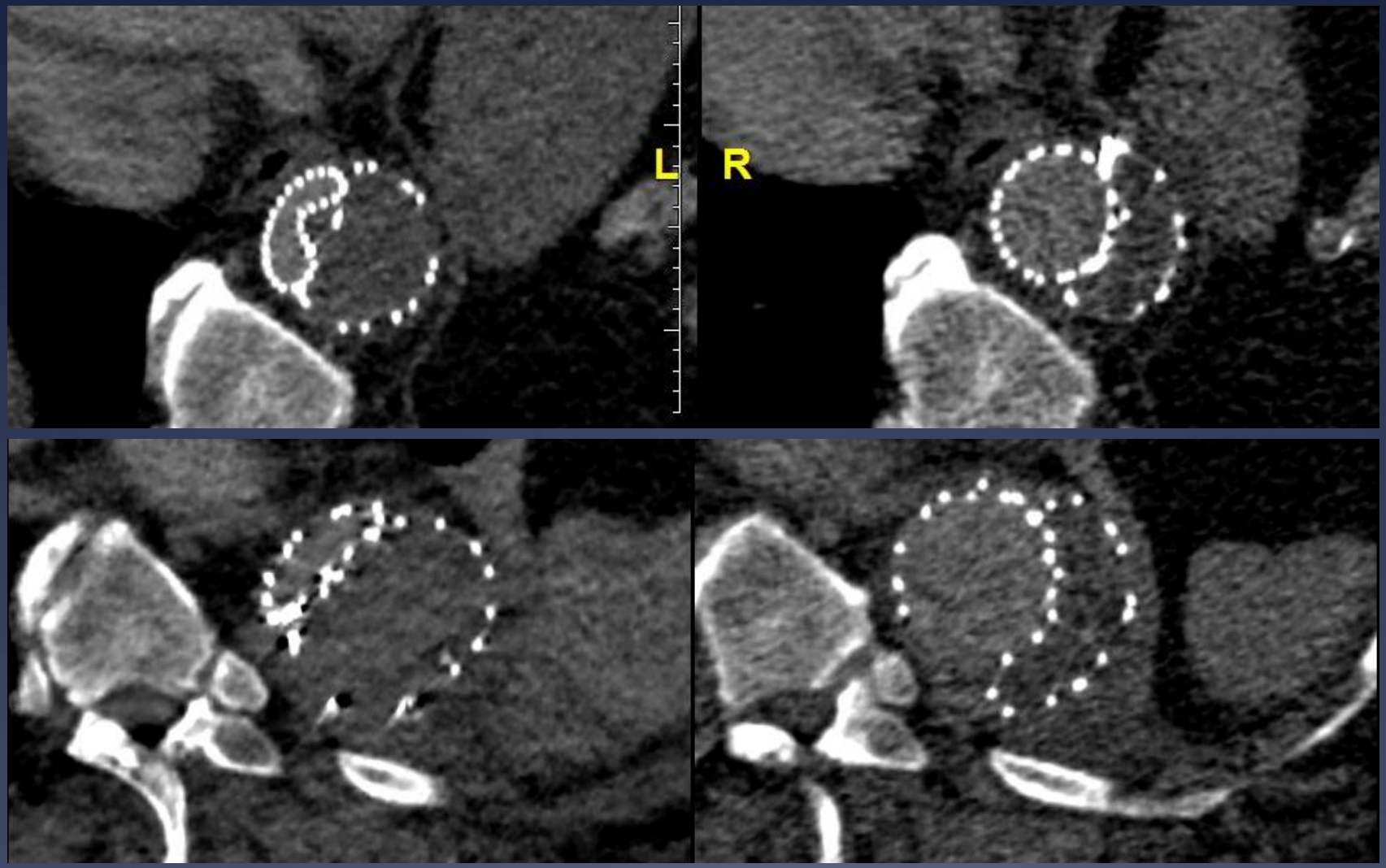

February 2016

July 2016

Candy-Plug Multicenter

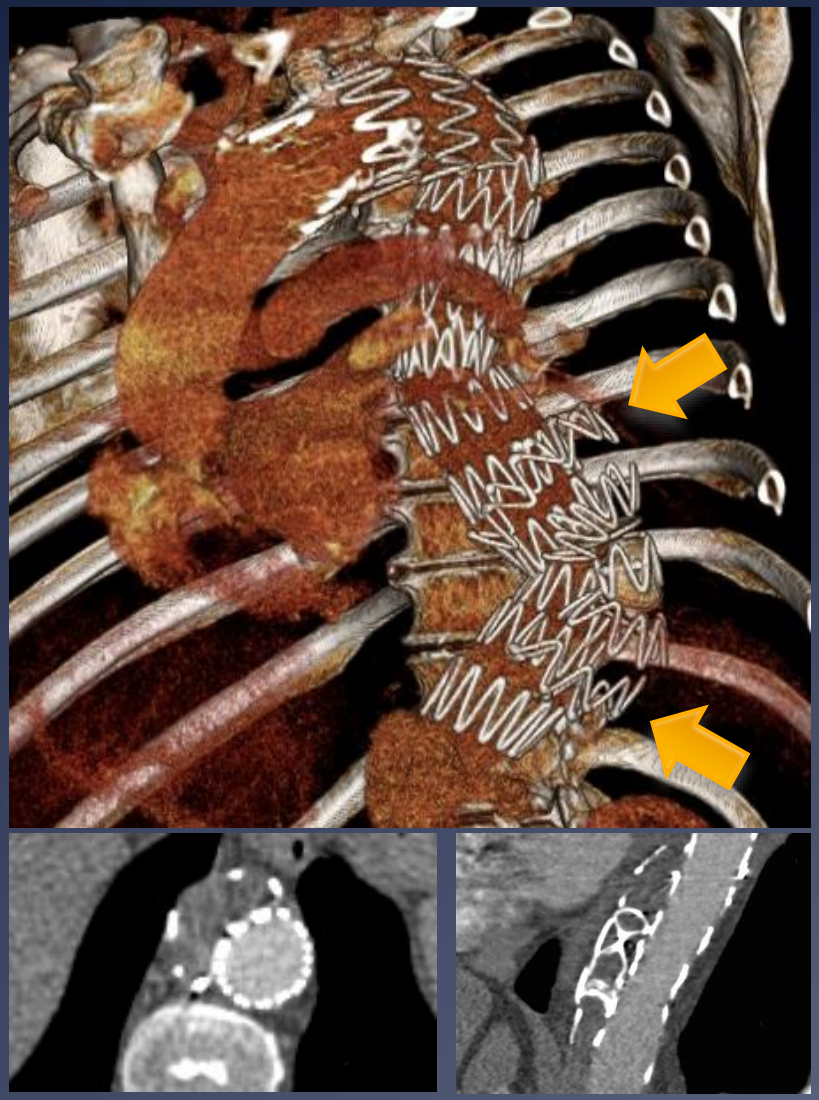

- 2013-2015; N=21
- Technical success 21/21
- No rupture
- No SCI
- No early mortality
- 3 reinterventions for continous perfusion
- Secondary FL-thrombosis 20/21 patients

Knickerbocker-Technique

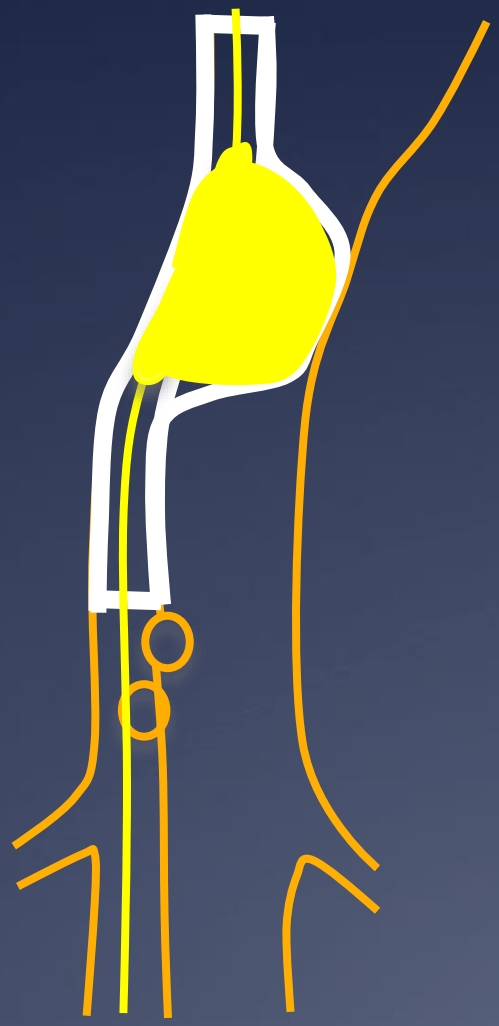

Knickerbocker-Technique

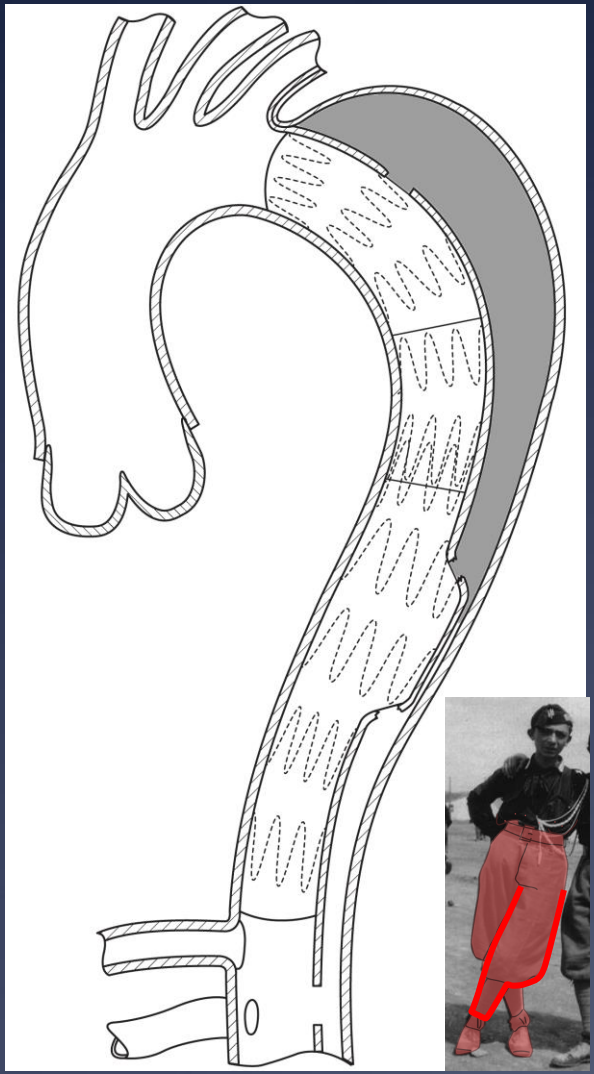

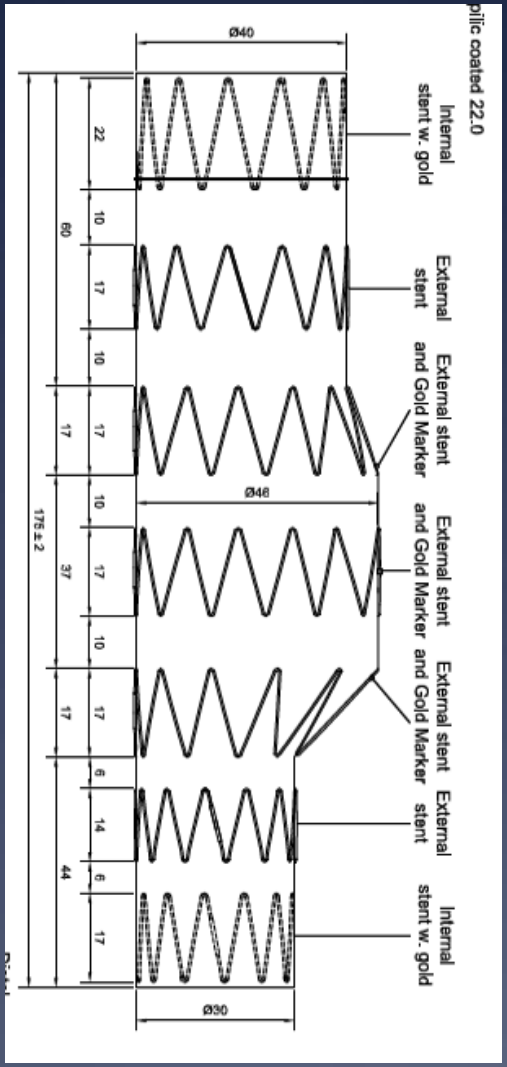

Kölbel et al. 2014; J Endovasc Ther 21: 117-22

Knickerbocker-Technique

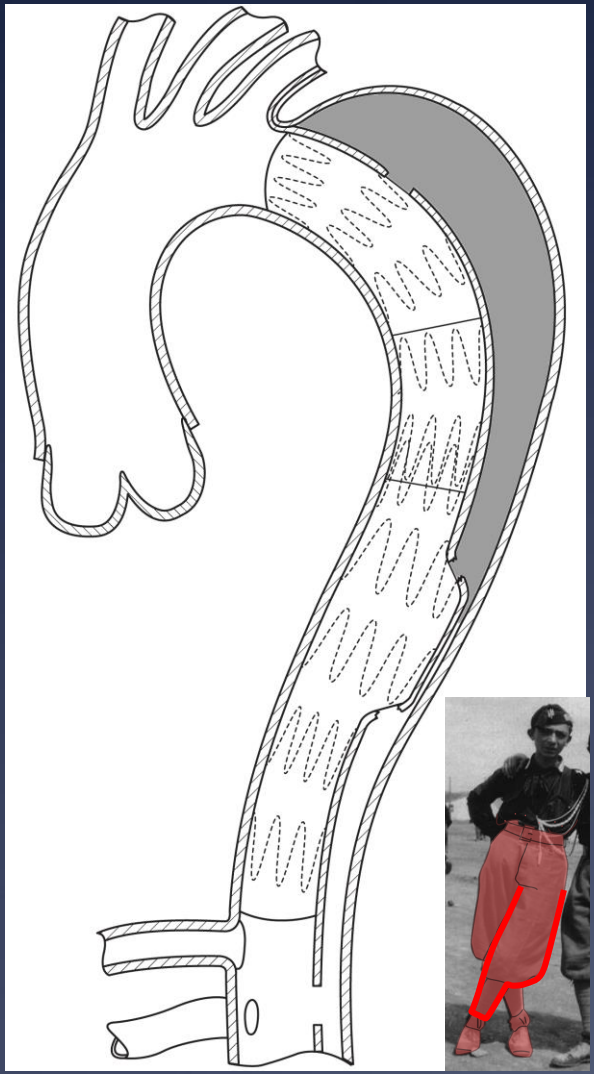

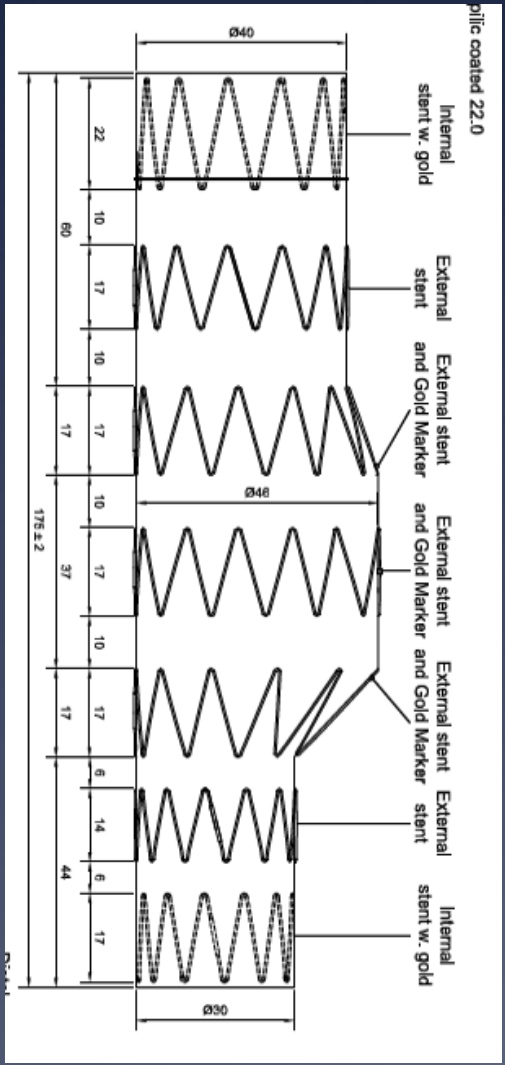

Kölbel et al. 2014; J Endovasc Ther 21: 117-22

Knickerbocker-Technique

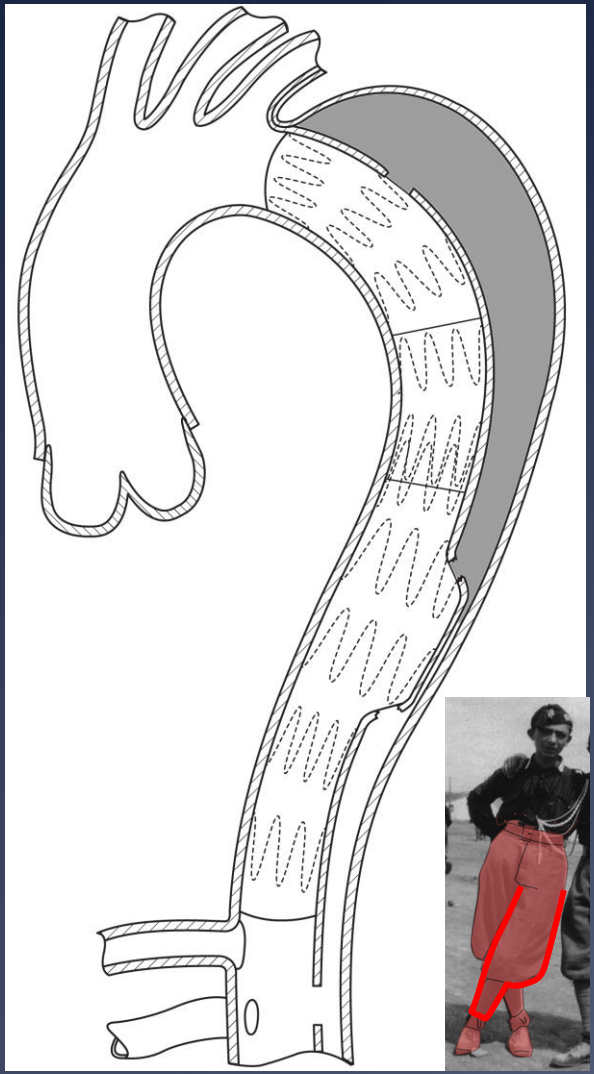

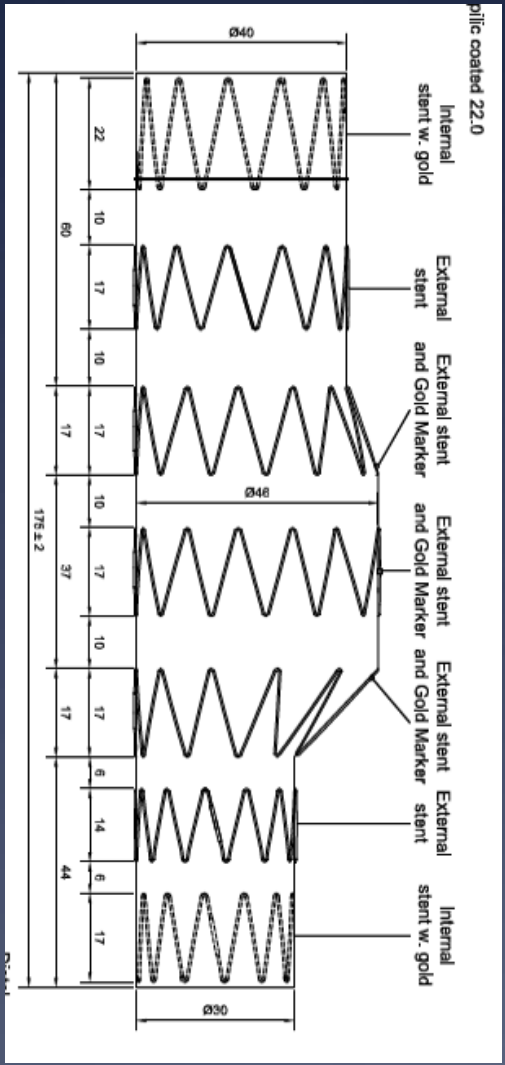



Kölbel et al. 2014; J Endovasc Ther 21: 117-22

Knickerbocker-Technique

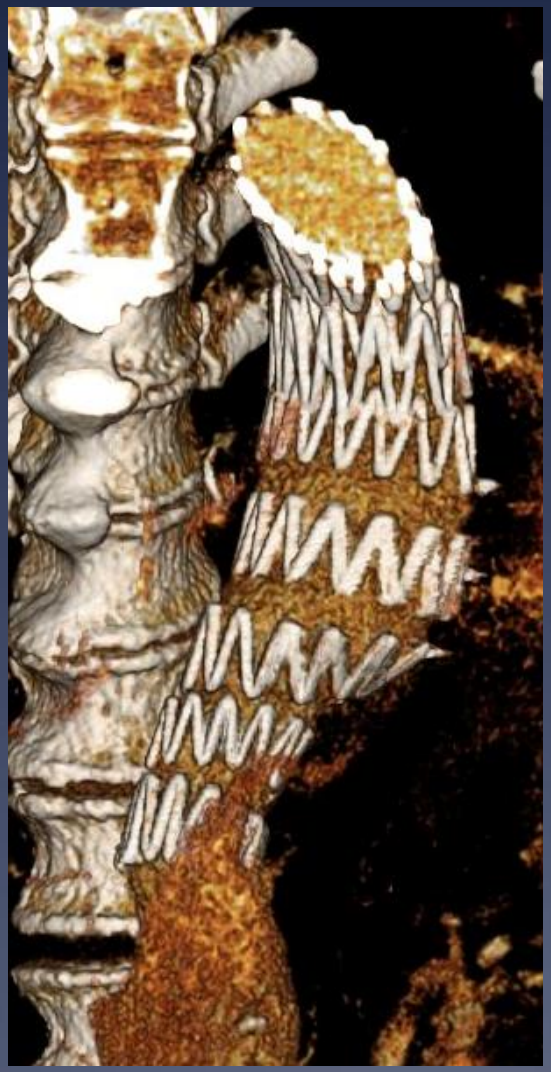

- 2013-2015; N=18
- Technical success 17/18
- 1 rupture
- No SCI
- No mortality
- 4 reinterventions for continous perfusion
- Secondary FL-thrombosis all patients

FL-Aneurysm in Chronic AD

Long-Term Predictors of Descending Aorta Aneurysmal Change in Patients With Aortic Dissection

Jong-Min Song, MD, PHD,* Sung-Doo Kim, MD,* Jeong-Hoon Kim, MD,* Mi-Jeong Kim, MD,*

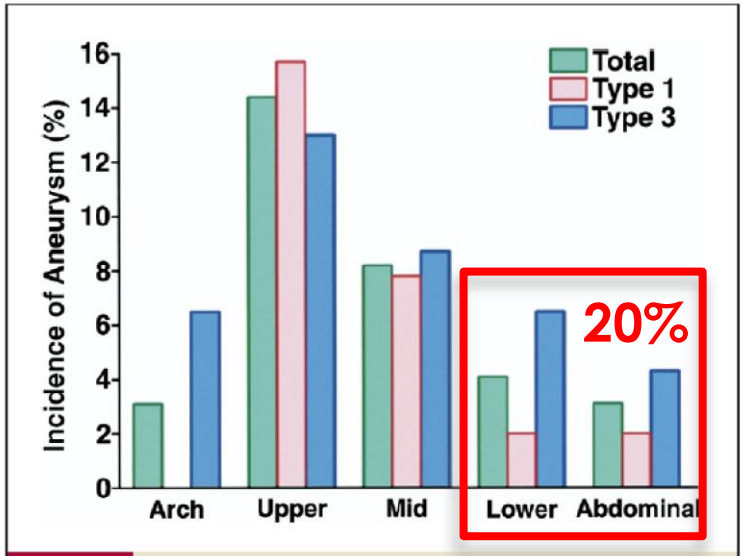

Figure 1 Incidence of Distal Aorta Aneurysm

Incidences of aneurysm at the aortic arch; upper, mid, and lower descending thoracic aorta; and abdominal aorta in patients with type 1 and type 3 aortic dissection.

- N=100: 51 post TAAD; 49 TBAD
- FU: 53±26 months: FL-Aneurysm
  - Aortic arch 3%
  - Upper desc. aorta 14%
  - Mid desc. aorta 8%
  - Lower desc. aorta 4%
  - Abdominal aorta 3%

Song et al. 2007; JACC 50:799-804

fEVAR in Chronic Type B

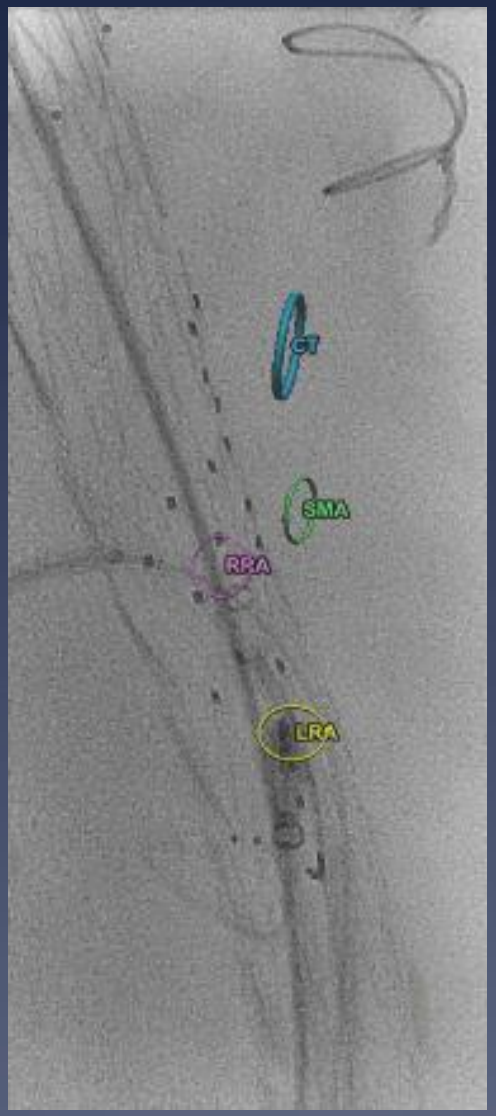

fEVAR in Chronic Type A/B

Outcomes of Fenestrated/Branched Endografting in Post-dissection Thoracoabdominal Aortic Aneurysms

K. Oikonomou [a,b], R. Kopp [a], A. Katsargyris [a], K. Pfister [a], E.L. Verhoeven [b], P. Kasprzak [a,*]

[a] Department of Surgery, Division of Vascular Surgery, University Hospital Regensburg, Regensburg, Germany
[b] Department of Vascular and Endovascular Surgery, Paracelsus Medical University, Nürnberg, Germany

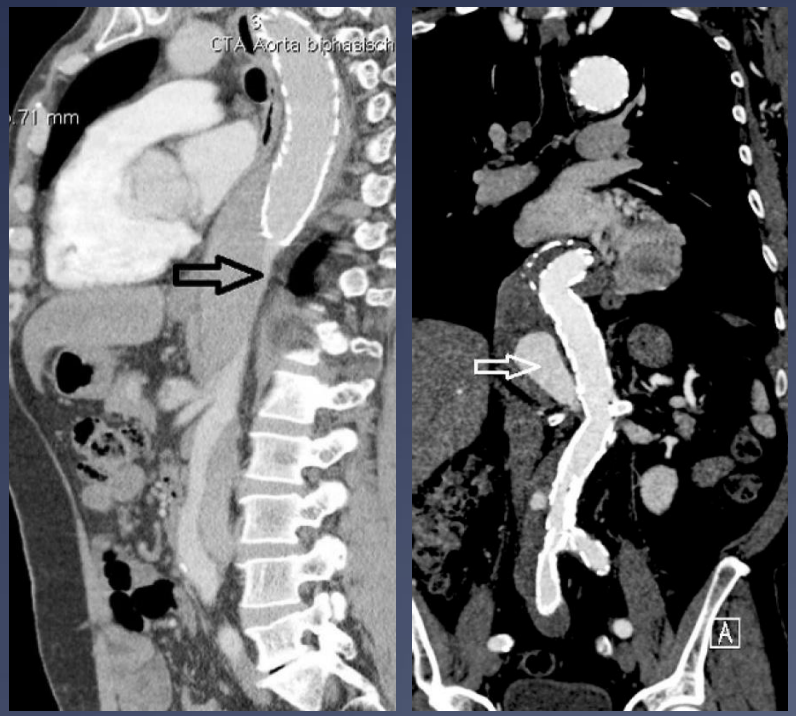

- 2010-2014
- N=31, 17 months FU
- 6 Type II EL; 6 type 1b EL
- 30d-mortality: 9.6%
- Technical success: 93.5%
- FL-thrombosis: 88%

Oikonomou et al. 2014; Eur J Vasc Endovasc Surg 48: 641-8

fEVAR in Chronic Type A/B

Early Experience of Endovascular Repair of Post-dissection Aneurysms Involving the Thoraco-abdominal Aorta and the Arch

R. Spear [a], J. Sobocinski [a], N. Settembre [b], M.R. Tyrrell [c], S. Malikov [b], B. Maurel [a], S. Haulon [a,*]

[a] Aortic Center, Hôpital Cardiologique, CHRU Lille, France
[b] Vascular Surgery, CHU Nancy, France
[c] King's Health Partners, London, UK

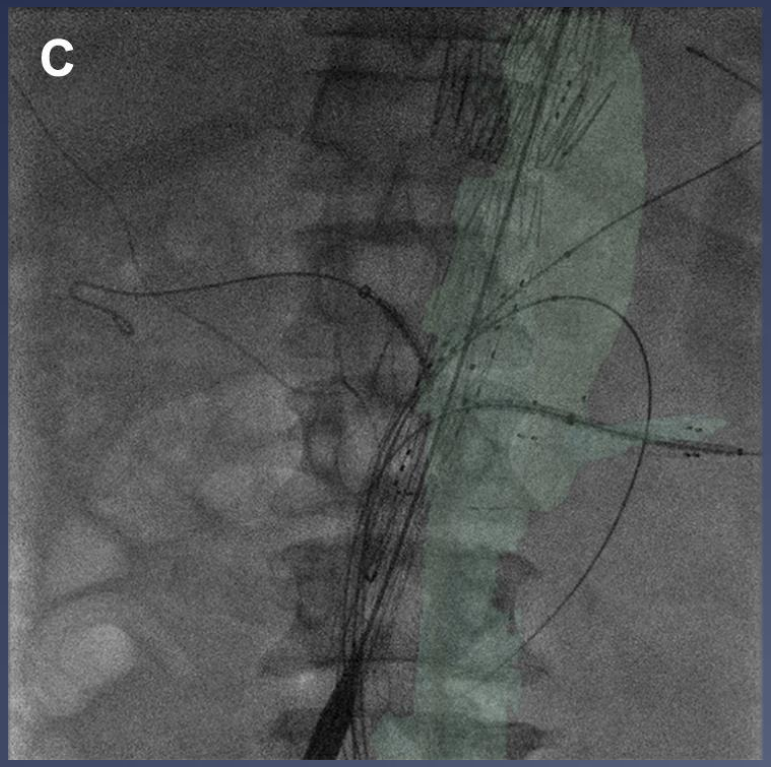

- 2011-2015
- N=16, 6 months mean FU
- Technical success: 100%
- 6 Type II EL; 1 type 3 EL
- In-hospital mortality: 6% (1/16)
- Paraplegia: 6% (1/16)
- FL-thrombosis: 56%

Spear et al. 2016; Eur J Vasc Endovasc Surg 51:488-97

Role of FL-Occlusion:

Hamburg 2013-2015:

- Chronic aortic dissection/failing TEVAR: 39
- False Lumen Occlusion techniques: 31
  - Candy-plug 14
  - Knickerbocker 12
  - Other (plugs, coils, glue) 5
- Primary F/B EVAR 8
- Secondary F/B EVAR 2

2

Secondary F/B EVAR

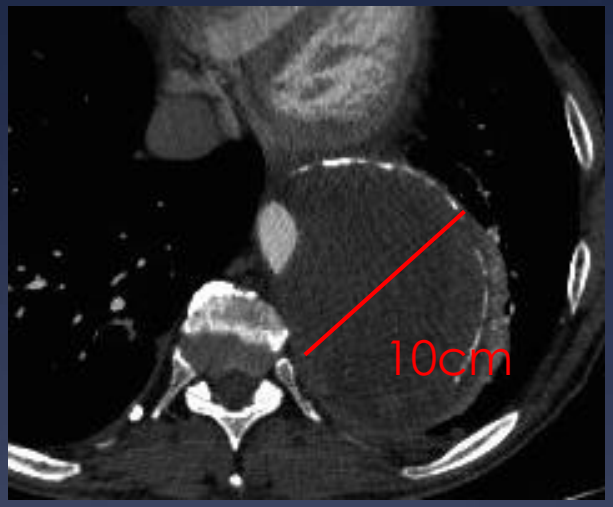

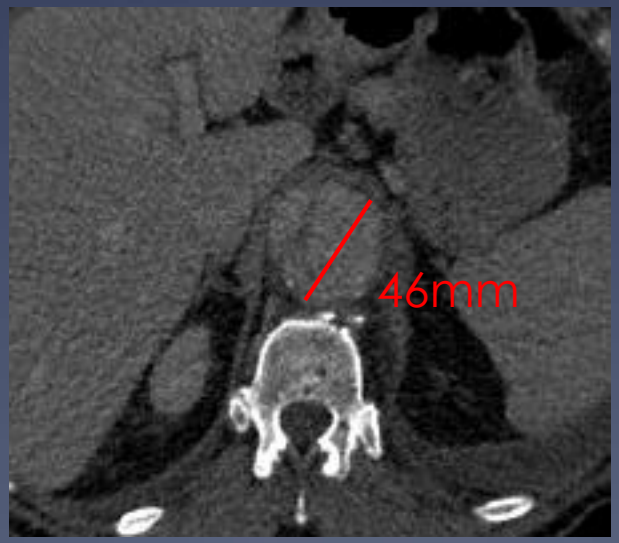

Secondary F/B EVAR

FET, TEVAR+Candyplug

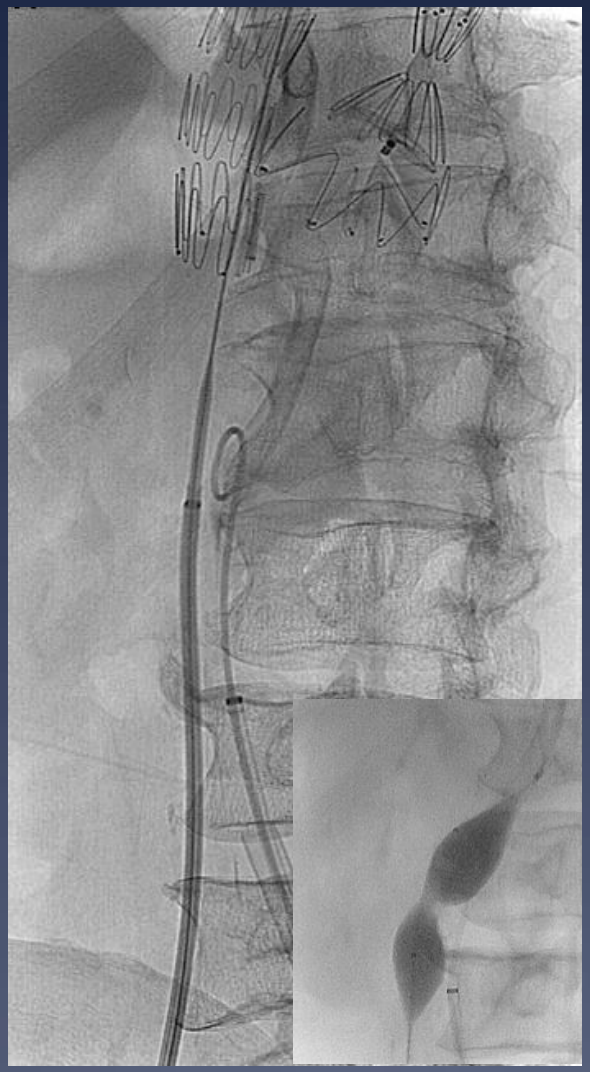

+ Fenestration

F/B EVAR

Iliac False Lumen Embolisation

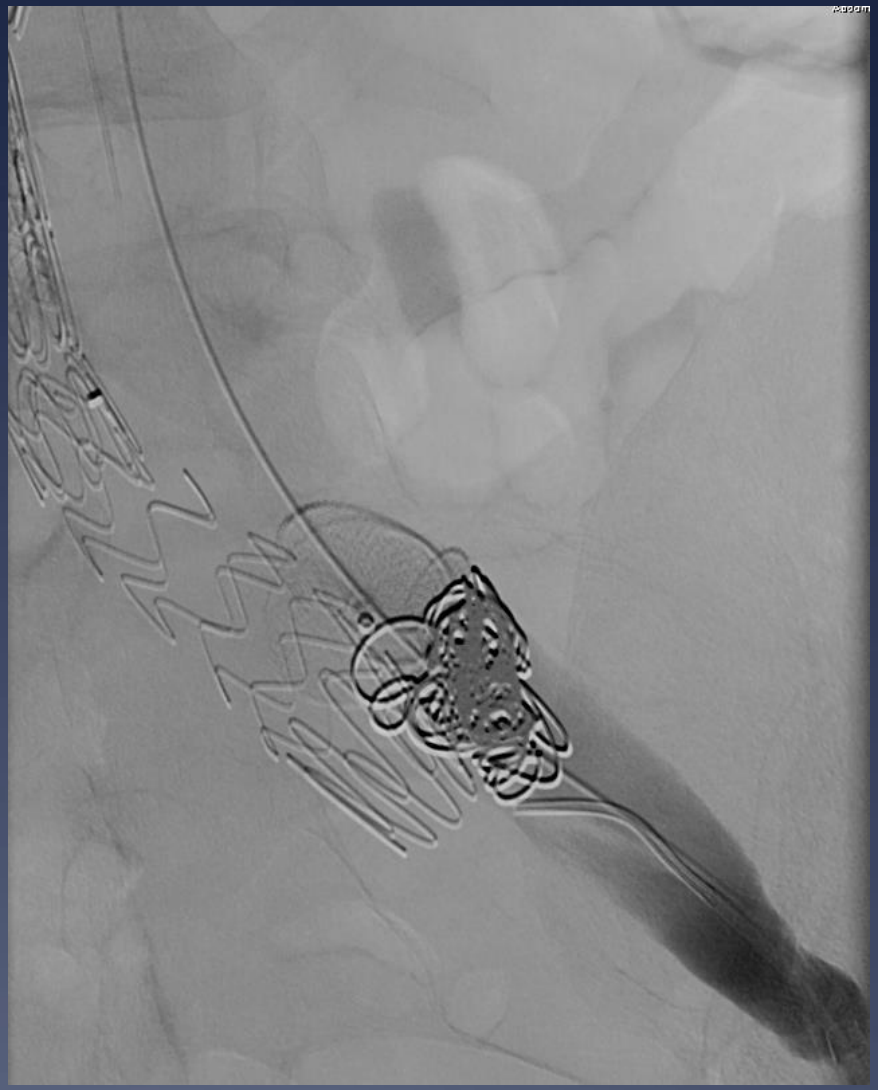

Ballon-occlusion to prevent plug-embolisation

Conclusion

- Tubular stent-graft sufficient in majority cases of TBAD.
- False lumen backflow limiting treatment success in chronic TBAD.
- Techniques for false-lumen embolisation:
  - Plugs, coils, glue
  - Candy-plug
  - Knickerbocker-technique
- Experience promising, but future role to be defined.
- F/B stentgrafts reserved for abdominal FL-aneurysm.