



2016

October 17-18, 2016
Philharmonie Essen, Germany

3rd Aortic Live Symposium

Mega Aortic Syndrome (MAS) type III Lupiae Technique

G. Esposito, MD

Mater Dei Hospital - Bari, Italy



Disclosure

Speaker name: Giampiero Esposito

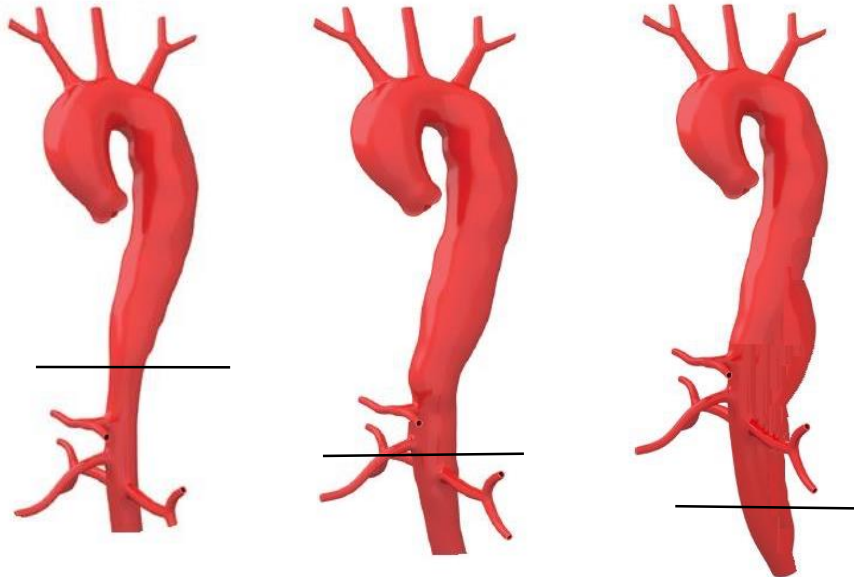
I do not have any potential conflict of interest

□

Case Presentation: MAS type III

73yrs, male

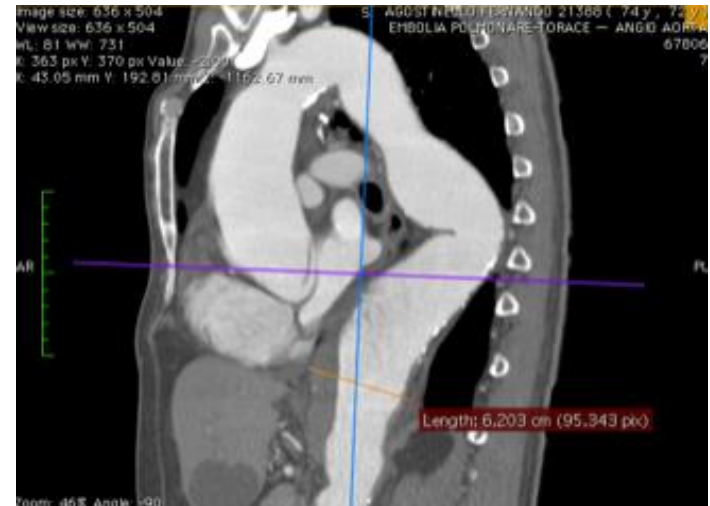
Spastic Paraparesis and Chronic Progressive Myelopathy
(after spine surgery: posterior cervical micro-discectomy)



Type I

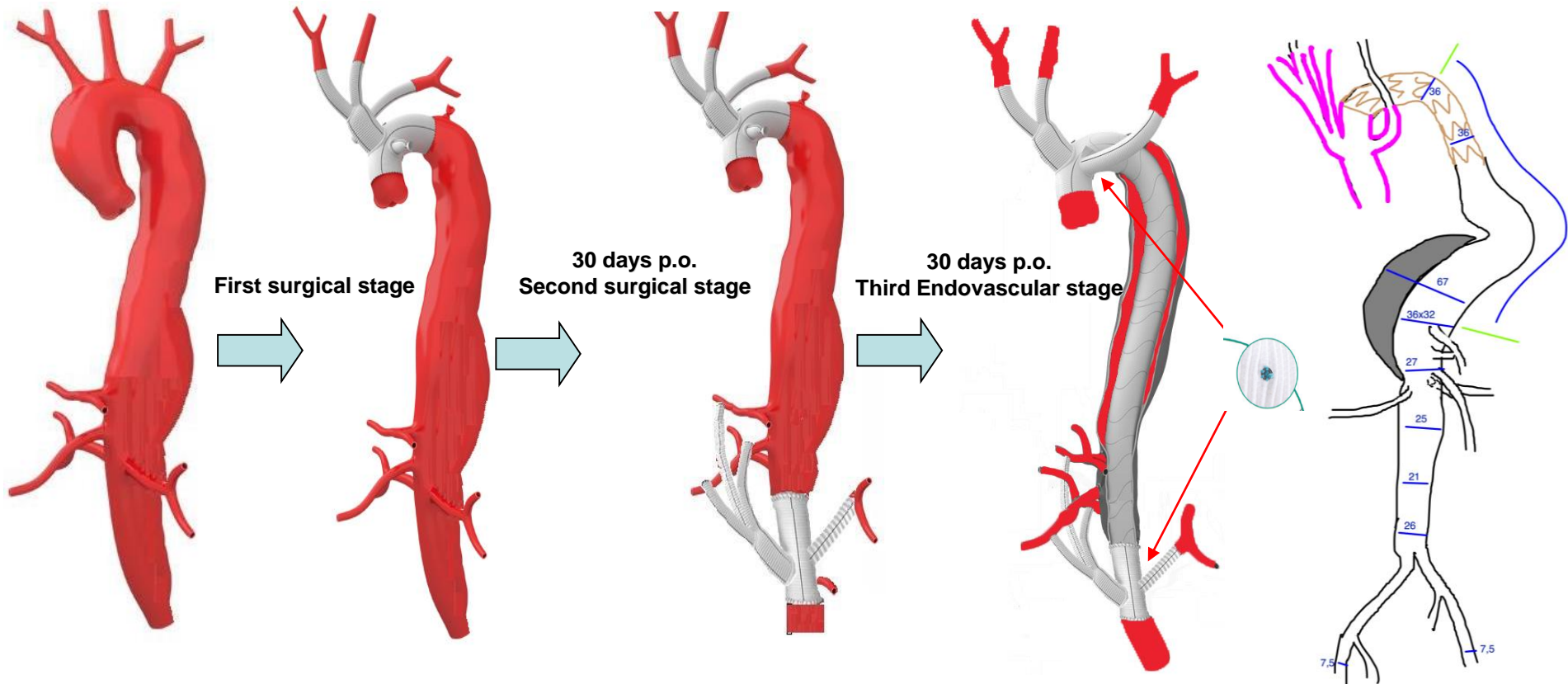
Type II

Type III



MAS CLASSIFICATION - Esposito G, Cappabianca G et al. Innovations 2011; 6(6): 366-372

MAS III: Hybrid Three-Stage Repair



- 1) Epaortic vessels rerouting and ascending aorta ± arch replacement by Lupiae Graft™ implantation
- 2) Retrograde de-branching of visceral vessels and abdominal aorta replacement by Lupiae Graft™ implantation.
- 3) Subsequent Endograft repair

Troisi N, Esposito G, Bichi S et al: JTCS 2013;Mar 145(3 suppl):S171-7

