University Heart Center Hamburg

GERMAN AORTIC CENTER HAMBURG

Arch Endo Repair:

The Cook Perspective

Tilo Kölbel, Sebastian Debus, Yskert von Kodolitsch, Nikos Tsilimparis, Christian Detter

German Aortic Center
University Heart Center Hamburg

AORTIC LIVE 2016
October 17–18, 2016
Philharmonie Essen, Germany

Disclosures

- Research-grants, travelling, proctoring speaking-fees, IP with Cook.
- Consultant to Philips

Gold Standard for the Arch

Surgery for the aortic arch:

- Open repair
- Elephant trunk

Mortality rates 5-20%

Stroke: 3-12%

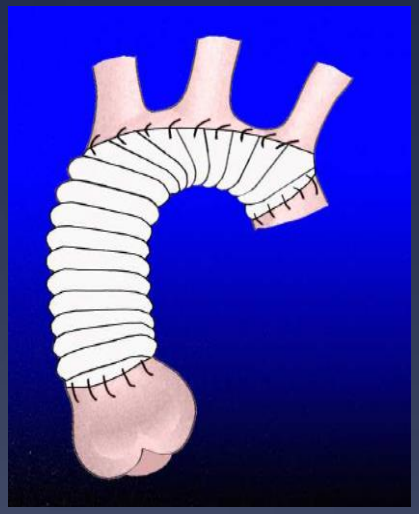

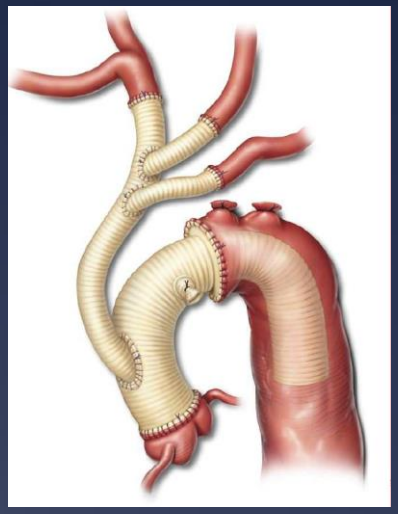

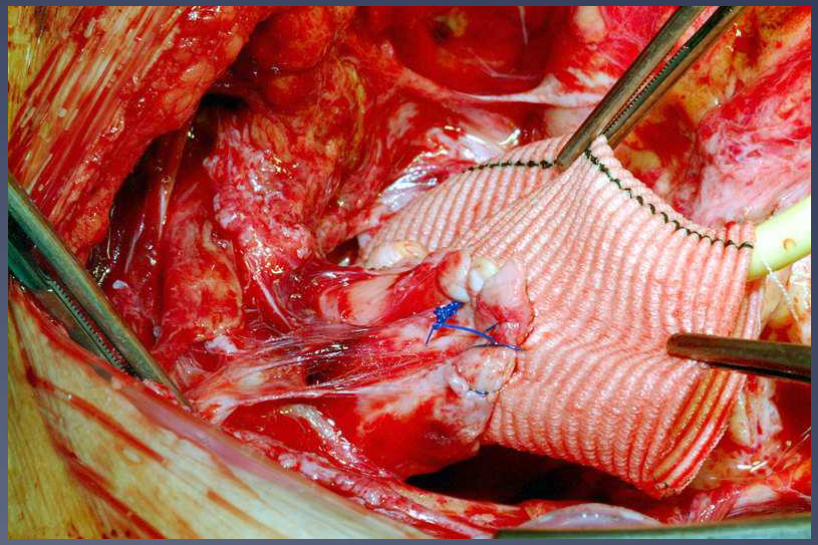

Tanaka et al. 2014; Ann Thorac Surg 97:1569-75
Cazavet et al. 2015; Eur J Cardiothorac Surg 49:134-40
Minakawa et al. 2010; Ann Thorac Surg 90:72-7
Sundt et al. 2008; Ann Thorac Surg 86:787-96

Contemporary FET-Results

Total aortic arch replacement with a novel 4-branched frozen elephant trunk prosthesis: Single-center results of the first 100 patients

Malakh Shrestha, MBBS, Tim Kaufeld, MD, Erik Beckmann, MD, Felix Fleissner, MD, Julia Umminger, MD, Firas Abd Alhadi, MD, Dietmar Boethig, MD, Heike Krueger, RN, Axel Haverich, MD, and Andreas Martens, MD

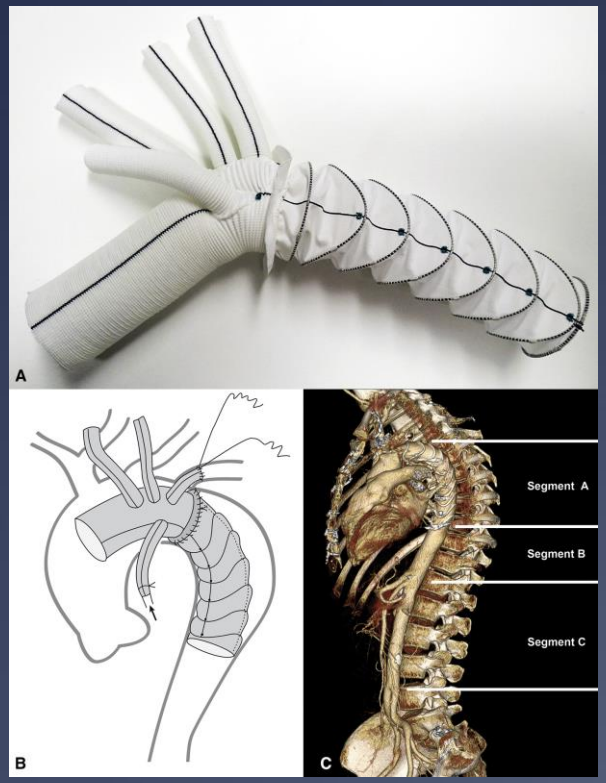

- Single center; n=100
- Age 62y
- Perioperative mortality 7%
- Stroke 9%
- Paraparesis 7%
- Dialysis 8%
- Recurrent nerve palsy 25%

Shresta et al. 2016; J Thorac Cardiovasc Surg 152:148-59

Open Surgery vs. Endovascular

Contemporary comparison of aortic arch repair by endovascular and open surgical reconstructions

Paola De Rango, MD, PhD,[a] Ciro Ferrer, MD,[b] Carlo Coscarella, MD,[b] Francesco Musumeci, MD,[c] Fabio Verzini, MD, PhD, FEBVS,[a] Gabriele Pogany, MD,[b] Andrea Montalto, MD,[c] and Piergiorgio Cao, MD, FRCS,[b] *Perugia and Rome, Italy*

- 2007-2014
- 29 OSR vs. 71 Endo
- 26m mean FU
- Endo-pat. older and sicker
- Stroke/Death: 17% vs.11% (n.s.)

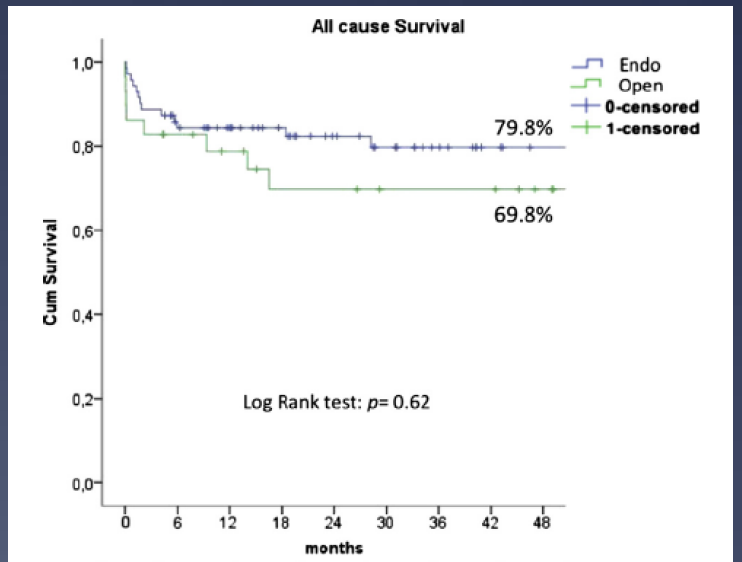

	months	0	12	24	36	48
ENDO	n° at risk	71	49	34	22	14
	st. error	0	0.04	0.05	0.05	0.05
OPEN	n° at risk	29	19	14	13	10
	st. error	0	0.08	0.09	0.09	0.09

DeRango et al. 2015; J Vasc Surg 61:339-46

Endovascular Advantages:

- No Clamping of the Aorta
- No cardio-pulmonary Bypass
- No cardiac arrest
- Reduced access trauma
- Repair while „engine running“

Endovascular Options for the Aortic Arch

- Chimney Grafts
- In-Situ Fenestration
- Fenestrated/ Branched Stent-grafts

Bail-out Techniques

Branched Arch Repair



Outer Branches

Inner Branches

Cook– Branched Arch Endograft

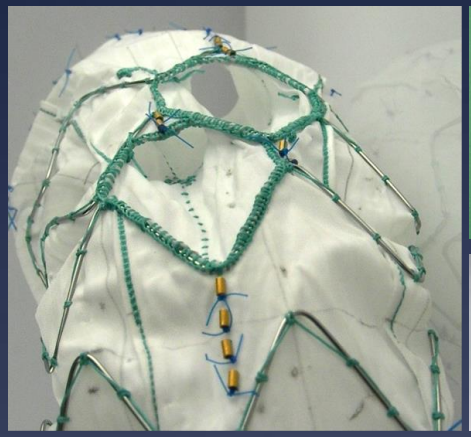

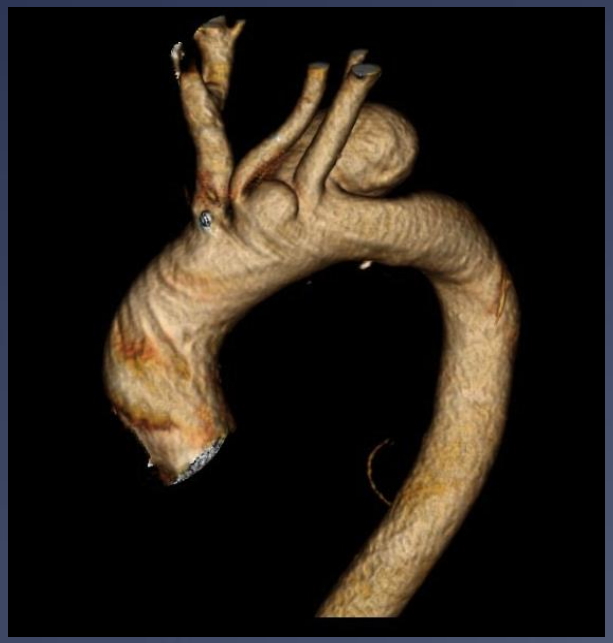

Branched Arch Endograft

Global experience with an inner branched arch endograft

Stéphan Haulon, MD, PhD,[a] Roy K. Greenberg, MD,[b] Rafaëlle Spear, MD,[a] Matt Eagleton, MD,[b] Cherrie Abraham, MD,[c] Christos Lioupis, MD,[c] Eric Verhoeven, MD, PhD,[d] Krassi Ivancev, MD,[e] Tilo Kölbel, MD, PhD,[f] Brendan Stanley, MD,[g] Timothy Resch, MD,[h] Pascal Desgranges, MD, PhD,[i] Blandine Maurel, MD,[a] Blayne Roeder, PhD,[j] Timothy Chuter, MD,[k] and Tara Mastracci, MD[b]

- 2009-2013
- Multicenter Study
- n = 38
- Technichal success 32/38
- Mortality 5/38 (13%)
- Stroke/TIA 6/38 (16%)



Haulon et al. 2014; J Thor Cardiovasc Surg 148:1709--16

Anatomical Suitability

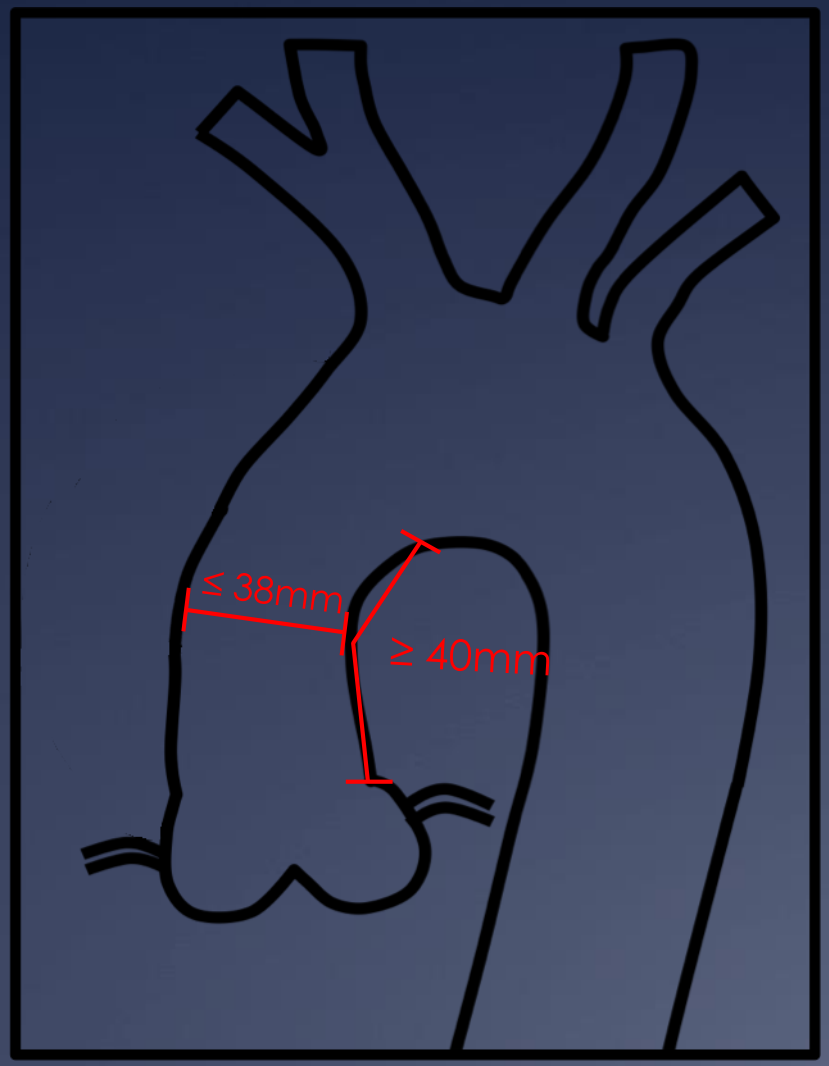

- Diameter ≤ 38mm
- Length ≥ 40mm
- Proximal landing zone ≥ 20mm
- Innominate diameter ≤ 20mm
- Appropriate access vessels
- No significant aortic regurge
- No mechanical aortic valve
- No dissection of branch-vessels

Technique

- Two stage repair:
  - 1. LCCA-LSA bypass
  - 2. Branched repair:
- Transfemoral access for the main-graft
- RCCA-cutdown for IA-branch
- Left brachial puncture for LCCA-branch and LSA-plug

Technique

- Precurved self-orienting device
- LV-wire position
- Cardiac output-reduction:
  - IVC balloon-occlusion
  - Rapid ventricular pacing
- Zenith-limb for IA
- Fluency for the LCCA
- Plug-occlusion for LSA

Lesion-Type

- Aneurysm and PAU of the arch
- Chronic dissection
- Acute Type A dissection

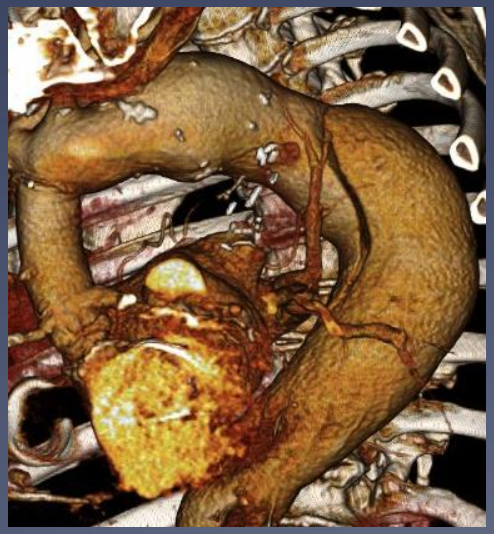

Residual Dissection

Potential challenges:

* Kinking of ascending graft
* Dissection of targetvessels with multiple entries
* Distal false-lumen perfusion

Residual Dissection

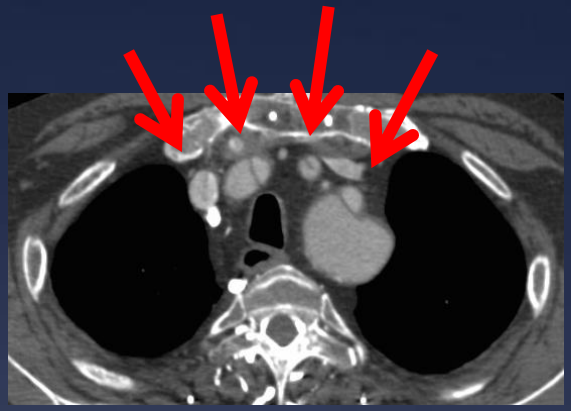

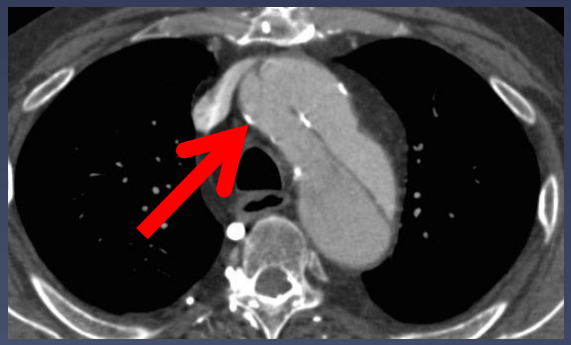

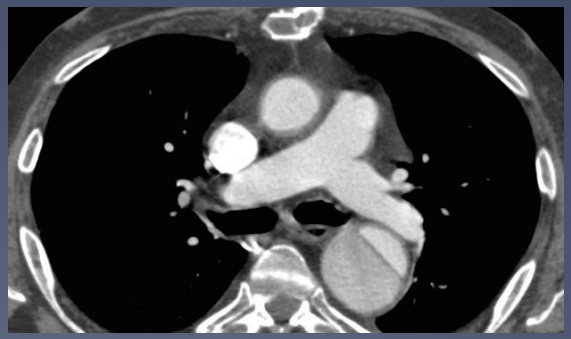

Residual Dissection

Bilateral carotid-subclavian bypass

Axillo-axillary bypass

Residual Dissection

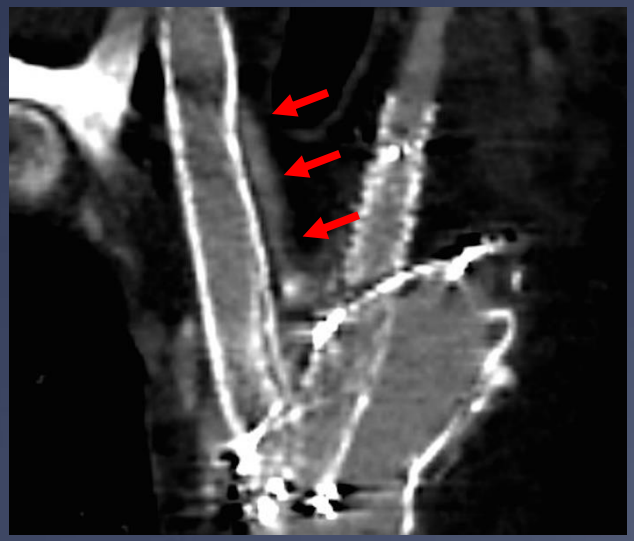

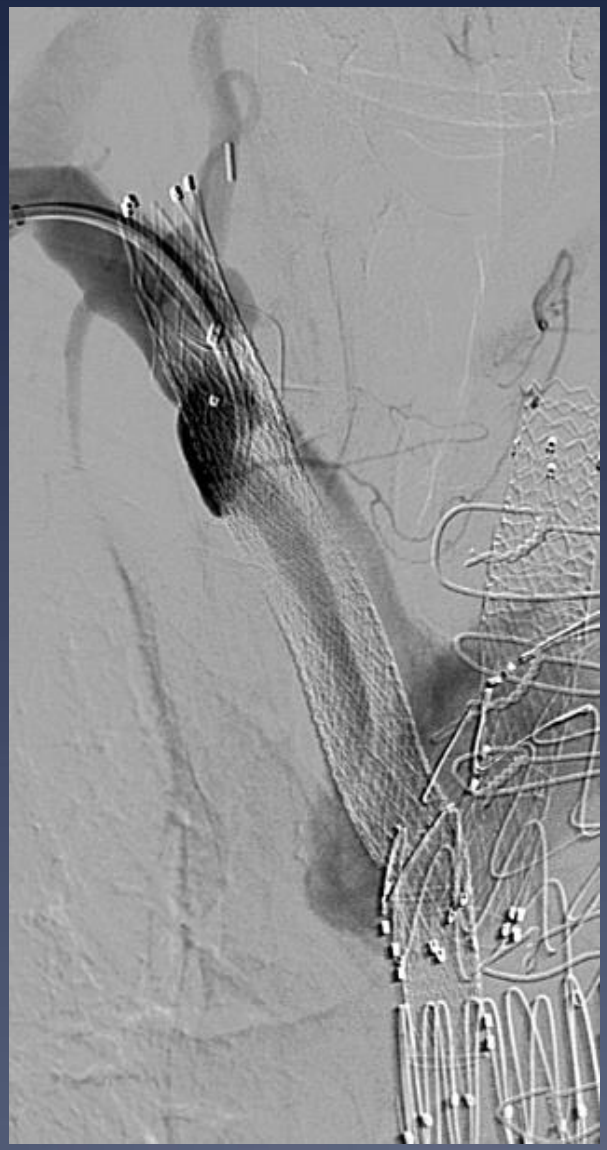

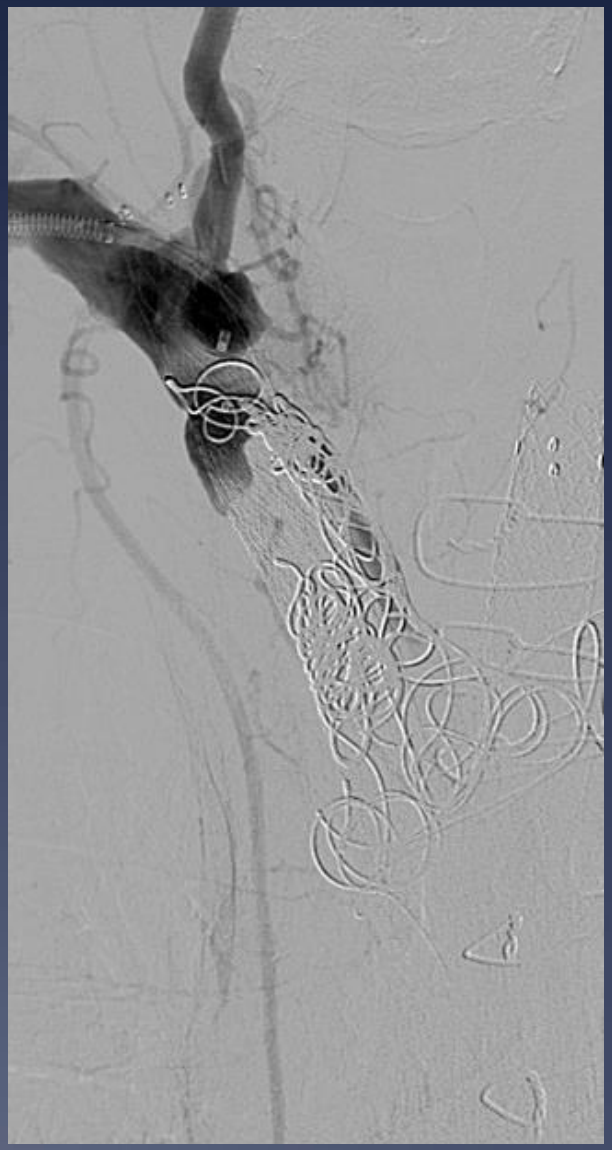

Cook Branched Arch Endograft

Subsequent experience:

- n = 27; Hamburg, Tokio, Lille
- 4/2013- 11/2014
- Technical success 27/27
- 30d Mortality 0/27
- 1y mortality 1/27
- Stroke/TIA 3/27

Spear et al 2016; Eur J Vasc Endovasc Surg 51: 380-5

Staged Debranching

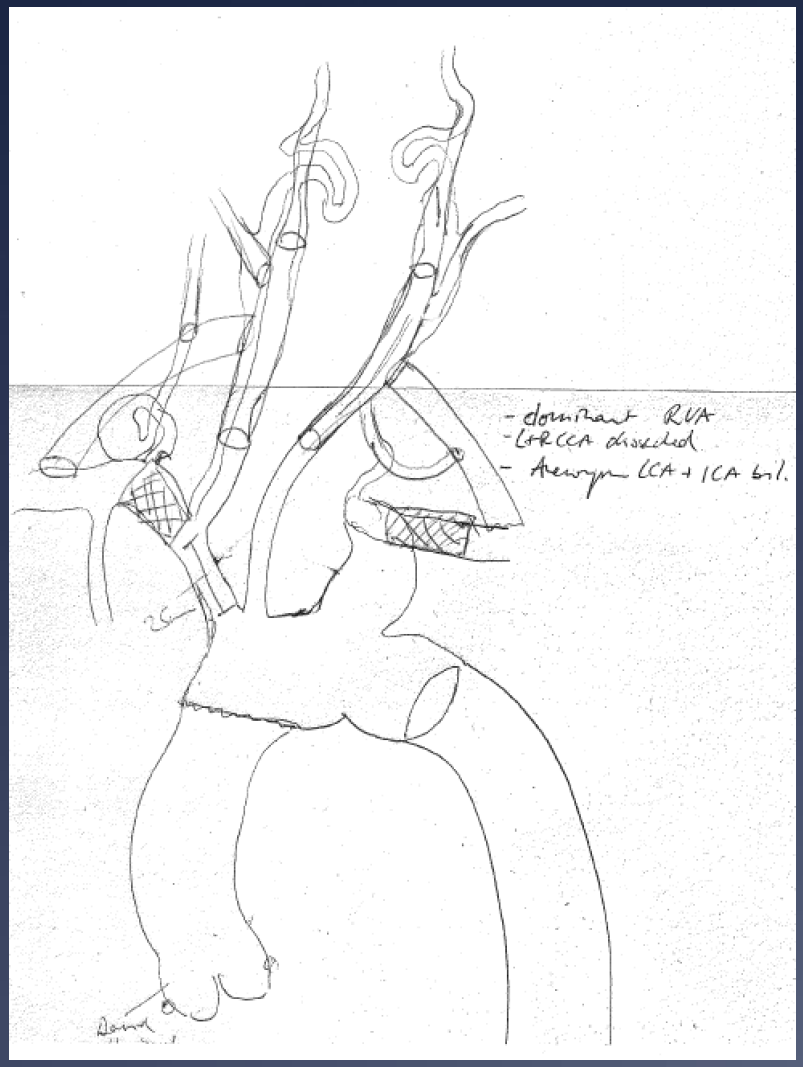

Staged Debranching

Interposition Graft LCCA

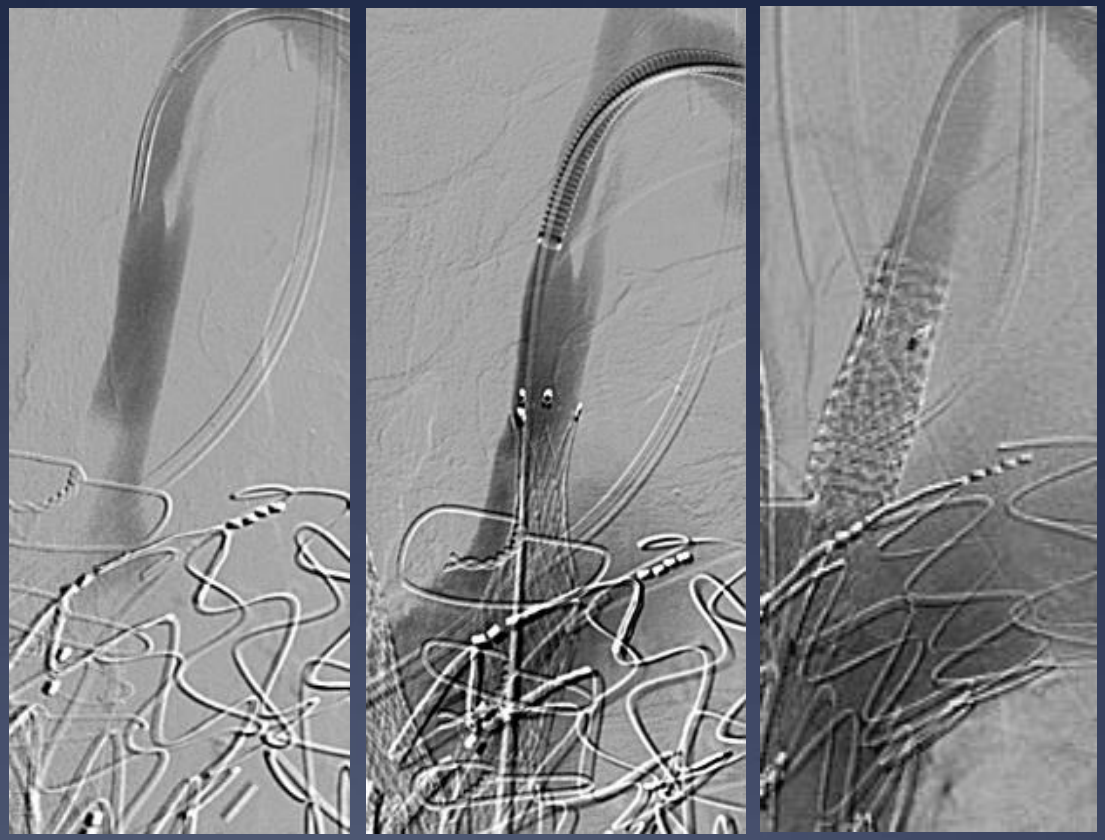

Landing in dissected LCCA

Acute Type A Dissection Branched Arch Endograft

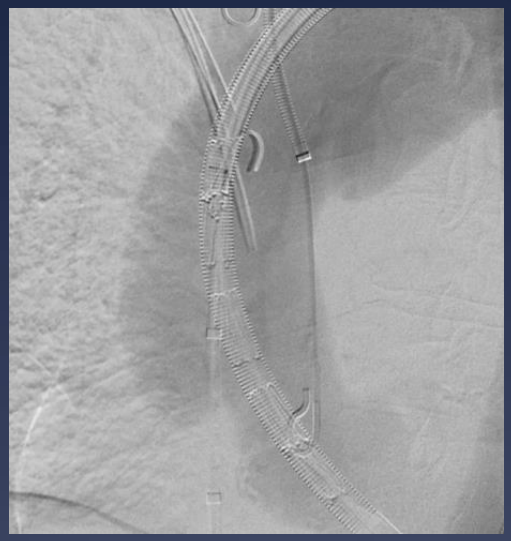

Kölbel et al. 2016; J Endovasc Ther, accepted

Be aware of CAB

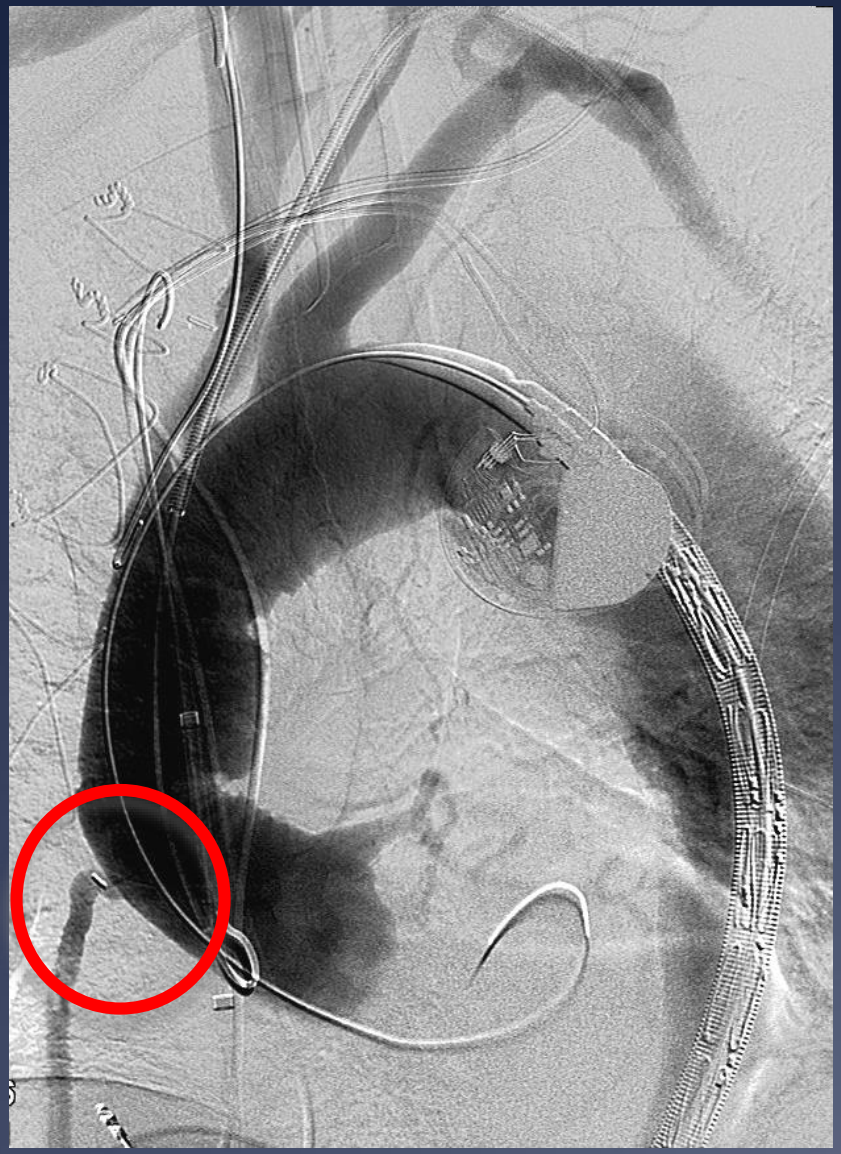

Mechanical Valve

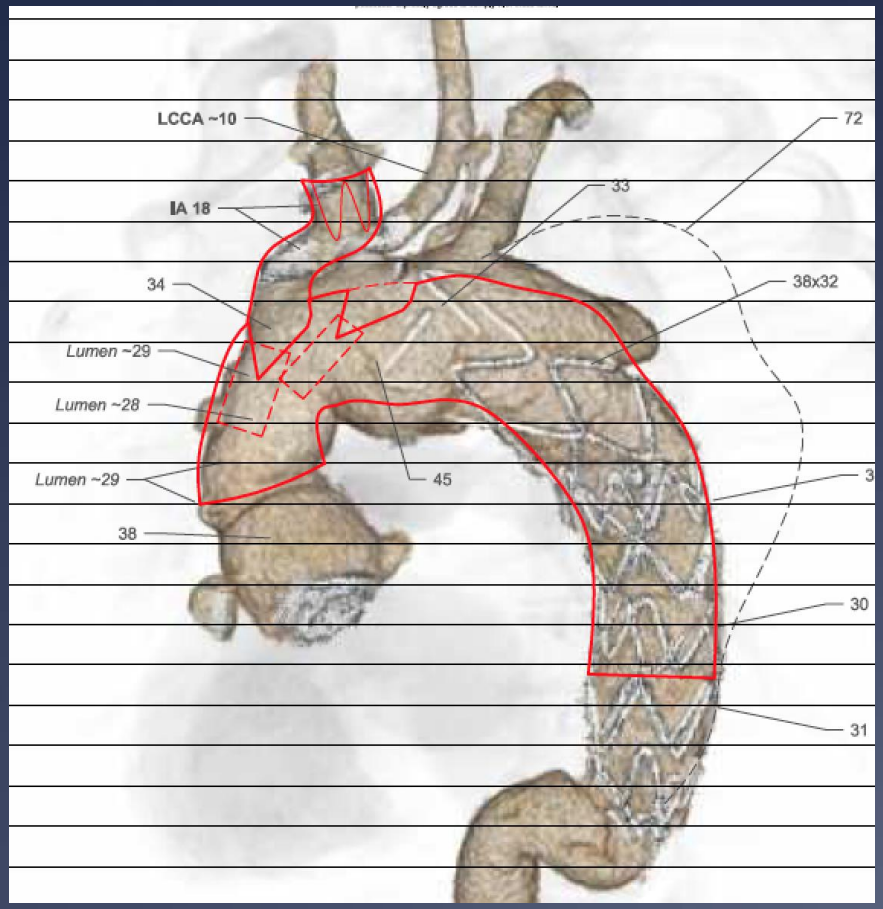

Spear et al. 2014; Eur J Vasc Endovasc Surg

CO^2 - Flushing

Carbon Dioxide Flushing Technique to Prevent Cerebral Arterial Air Embolism and Stroke During TEVAR

Journal of Endovascular Therapy
1–3
© The Author(s) 2016
Reprints and permissions:
sagepub.com/journalsPermissions.nav
DOI: 10.1177/1526602816633705
www.jevt.org
SAGE

- 2014-2015: n=36
- All complex arch and ascending TEVAR:
  - Branched arch
  - Fenestrated arch
  - Ascending TEVAR
- All zone 0 -1
- Stroke: 1/36 (3%)
  - minor non-disabling stroke

Kölbel et al 2016; J Endovasc Surg 23: 393-5

Cook Branched Arch Endograft

<u>Hamburg Experience 2012-2016:</u>

- Cases: 40
  - Aneuysm: 18
  - Residual dissection: 17
  - Acute Type A: 2
  - PAU: 3
- 30d-Mortality: 2 (5%)
- Stroke: 2 (5%)

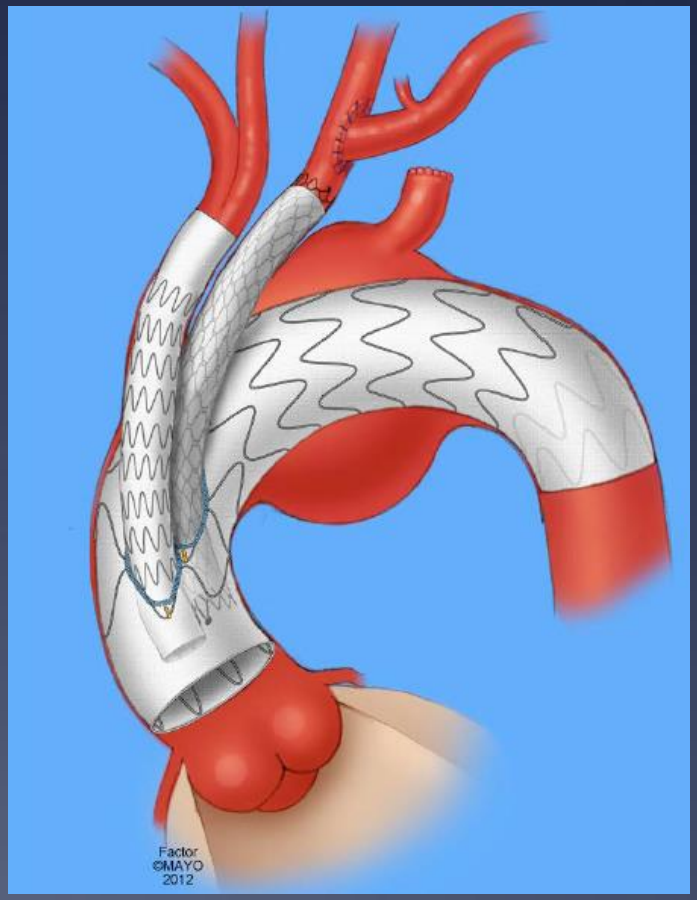

Courtesy of Gustavo Oderich, Mayo-Clinic

Post TAAD-Repair

Post TAAD-Repair

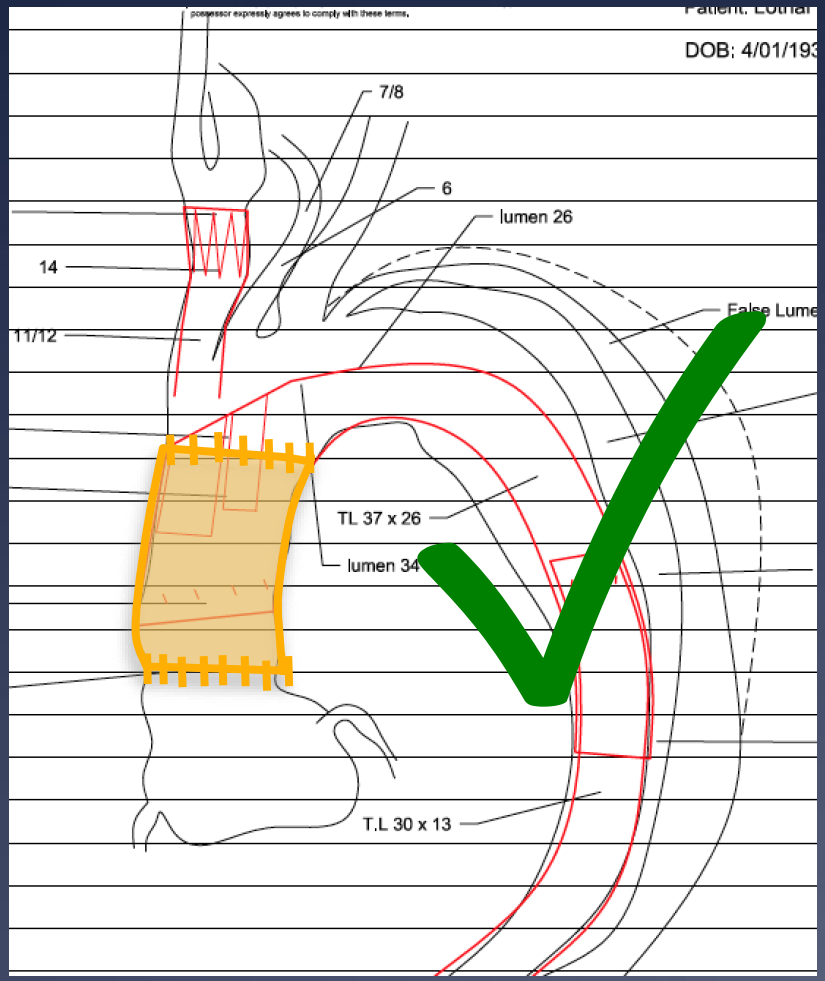

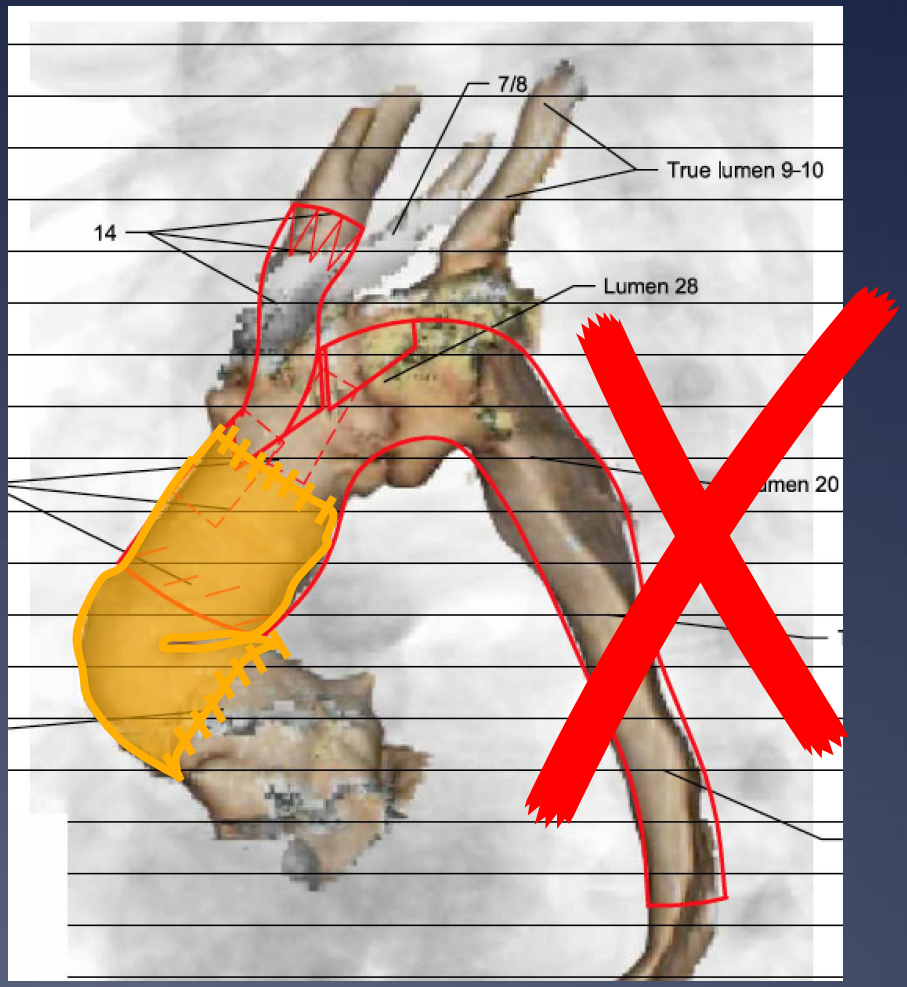

Post TAAD-Repair

Inner-Branched Endografts for the Treatment of Aortic Arch Aneurysms After Open Ascending Aortic Replacement for Type A Dissection

Charles P. E. Milne, MBBS (Hons), FRACS (Vasc), Mau Amako, MD, PhD, Rafaelle Spear, MD, PhD, Rachel E. Clough, MRCS, PhD, Adrien Hertault, MD, Jonathan Sobocinski, MD, PhD, Wendy Brown, MBBS (Hons), PhD, and Stéphan Haulon, MD, PhD

- N=73; 2009-2015 Type 1 AD
- Eligibility for B-TEVAR
- Access, diameter, angulation
- 70% anatomically suitable

Milne et al. 2016; Ann Thor Surg; epub

UNIVERSITY HEART CENTER
UHC

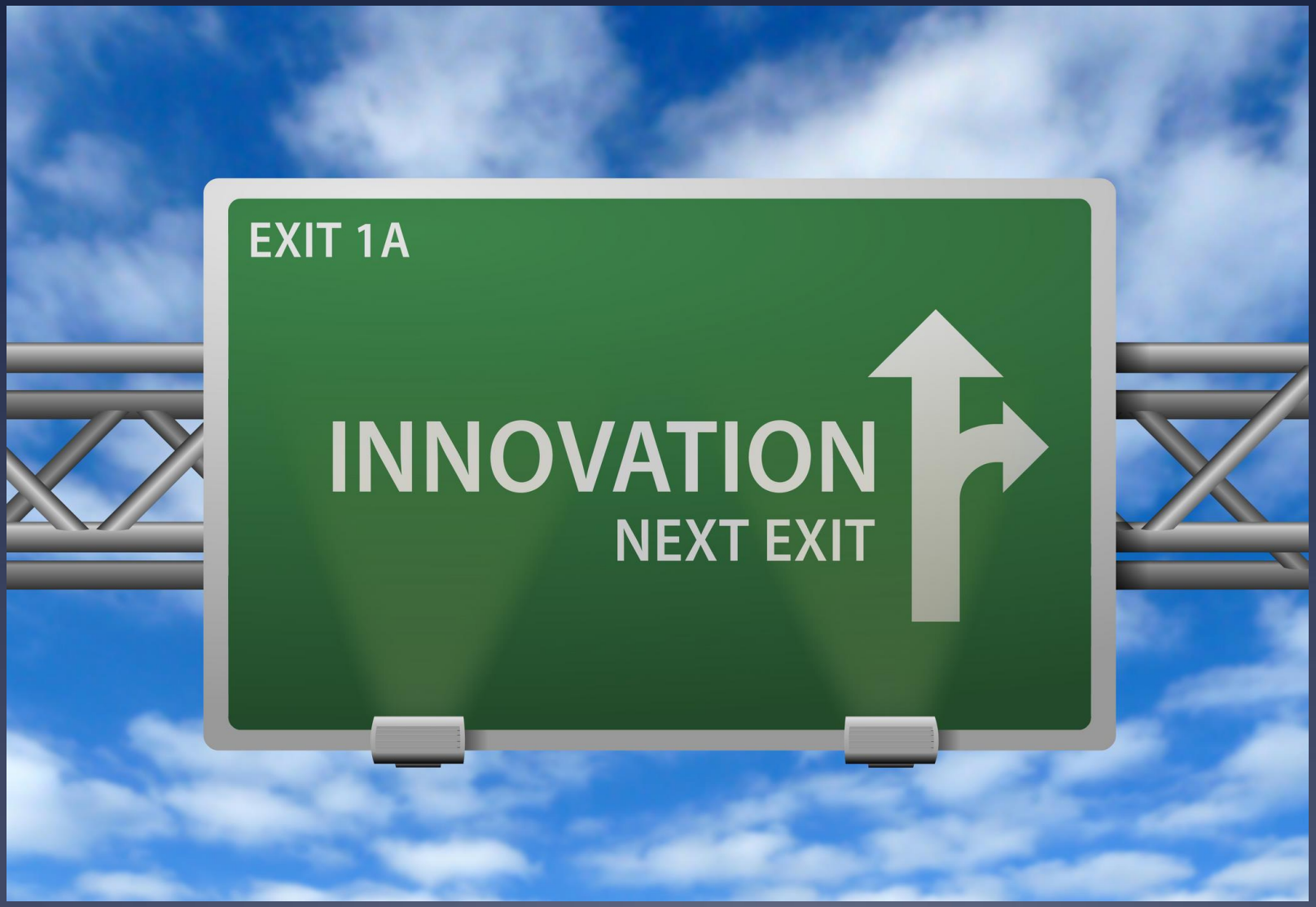

Transapical Branched Arch

- Percutaneous transapical access
- Single internal branch arch endograft
- 8 domestic pigs

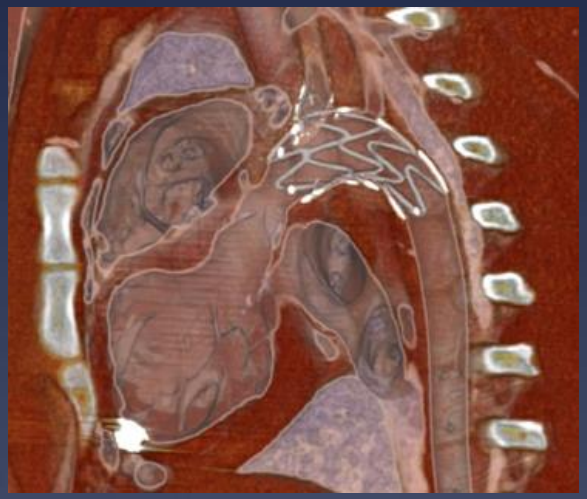

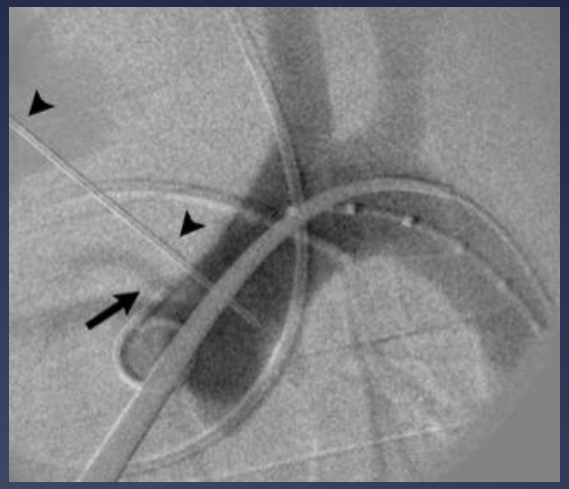

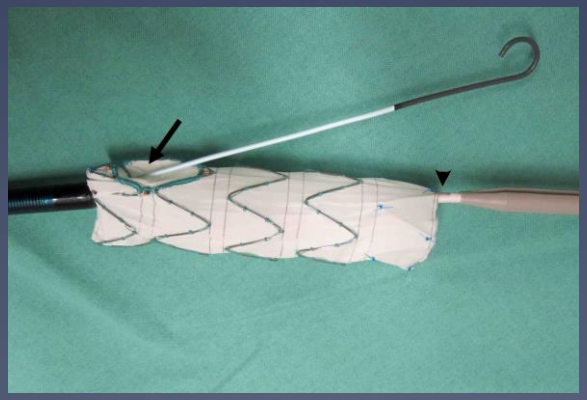

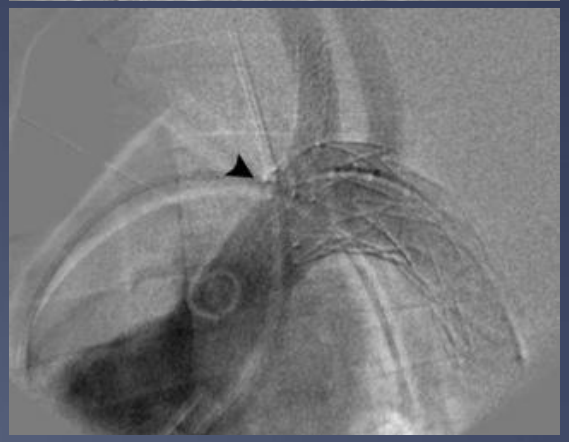

Wipper et al. 2016; J Endovasc Ther 23:493-500

Methods

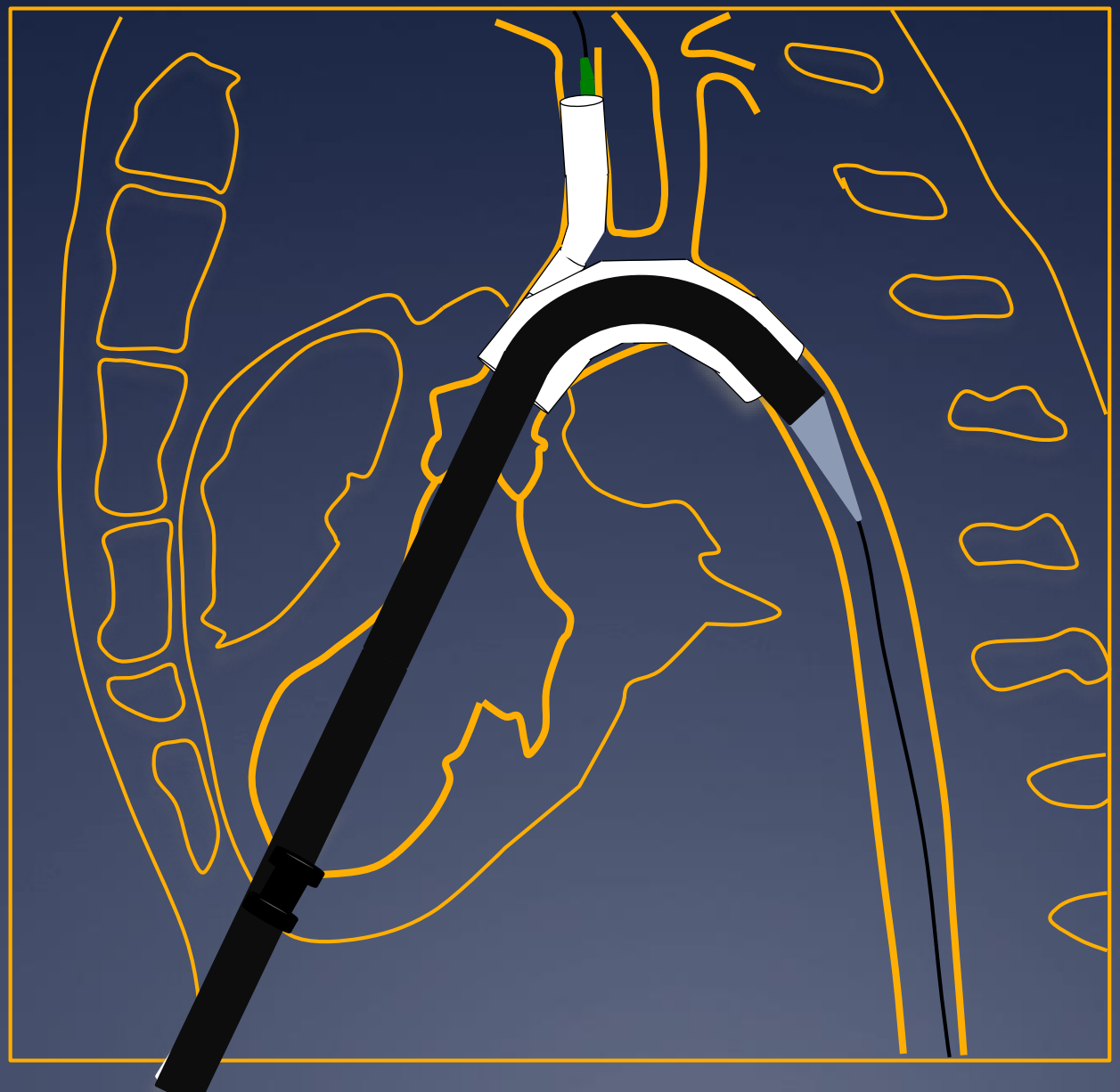

German Aortic Center

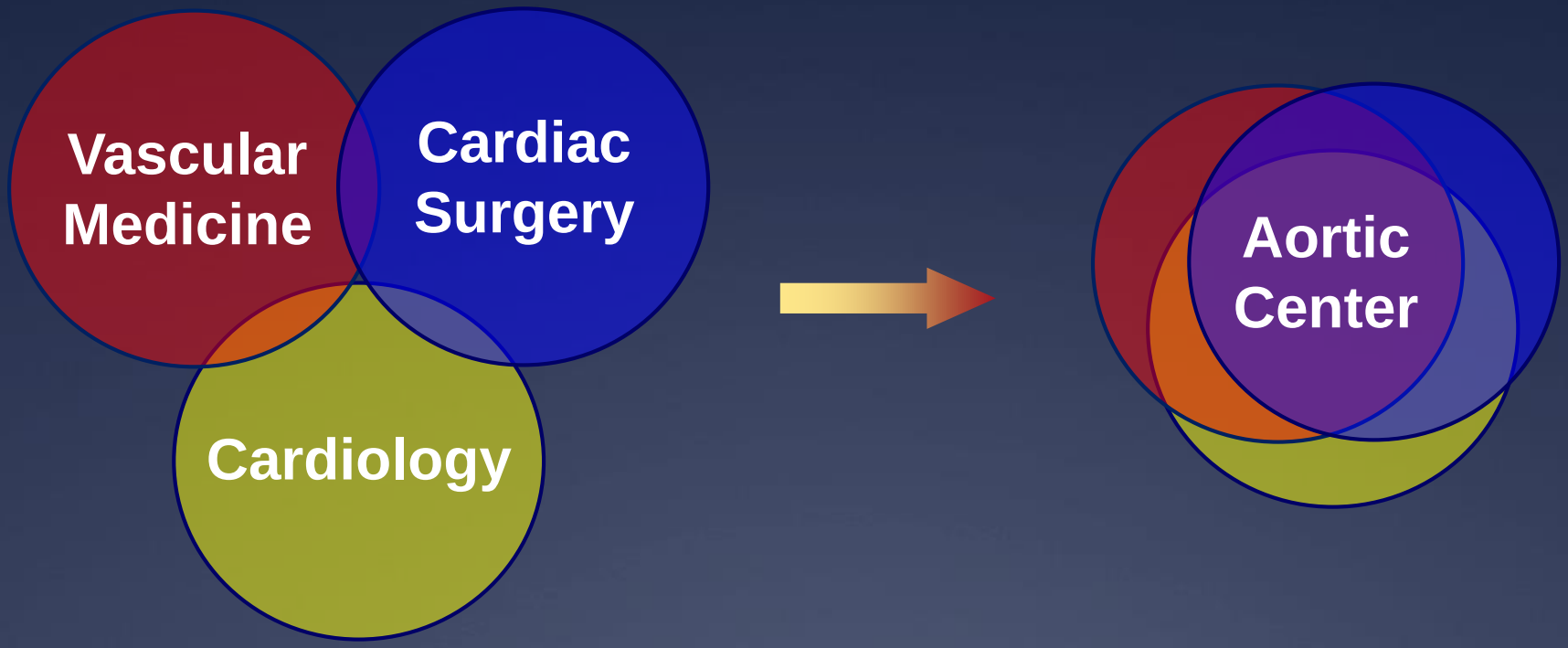

Conclusion

- Branched arch grafts feasible for high-risk patients.
- Peri-operative morbidity and mortality acceptable.
- Innovative new technique under investigation.
- Limited evidence and significant learning curve.
- Techniques in the aortic arch complementary not competing.
- Build an Aortic Center for cooperation!