

Descending aorta – transapical approach

K. Tsagakis

Department of Thoracic and Cardiovascular Surgery

West German Heart and Vascular Center

University Hospital Essen, Germany

Disclosure

Speaker name:

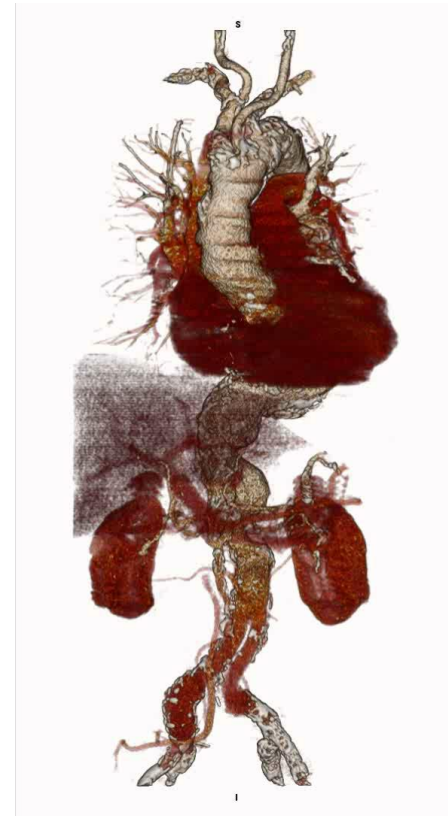
Konstantinos Tsagakis, MD

I have the following potential conflicts of interest to report:

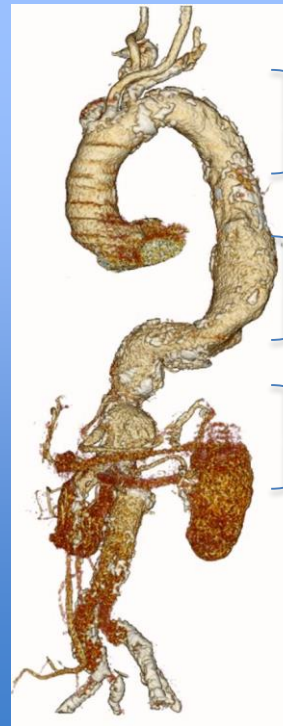
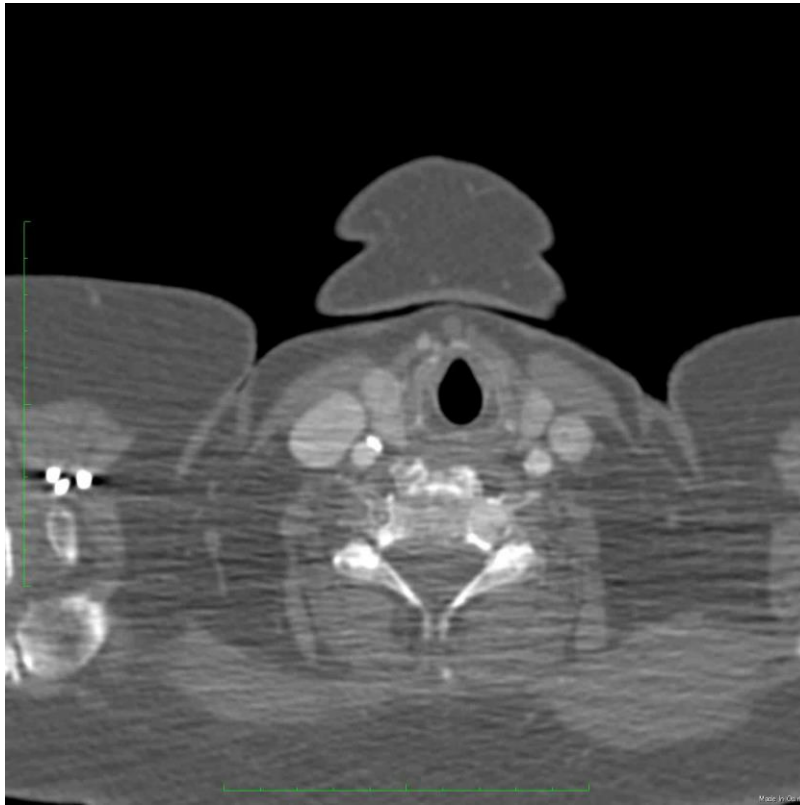
- ☐ Consulting to Jotec GmbH
 - ☐ Employment in industry
 - ☐ Stockholder of a healthcare company
 - ☐ Owner of a healthcare company
 - ☐ Other(s)
-
- ☐ I do not have any potential conflict of interest

TA-TEVAR – Case Demonstration

- 76yrs, female
- Symptomatic TAAA 6cm, acute IMH
- Peripheral artery disease
 - Y-Prosthesis (AAA)
 - RIA+LIA stenting
 - Fem-pop. bypass
- COPD



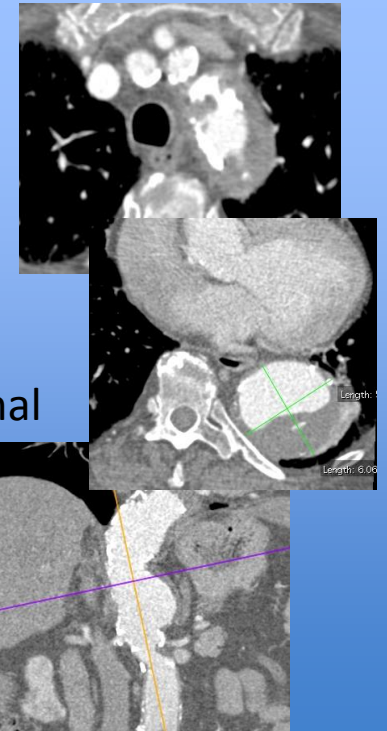
TA-TEVAR – Case Demonstration



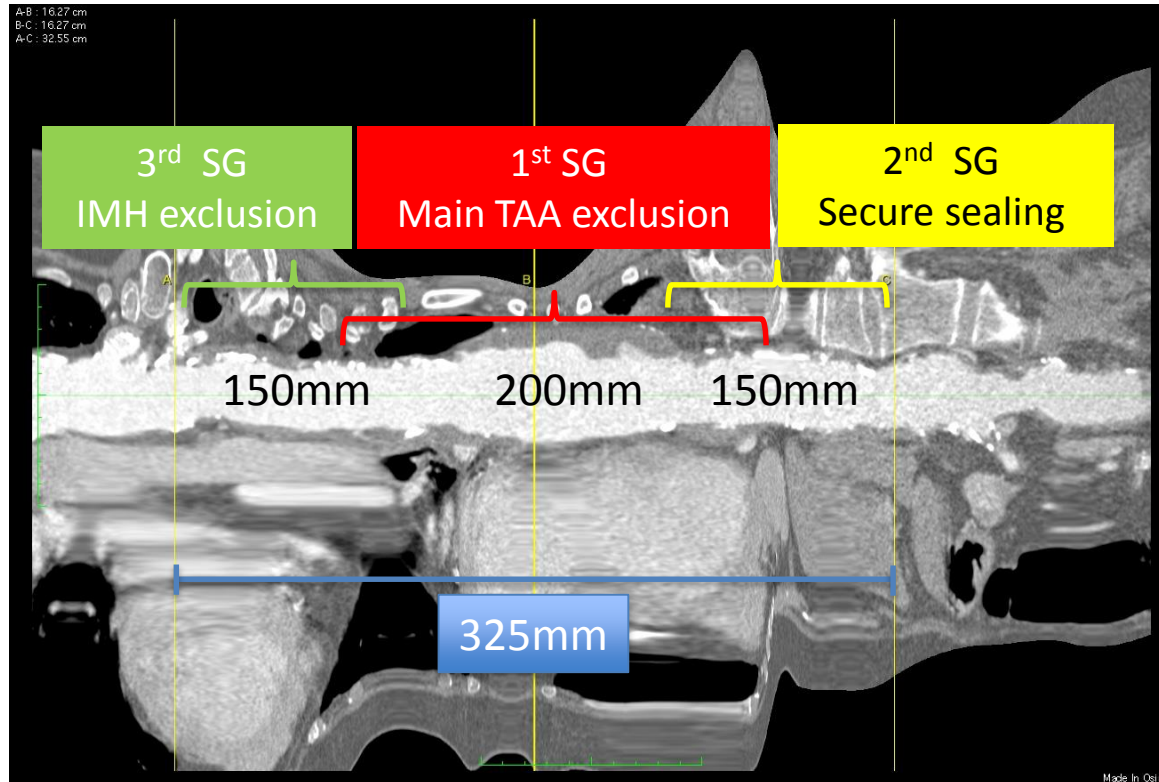
IMH

6cm Ø

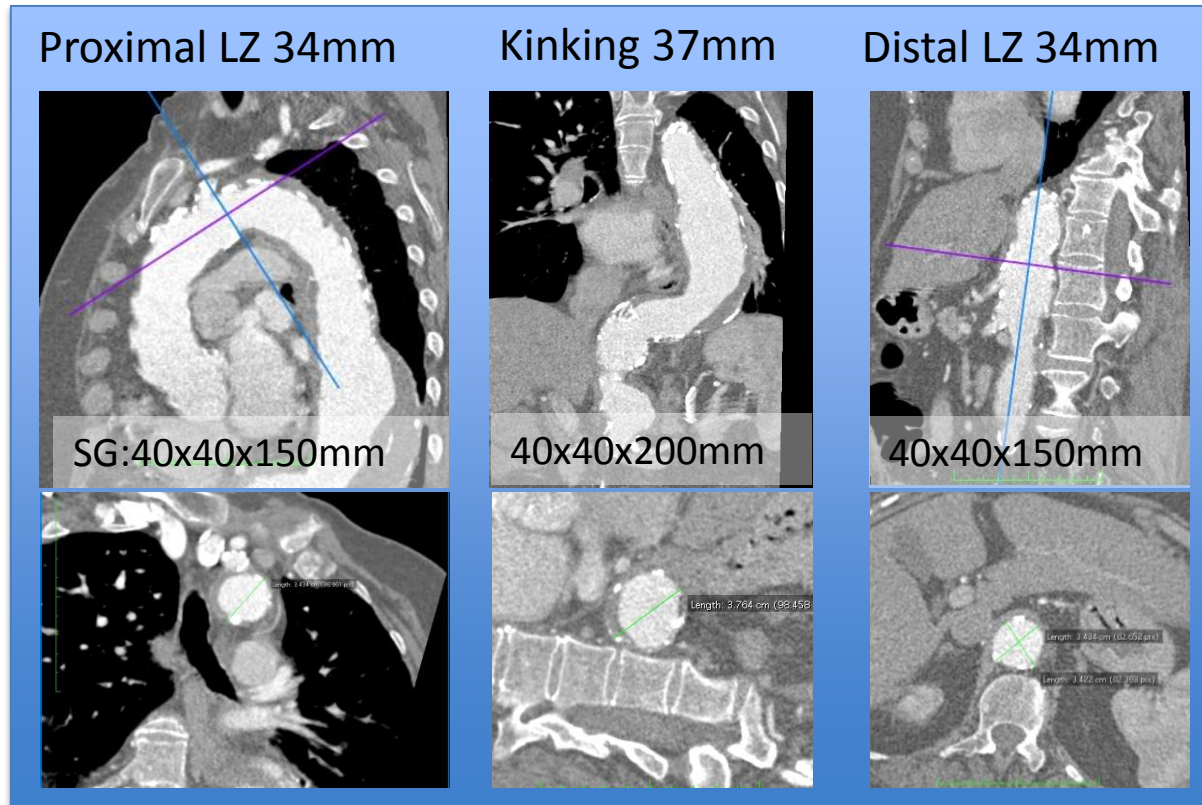
Suprarenal
AAA



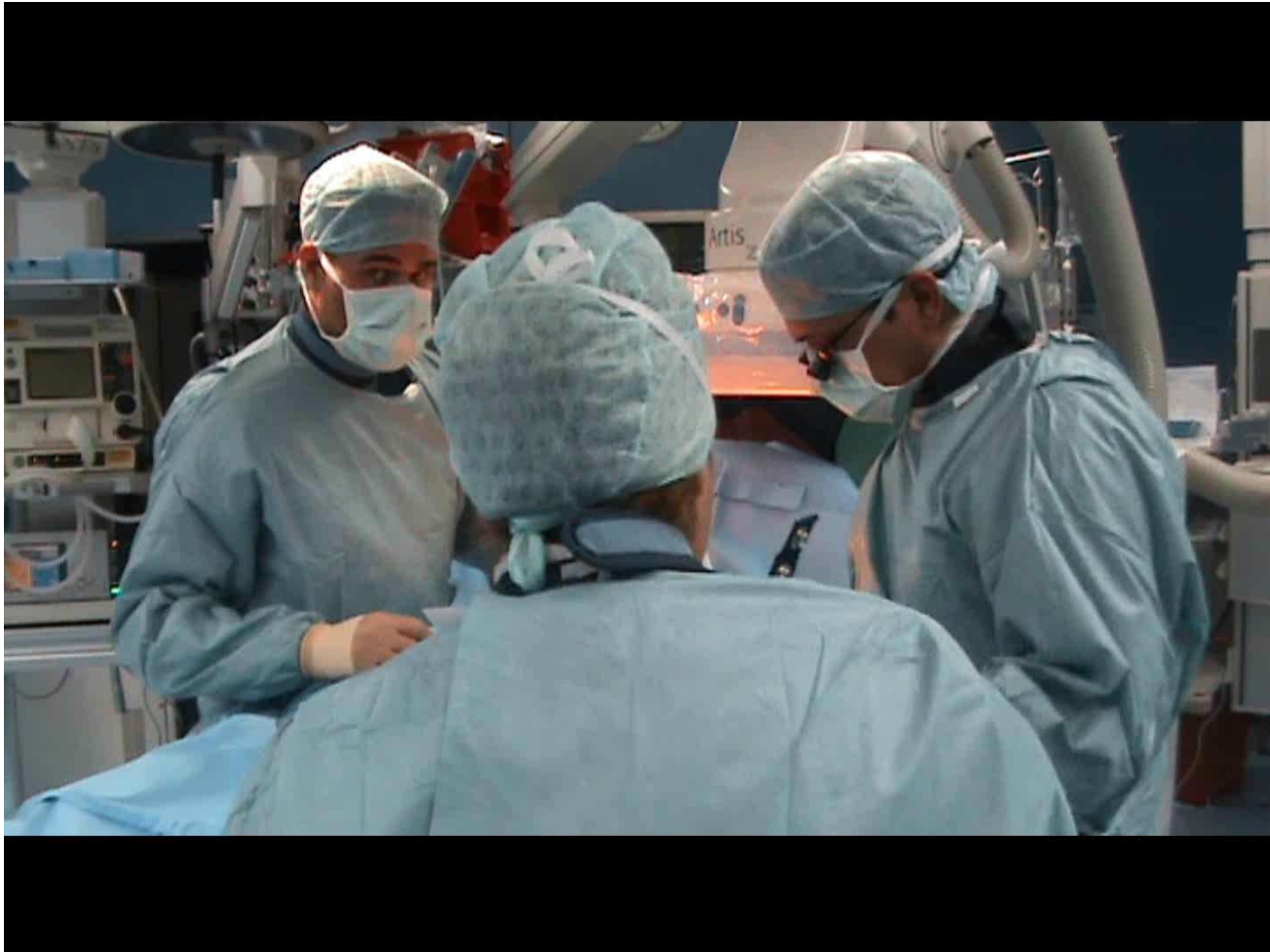TA-TEVAR – Case Demonstration



TA-TEVAR – Case Demonstration



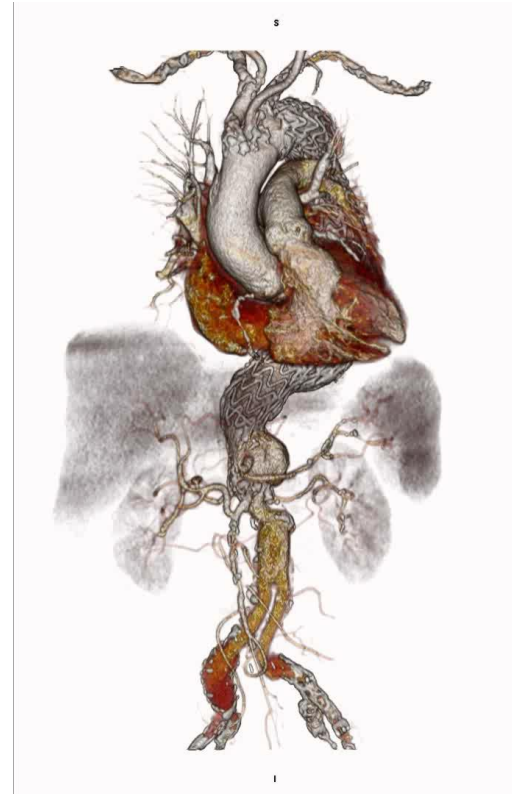
TA-TEVAR – Case Demonstration



TA-TEVAR – Case Demonstration

Since April 2016

TA-TEVAR	N =2
Mortality	-
Stroke	-
Transient paraparesis [recovery after CFS-D]	1



TA-TEVAR – Case Demonstration

Case 1

76yrs, female

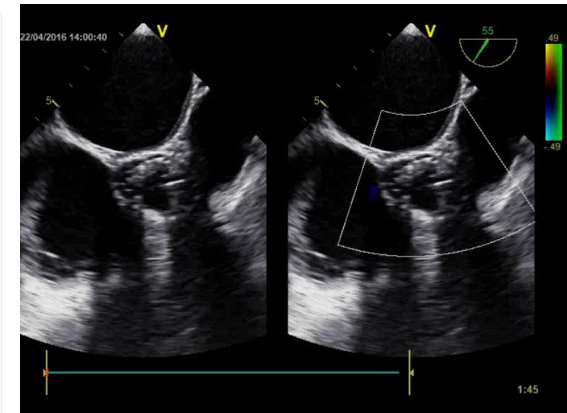
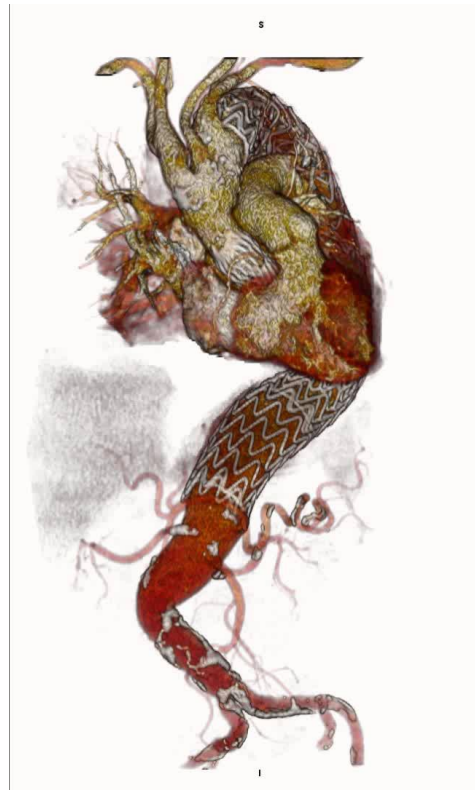
St/p Asc+Arch replac.

St/p TF-TAVI

St/p 2xTEVAR

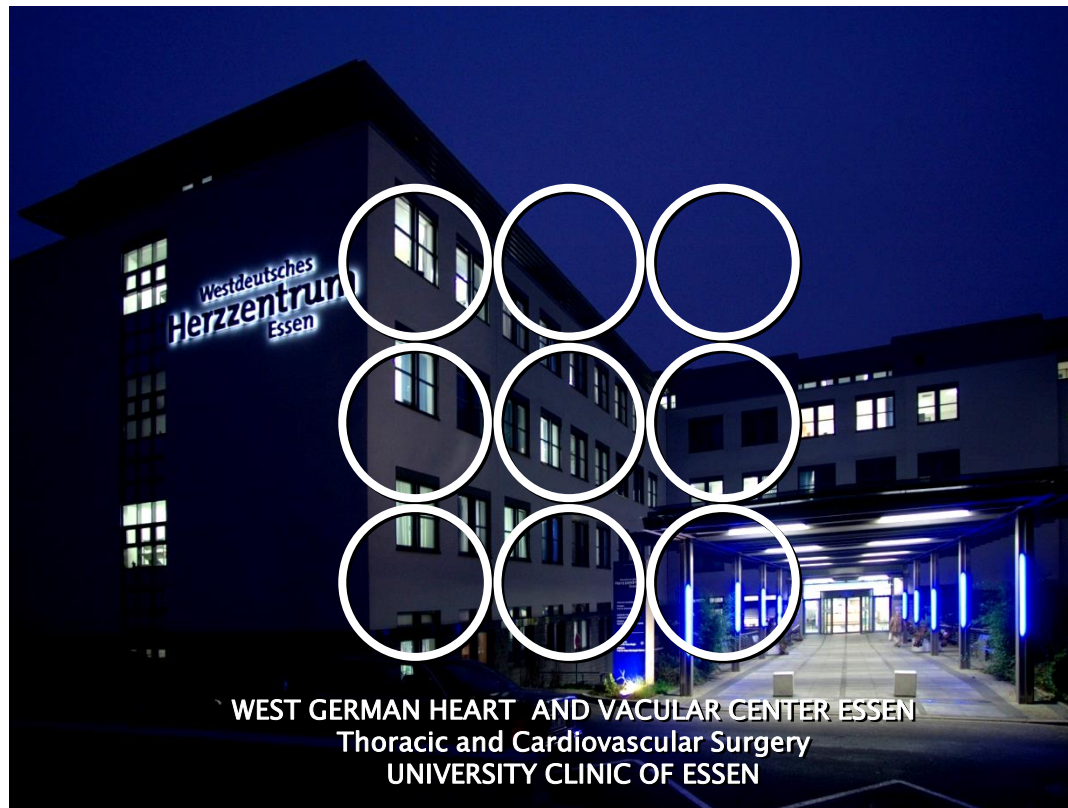
New findings:

Ia+Ib endoleak



TA- TEVAR

2x GoreTAG SG 45x45mm
to exclude the proximal
and distal endoleak



konstantinos.tsagakis@uk-essen.de