Niels-Stensen-Kliniken
Marienhospital Osnabrück

Sustaining hypogastric flow - preserving pelvic functionality

Jörg Heckenkamp

Niels-Stensen-Kliniken, Marienhospital Osnabrück

Zentrum für Gefäßmedizin, Klinik für Gefäßchirurgie

Niels-Stensen-Kliniken
Marienhospital Osnabrück

(Aorto-) Iliac Artery Aneurysms

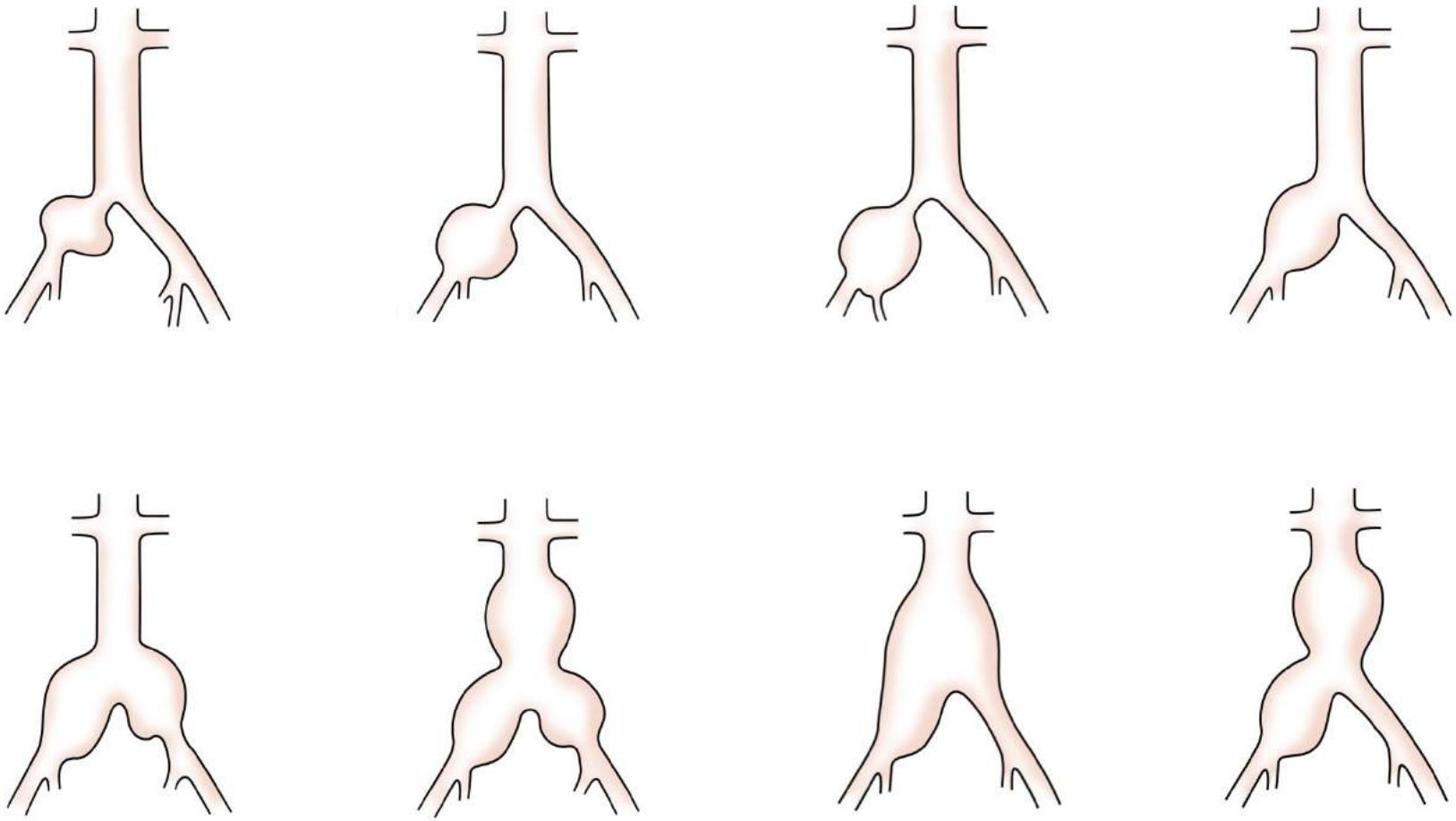

Niels-Stensen-Kliniken
Marienhospital Osnabrück

Basic Measurements

Country: Germany
City: Osnabrück
Hospital: Marienhospital
Doctor: Prof. Heckenkamp
Initials: P.H.
Birthday: 17.09.1928

E-xtra DESIGN ENGINEERING

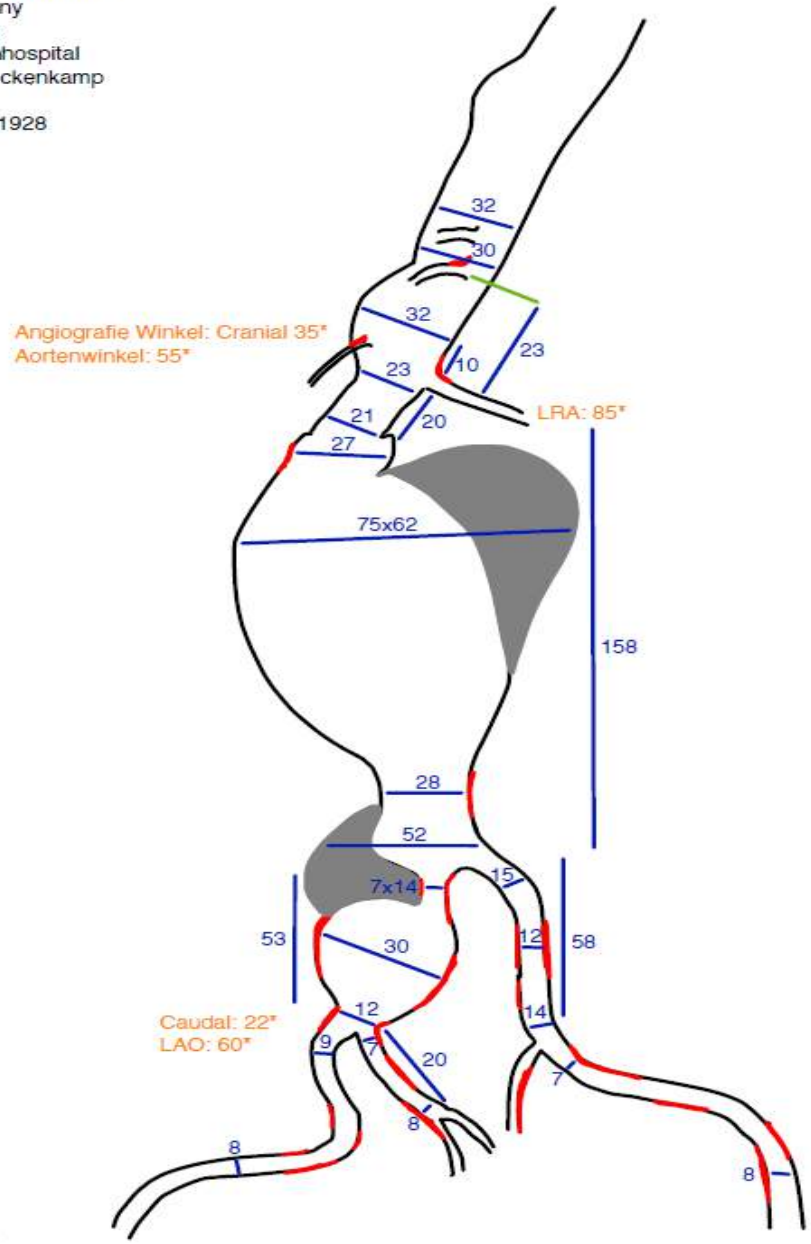

JOTEC GmbH, E-xtra Design Engineering,
Lotzenäcker 23, 72379 Hechingen, Tel. 07471922301, Fax 07471922101

Niels-Stensen-Kliniken
Marienhospital Osnabrück

Aorto-Iliac Artery Aneurysm Management

Open Surgical Repair

- Complications include: [1,2]
  - Higher early (30 day) morbidity / mortality
  - Increased surgical time
  - Increased blood loss
  - Longer hospital stay
  - Longer Intensive Care Unit stay

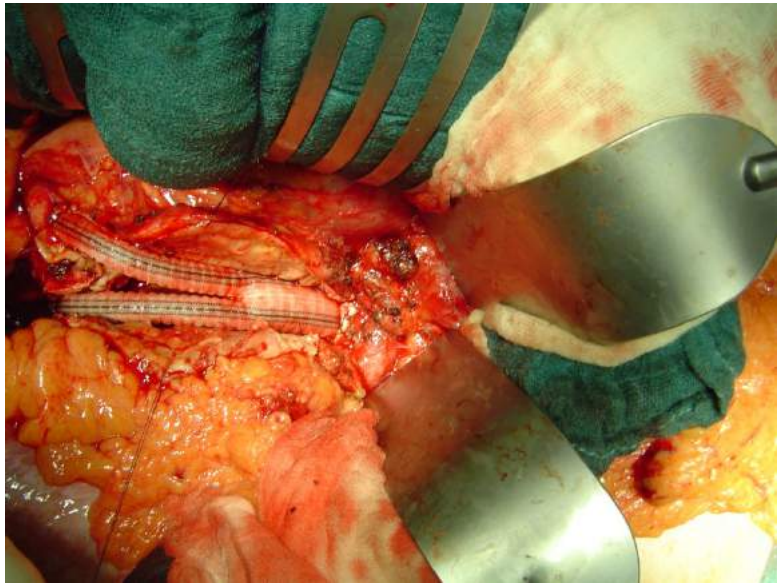

Hay-day for open aortic surgery is over, Charing Cross, 2015

1. Stather PW. Systematic review and meta-analysis of the early and lateoutcomes of open and endovascular repair of abdominal aortic aneurysm. *British Journal of Surgery 2013;100(7):863-872.*
2. Lederle FA. *Open Versus Endovascular Repair (OVER) Veterans Affairs Cooperative Study Group. Outcomes following endovascular vs open repair of abdominal aortic aneurysm. A randomized trial. Journal of the American Medical Association 2009;302(14):1535-1542.*

Niels-Stensen-Kliniken
Marienhospital Osnabrück

Aorto-Iliac Artery Aneurysm Management

First Experiences with Coil-and-Cover

- Occlude internal iliac artery and cover with endograft sealing in the external iliac artery
- Complications include:
  - Severe morbidity (including colonic ischemia) and even mortality [1]
  - Buttock claudication rates of 50% with persistence rates of 33% [2,3]
  - Sexual dysfunction rates of 20% [2,3]

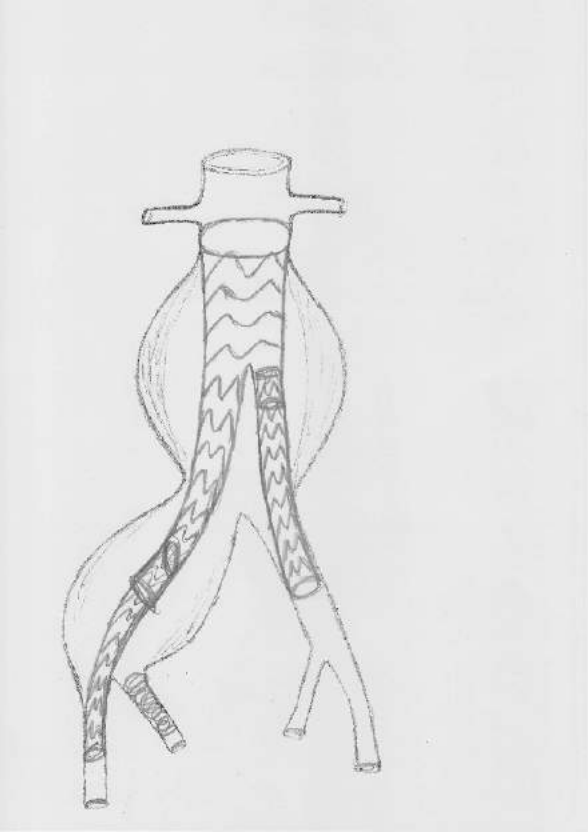

Verzini F. Endovascular treatment of iliac aneurysm: concurrent comparison of side branch endograft versus hypogastric exclusion. *Journal of Vascular Surgery 2009;49(5):1154-1161.*

Farahmand P. Is hypogastric artery embolization during endovascular aortoiliac aneurysm repair (EVAR) innocuous and useful? European *Journal of Vascular Endovascular Surgery 2008;35(4):429-435.*

Rayt HS. Buttock claudication and erectile dysfunctionafter internal iliac artery embolization. *Cardiovasc Intervent Radiol 2008;13:728-734*

Niels-Stensen-Kliniken
Marienhospital Osnabrück

Sandwich, Chimney, Periscope Technique

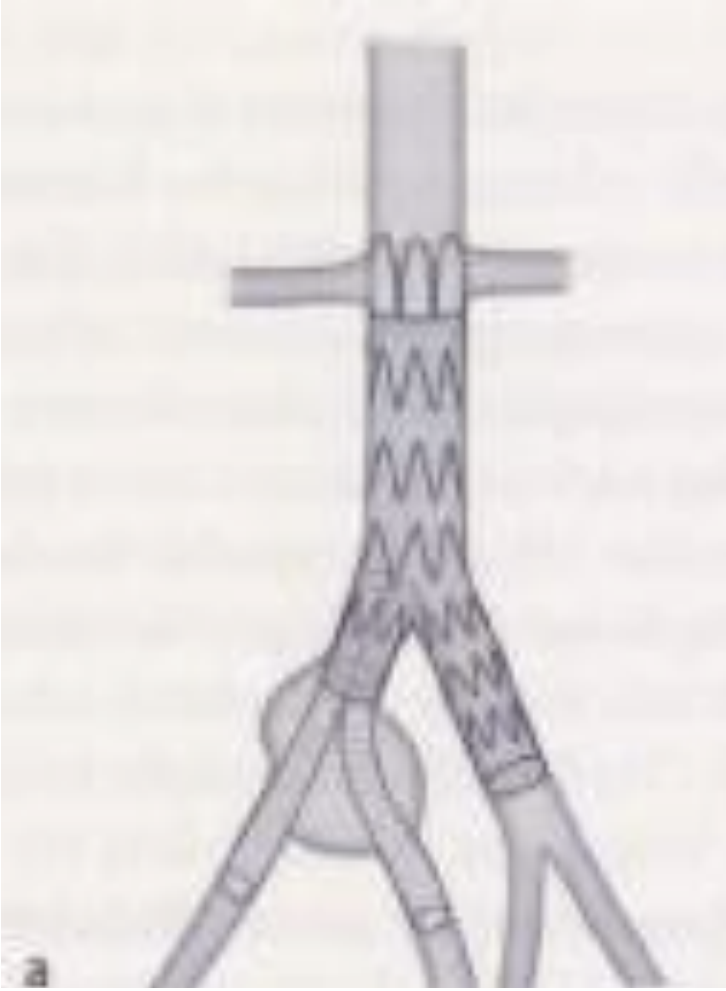

Novel chimney-graft technique for preserving hypogastric flow in complex aortoiliac aneurysms

Heckenkamp J. [1], Brunkwall J. [2], Luebke T. [2], Aleksic M. [3], Schöndube F. [4], Stojanovic T. [4]

J Cardiovsc Surg, 2012

[1] Department of Vascular Surgery, Niels-Stensen-Hospital, Osnabrueck, Germany;

Niels-Stensen-Kliniken
Marienhospital Osnabrück

Iliac Aneurysm Management (Periscope)

***Off* Label Endovascular Techniques**

- Endovascular repair using parallel stent-grafting
- Complications include: [1,2]

– No specific testing / long-term follow up

– Potential compression of parallel grafts, Endoleak

– Requires brachial / axillary access

Useful after Aorto-biiliac Endograft

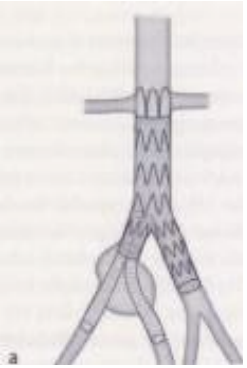

1. Fatima J. Pelvic revascularization during endovascular aortic aneurysm repair. *Perspectives in Vascular Surgery & Endovascular Therapy 2012;24(2):55-62.*
2. Lobato AC. The sandwich technique to treat complex aortoiliac or isolated iliac aneurysms: results of midterm follow-up. *Journal of Vascular Surgery 2013;57(2)Supplement:26S-34S.*

Niels-Stensen-Kliniken
Marienhospital Osnabrück

Bell Bottom, Flare Technique

- Increased sec. Interventions[1]
  - Aneurysm Progression
  - Type Ib Endoleak

Eur J Vasc Endovasc Surg (2017) 54, 170–176

EVAR with Flared Iliac Limbs has a High Risk of Late Type 1b Endoleak

D. Gray, R. Shahverdyan [1], V. Reifferscheid [2], M. Gawenda, J.S. Brunkwall *

Clinic of Vascular and Endovascular Surgery, University Hospital of Cologne, Kerpener Str. 62, 50937 Cologne, Germany

1:Torsello G et al. Endovascular treatment of common iliac artery aneurysms using the bell-bottom technique. *J Endovasc Ther*;2008:14,625

Niels-Stensen-Kliniken
Marienhospital Osnabrück

EVAS (Common Iliac Aneurysms)

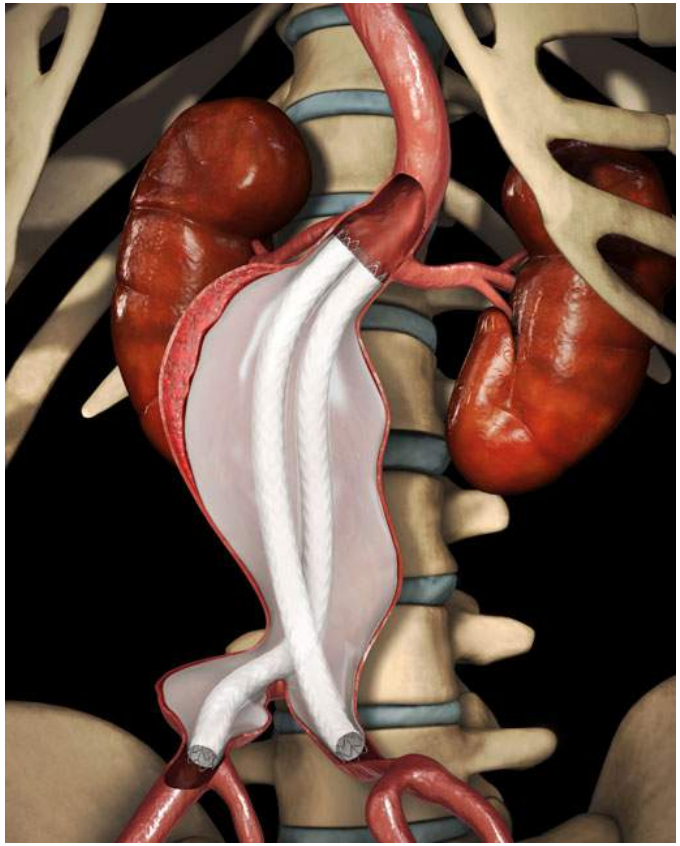

J Vasc Surg. 2016 Nov;64:1262-1269
Preservation of hypogastric flow and control of iliac aneurysm size in the treatment of aortoiliac aneurysms using the Nellix EndoVascular Aneurysm Sealing endograft.
Krievins DK[1], Savlovskis J[2], Holden AH[3], Kisis K[4], Hill AA[5], Gedins M[4], Ezite N[2], Zarins CK[6].

EVAS was effective with preservation of internal iliac patency in most cases. Complete CIA exclusion prevented aneurysm enlargement over time, whereas partial exclusion did not prevent continued CIA enlargement, particularly in larger aneurysms. Distal sealing up to 35 mm

Niels-Stensen-Kliniken
Marienhospital Osnabrück

Side Branch Technology

E-liac®

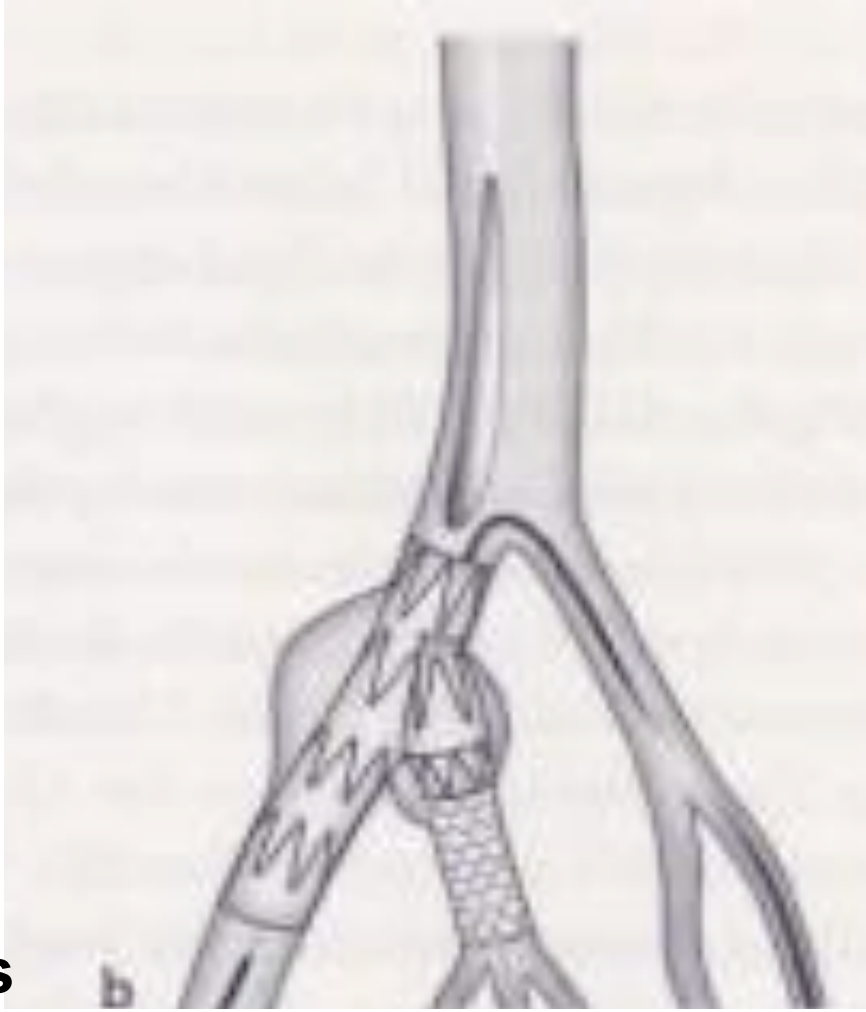

Authorized for:
Aorto-Iliac Aneurysms
Isolated Iliac Aneurysms

Niels-Stensen-Kliniken
Marienhospital Osnabrück

Design E-liac®

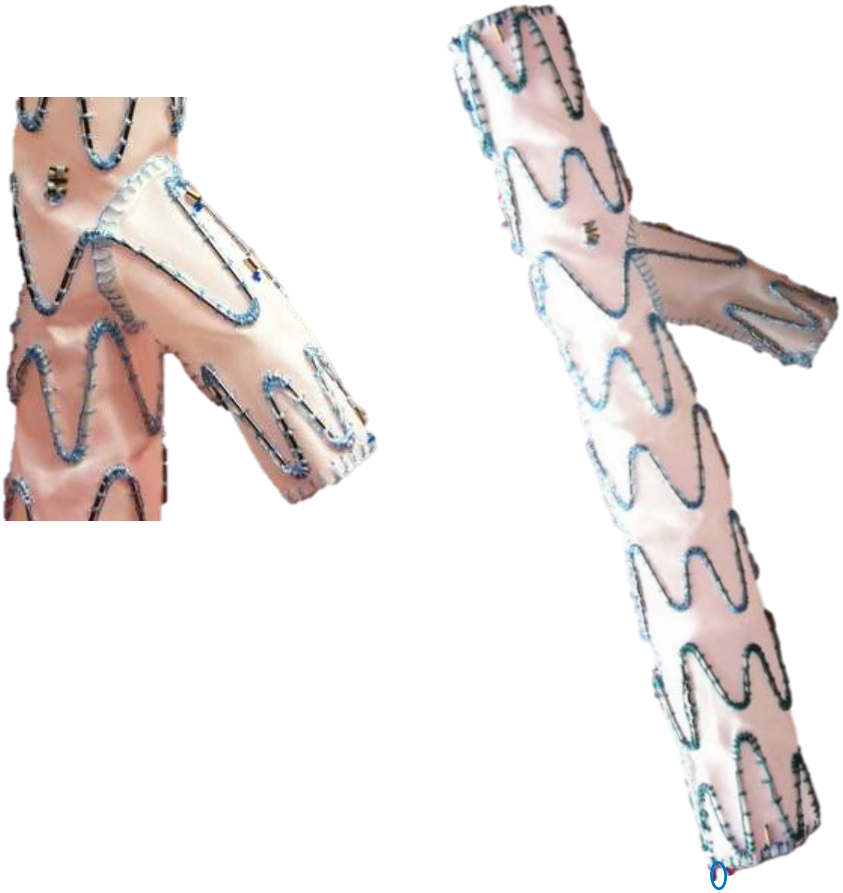



Niels-Stensen-Kliniken
Marienhospital Osnabrück

Design E-liac®

Niels-Stensen-Kliniken
Marienhospital Osnabrück

Implant Design

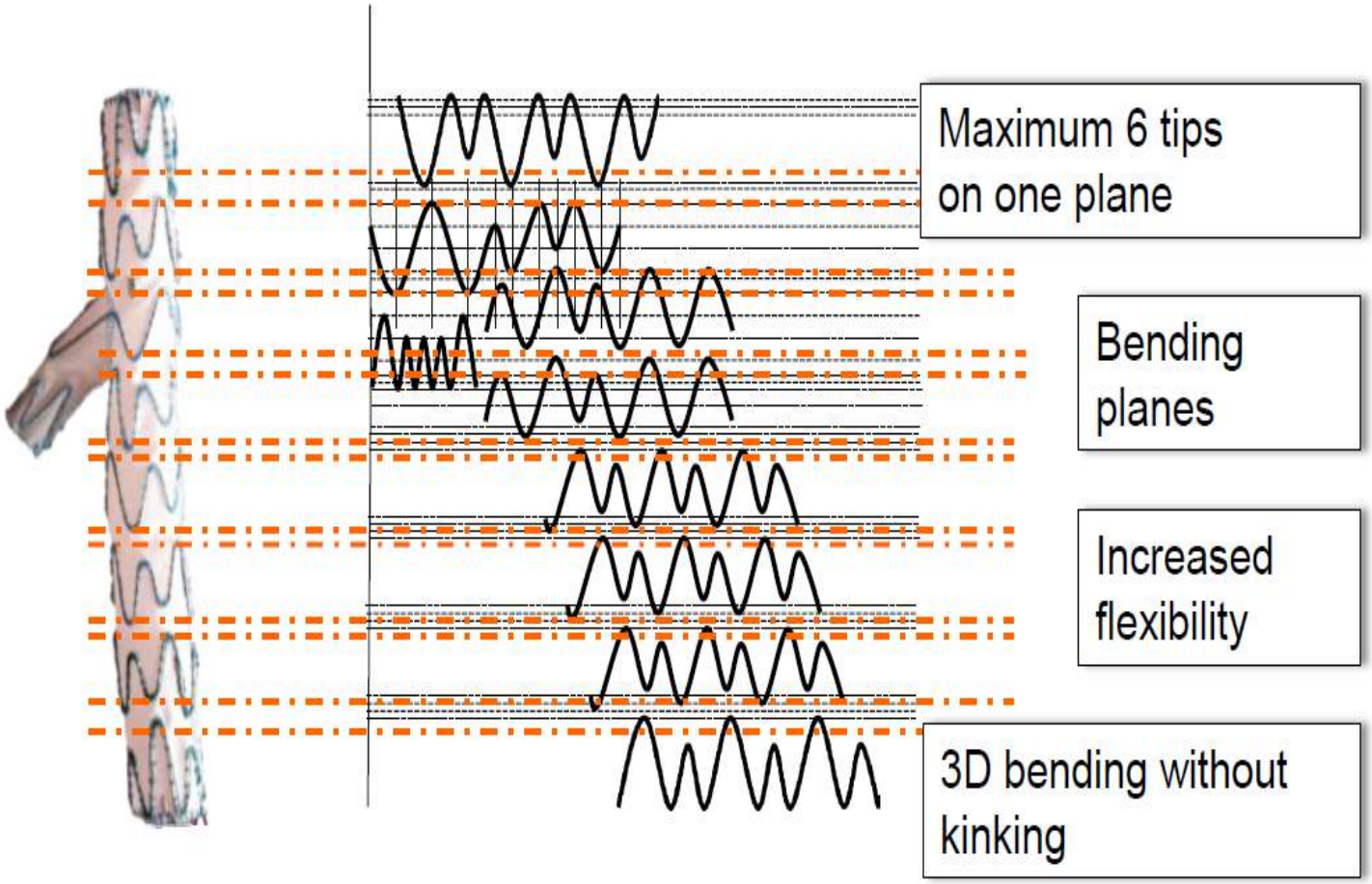

Niels-Stensen-Kliniken
Marienhospital Osnabrück

Symmetric stent design

Asymmetric stent design

Niels-Stensen-Kliniken
Marienhospital Osnabrück

Implant Design E-liac®

- Asymetric spring design
  → High flexibility
- Increase of radial force
- Deployment of side branch by the use of a special shaped bifurcation spring
- Spring within Side Branch → Compression spring for a better anchoring of covered stent

Niels-Stensen-Kliniken
Marienhospital Osnabrück

Implant Design

Positioning of radiopaque marker:

- Tubes indicate endings of prosthesis
- Tubes on Branch indicate distal positioning
- E (3)-Marker shows the orientation and beginning of side branch

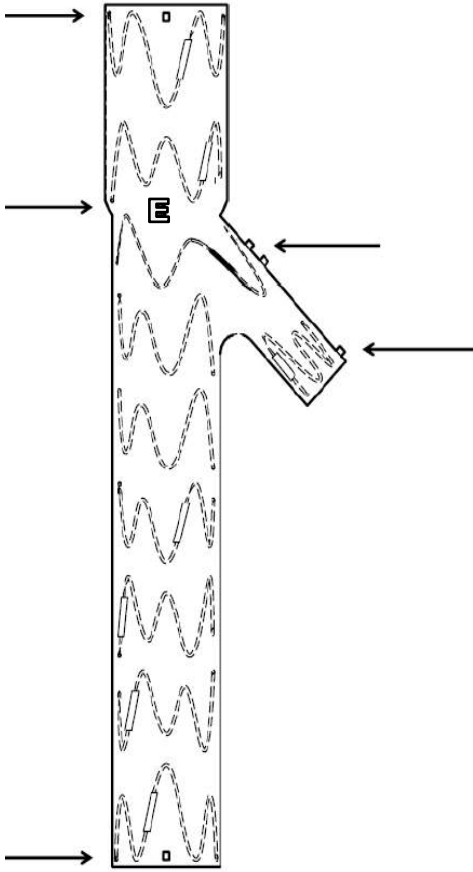

Niels-Stensen-Kliniken
Marienhospital Osnabrück

Implant Design

Positioning of radiopaque marker:

- E-Marker indicates branch orientation → Depending on implantation side the E-Marker appears as an E or as a 3

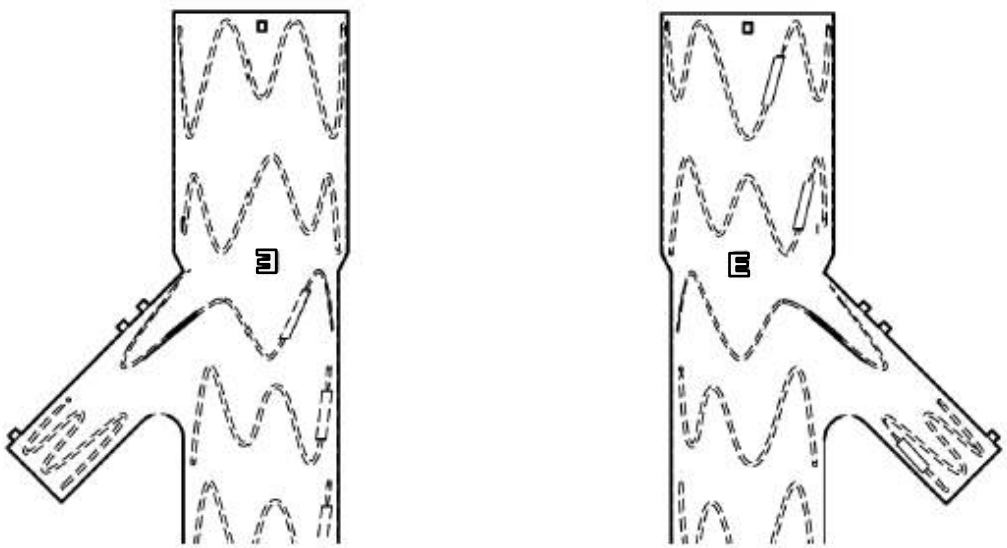

Niels-Stensen-Kliniken
Marienhospital Osnabrück

Niels-Stensen-Kliniken
Marienhospital Osnabrück

Instructions for use E-liac

- Unilateral or bilateral aorto-iliac or iliac aneurysm
- Access vessel morphology compatible with the **18F (6mm OD)** delivery system
- Non-aneurysmal CIA landing area in case of iliac artery aneurysm **≥ 20mm**
- Diameter of the CIA in the proximal landing area: **12mm to 17mm**
- Non-aneurysmal EIA segment distal to the aneurysm **≥ 15mm**
- Diameter of the EIA in the distal landing area: **8mm to 13mm**
- Non-aneurysmal IIA segment distal to the aneurysm **≥ 15mm**
- Angel between EIA and IIA **≤ 50°**
- Thrombus free iliac lumen in the area of iliac bifurcation **≥ 18mm**

Niels-Stensen-Kliniken
Marienhospital Osnabrück

Patient:

Male
Age: 77
Right Iliac Aneurysm, Diameter 44mm
TAA, Therapy with NOAK
Asymptomatic
17.09.2014: Exclusion: E-liac (72IB1814L53L44)
Eventus (91BX3710L)
Follow-up 10/14: No endoleak, Diameter: 37mm
Follow-up 10/16: No endoleak, Diameter: 33mm
Follow-up 10/17: No endoleak, Diameter: 30mm


H
R
40mm


H
R
40mm


H
R
40mm


H
R
40mm


H
R
40mm


H
R
40mm


H
R
40mm


H
R
40mm


H
R
40mm


H
R
40mm


H
R
40mm


H
R
40mm

17.09.2014

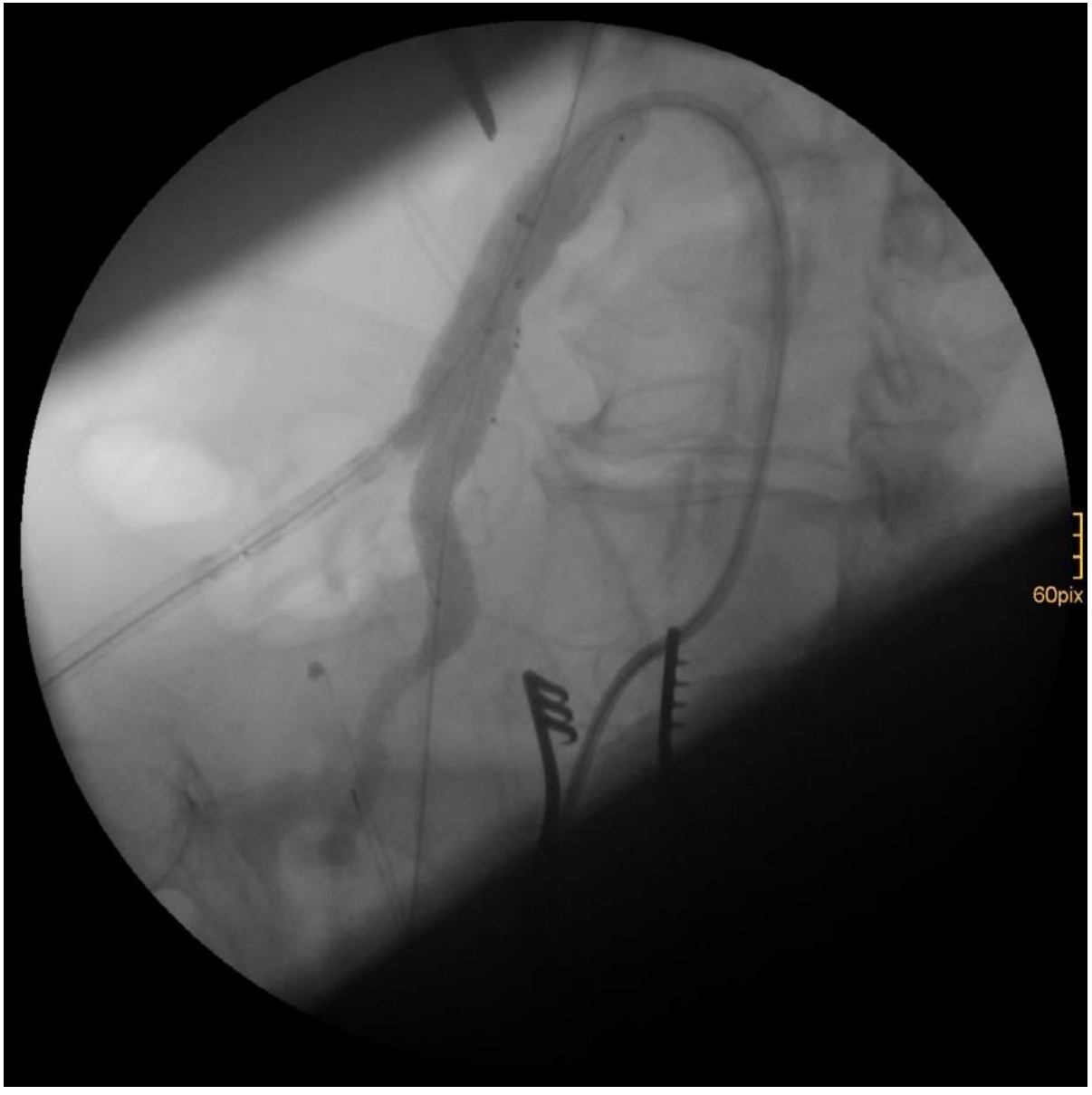

23.10.2014


A
R
20mm


A
R
20mm


A
R
20mm


A
R
20mm


A
R
20mm


A
R
20mm


A
R
20mm


A
R
20mm


A
R
20mm


A
R
20mm


A
R
20mm


A
R
20mm


A
R
20mm


A
R
20mm


A
R
20mm


A
R
20mm


A
R
20mm


A
R
20mm


A
R
20mm


A
R
20mm


A
R
20mm


A
R
20mm


A
R
20mm


A
R
20mm

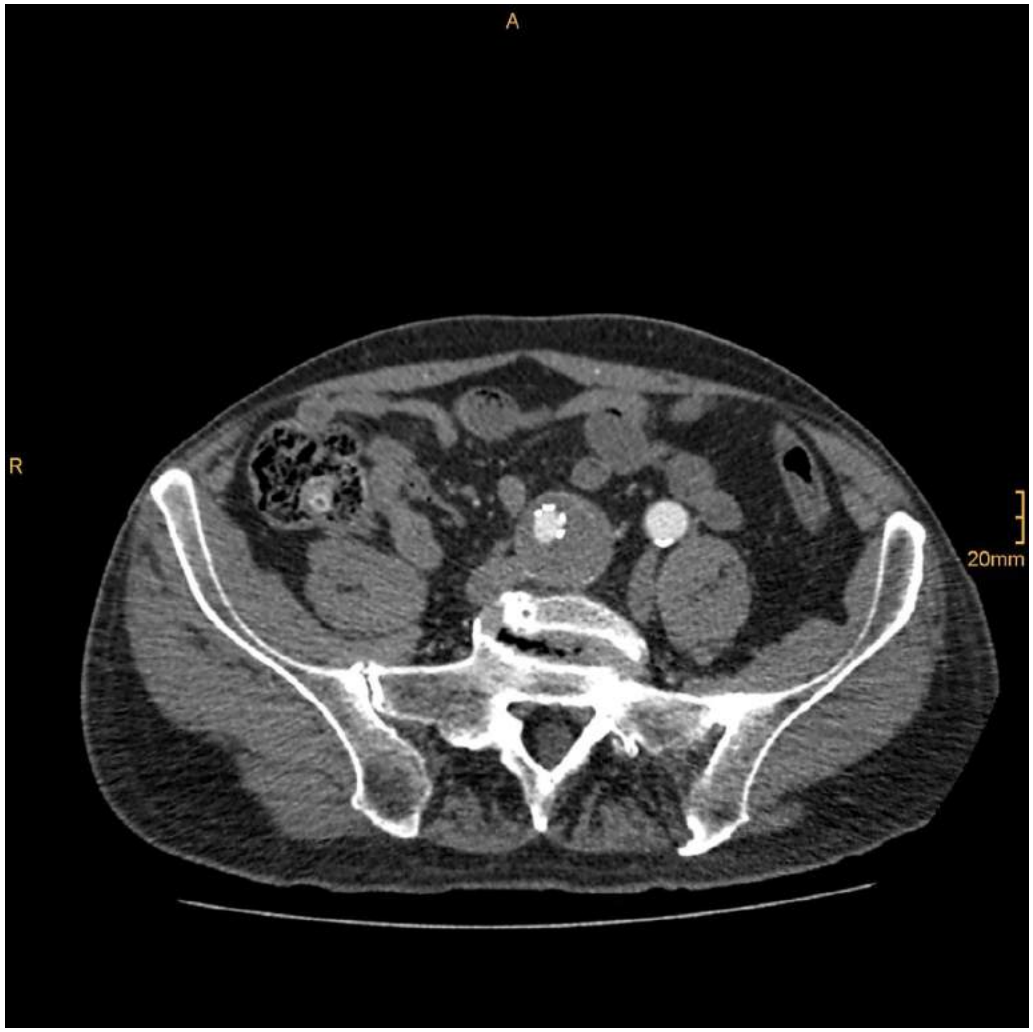
A
R
20mm


A
R
20mm


A
R
20mm


A
R
20mm


A
R
20mm

Diameter: 37mm


A
R
20mm

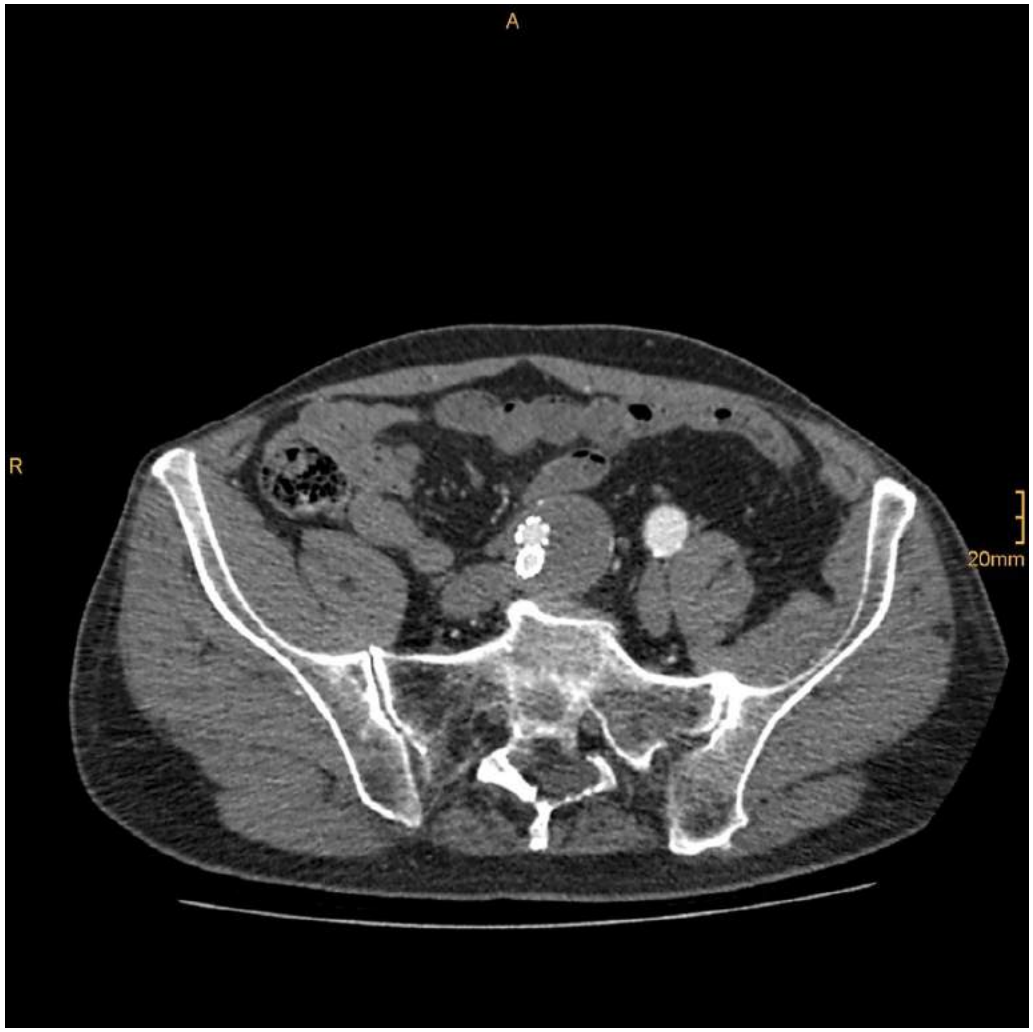
A
R
20mm


A
R
20mm


A
R
20mm


A
R
20mm


A
R
20mm

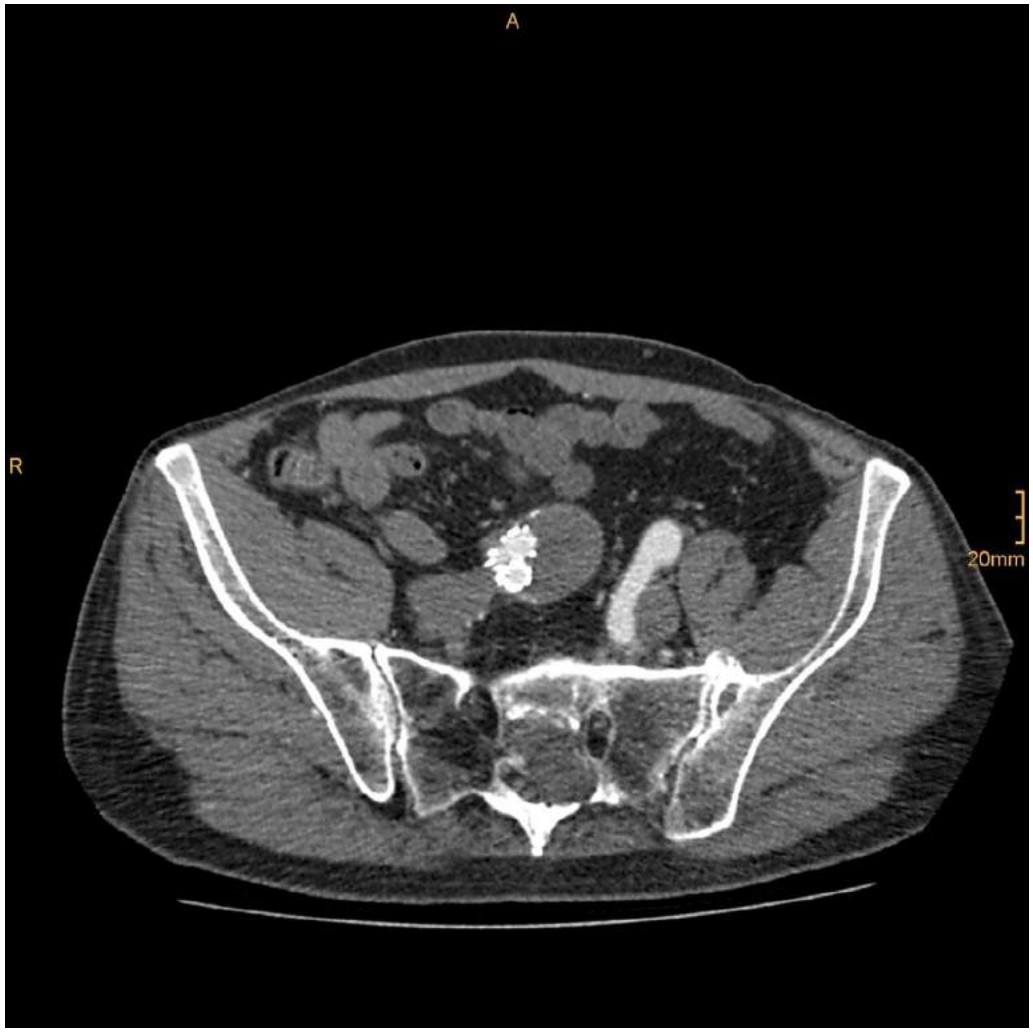
A
R
20mm

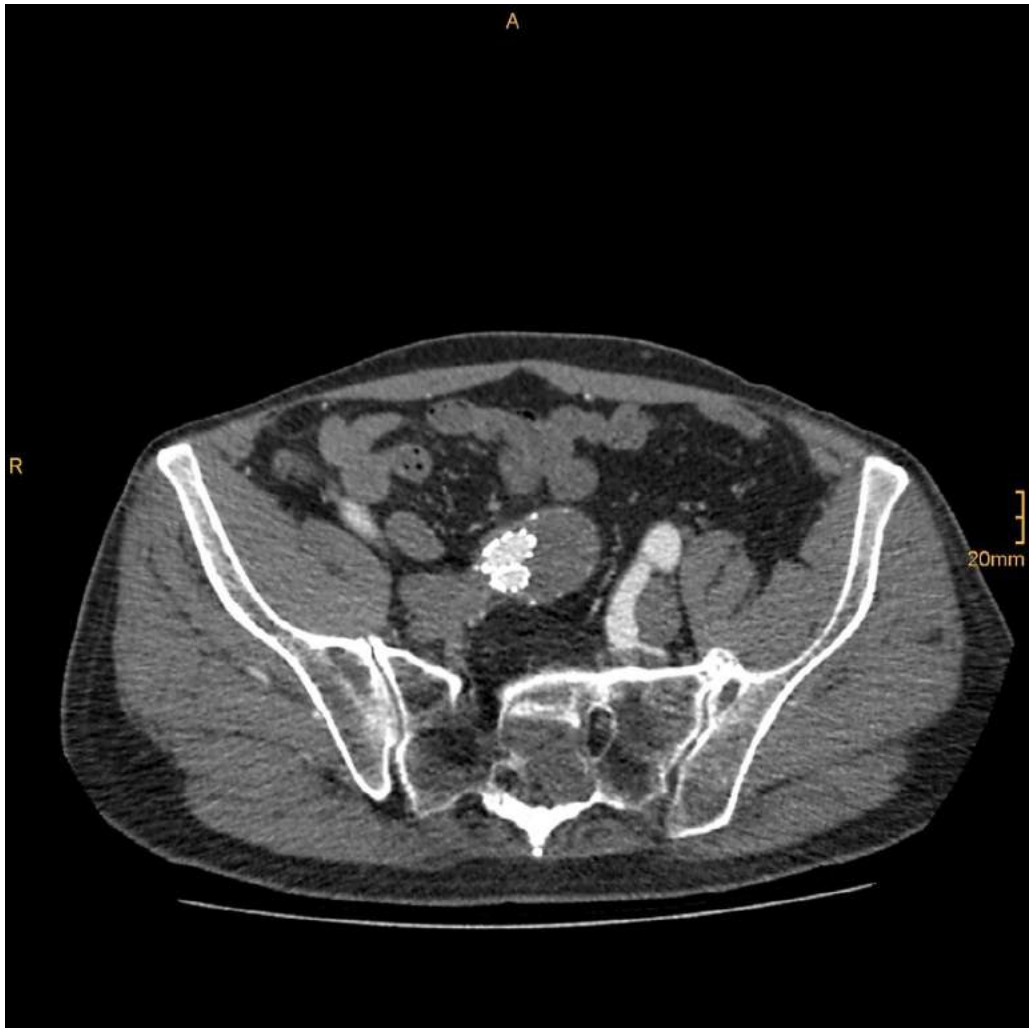
A
R
20mm


A
R
20mm


A
R
20mm


A
R
20mm


A
R
20mm


A
R
20mm


A
R
20mm


A
R
20mm

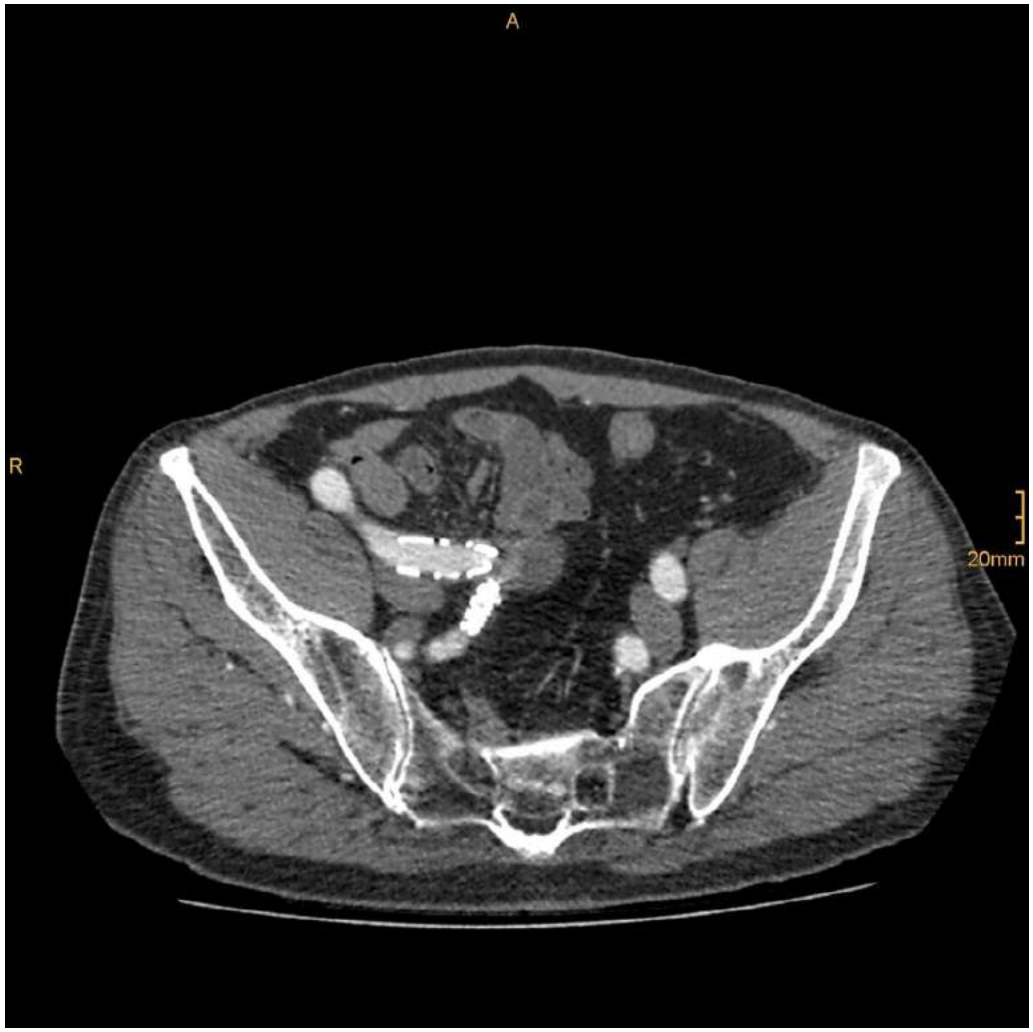
A
R
20mm

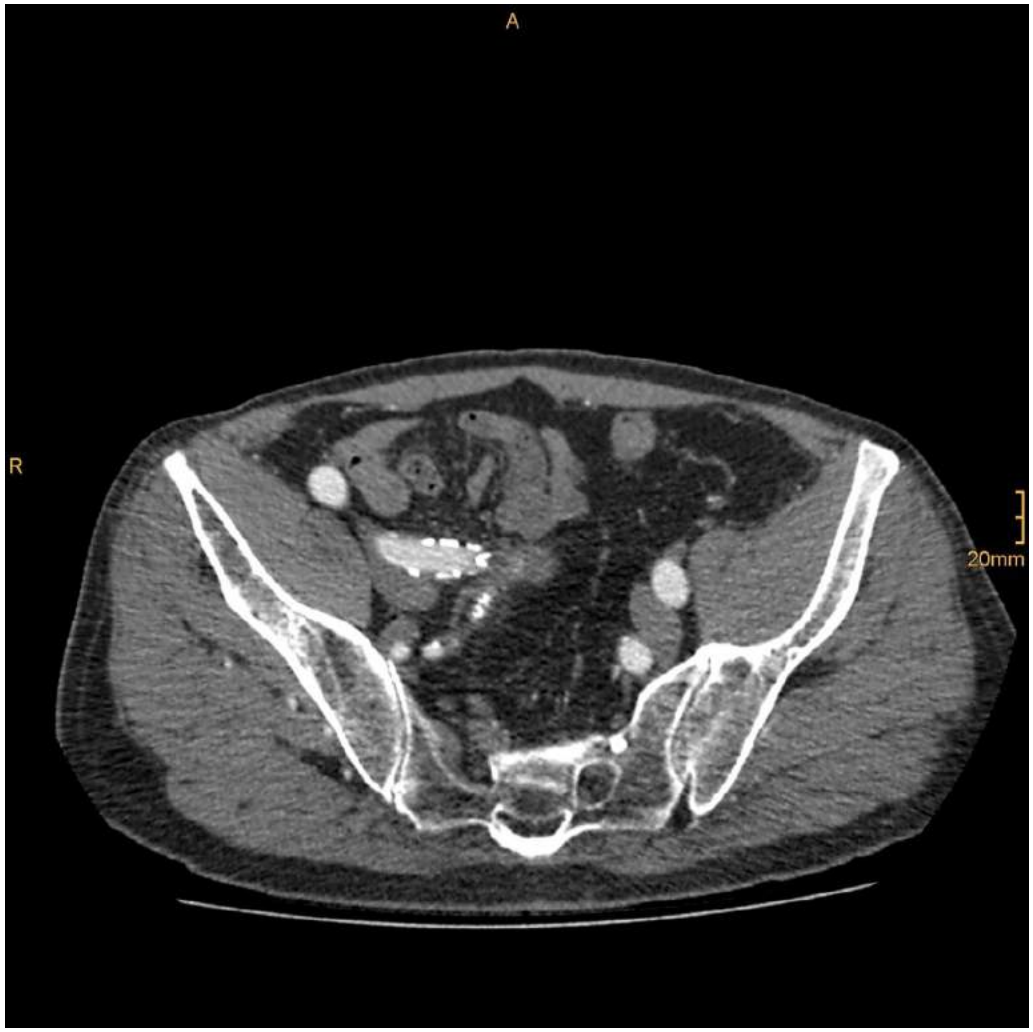
A
R
20mm

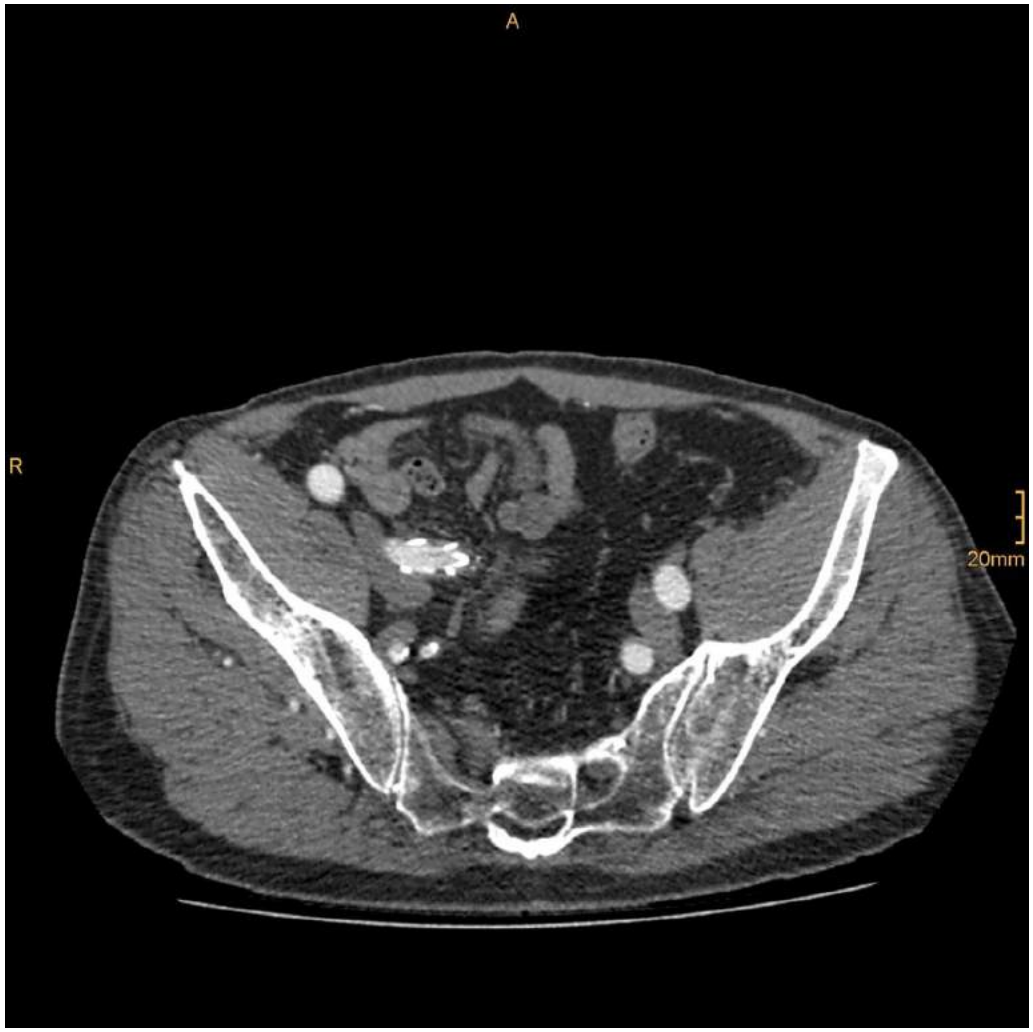
A
R
20mm

Niels-Stensen-Kliniken
Marienhospital Osnabrück

Data E-liac®

A multicenter 12-month experience with a new iliac side-branched device for revascularization of hypogastric arteries.

Mylonas SN, Rümenapf G, Schelzig H, Heckenkamp J, Youssef M, Schäfer JP, Ahmad W, Brunkwall JS; E-liac Collaborative Group.

***J Vasc Surg*.2016;64:1652-1659**

CONCLUSIONS:

This first ever 1-year study reports the results with the new E-liac device and shows that it can be safely applied for the treatment of aortoiliac aneurysmatic disease with low reintervention rates and high patency rates. Long-term data are needed to confirm the durability of the device.

Niels-Stensen-Kliniken
Marienhospital Osnabrück

Basic Measurements

Country: Germany
City: Osnabrück
Hospital: Marienhospital
Doctor: Prof. Heckenkamp
Initials: P.H.
Birthday: 17.09.1928

E-xtra DESIGN ENGINEERING

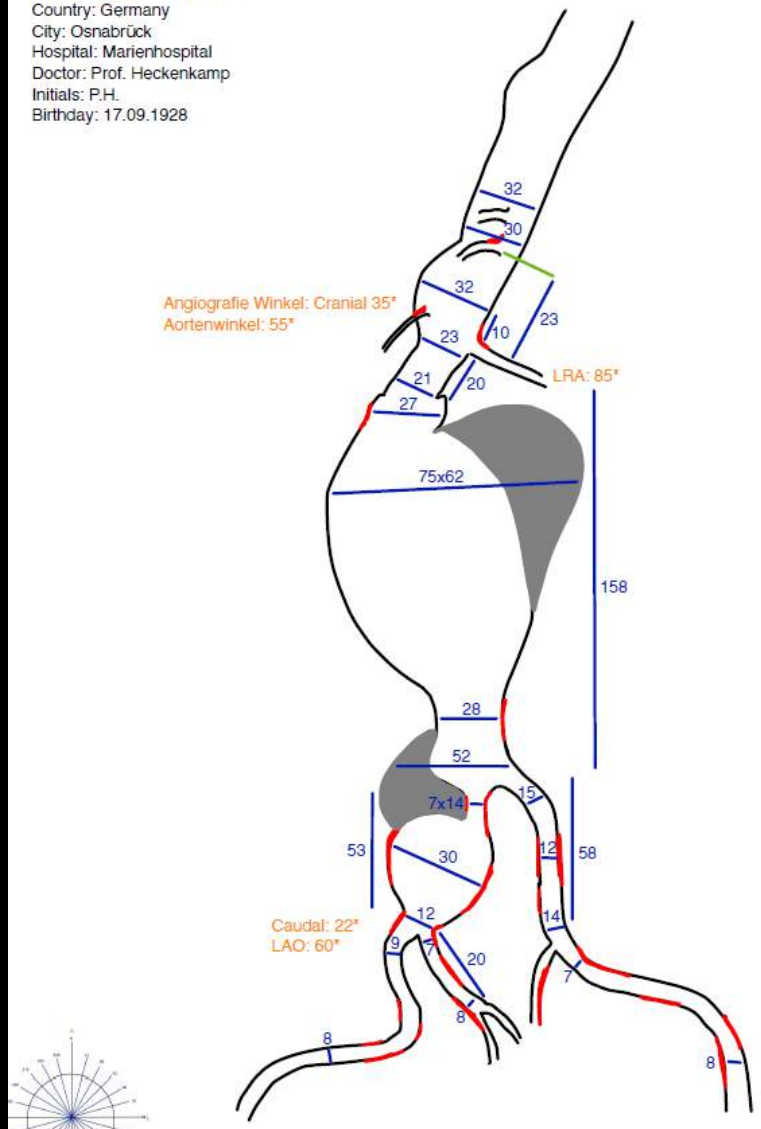

JOTEC GmbH, E-xtra Design Engineering,
Lotzenäcker 23, 72379 Hechingen, Tel. 07471922301, Fax 07471922101

Niels-Stensen-Kliniken
Marienhospital Osnabrück

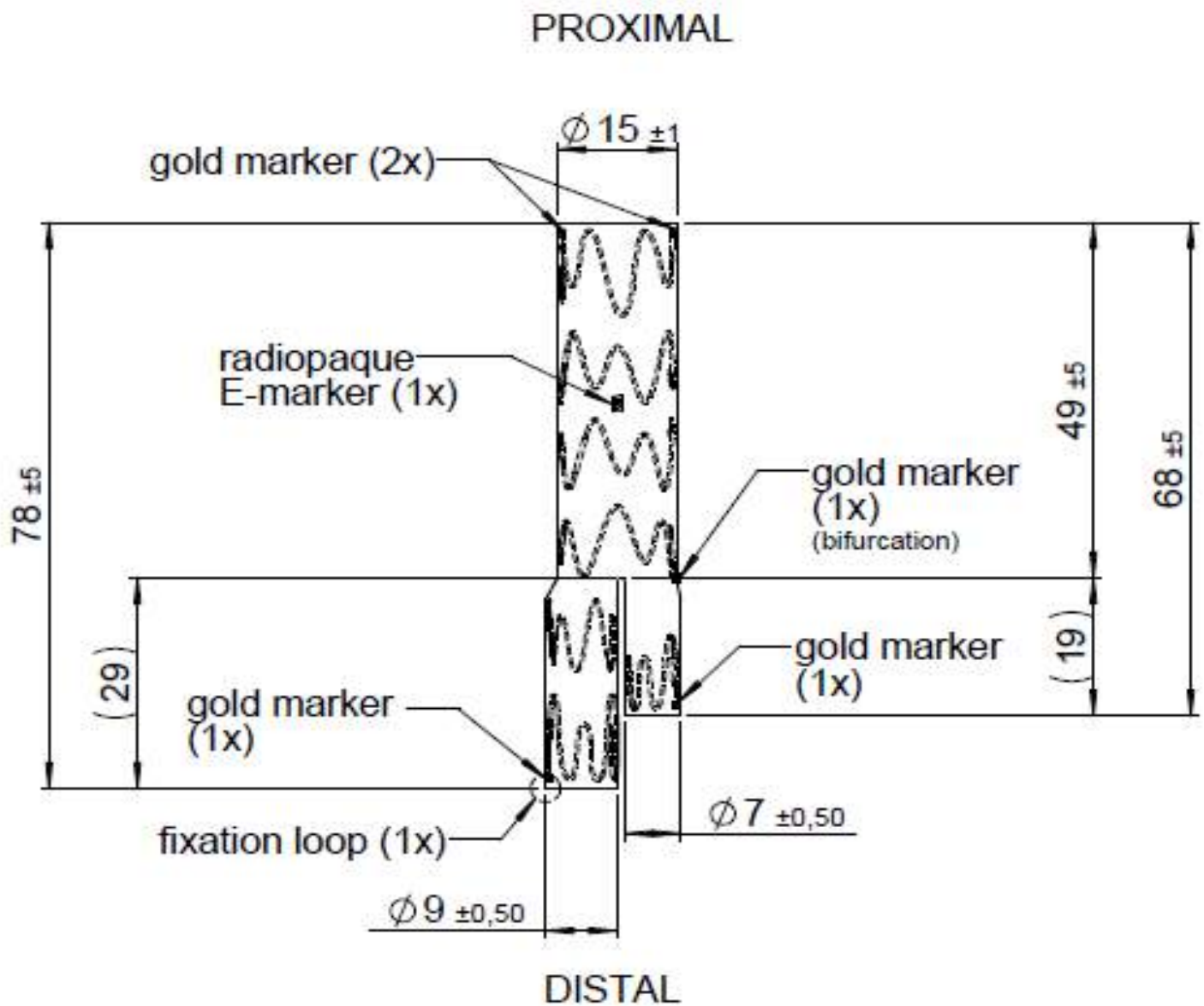

Niels-Stensen-Kliniken
Marienhospital Osnabrück



Niels-Stensen-Kliniken
Marienhospital Osnabrück


A
R
20mm

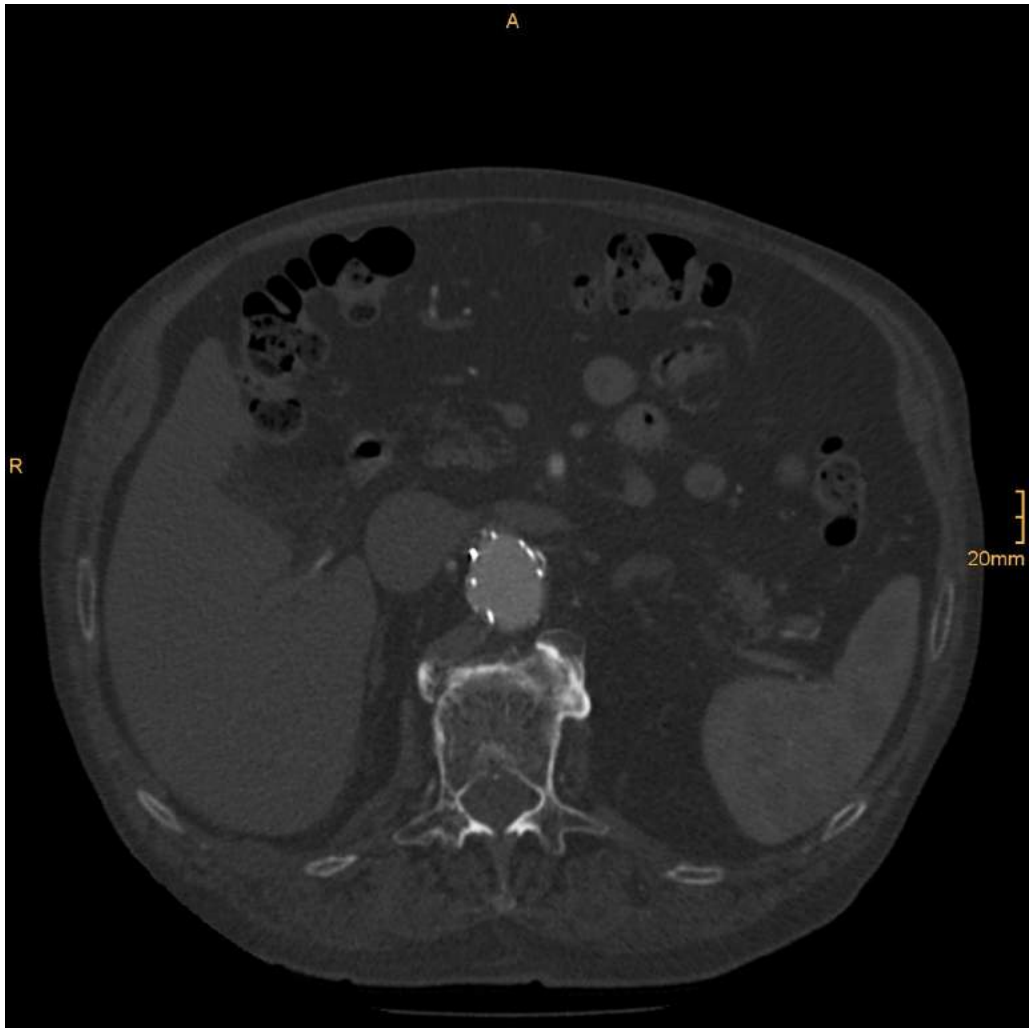
A
R
20mm


A
R
20mm

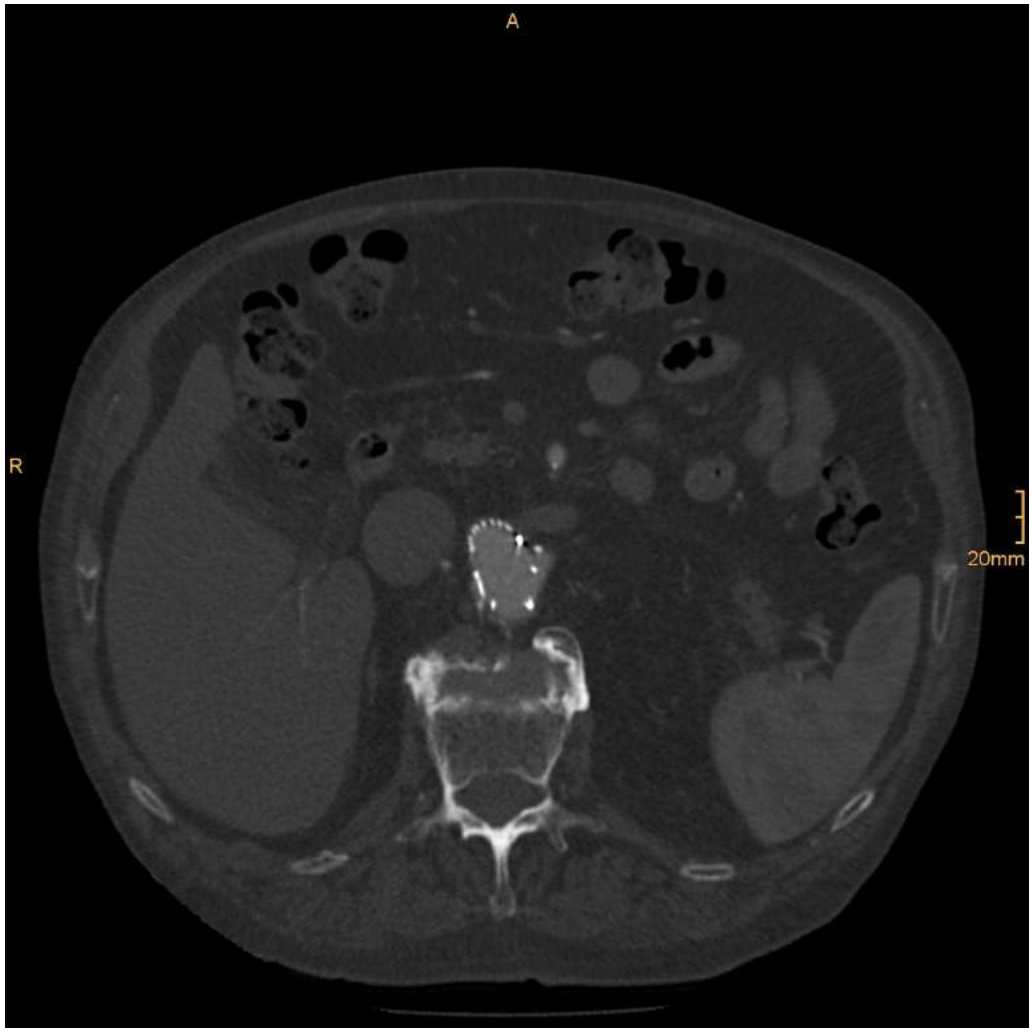
A
R
20mm


A
R
20mm

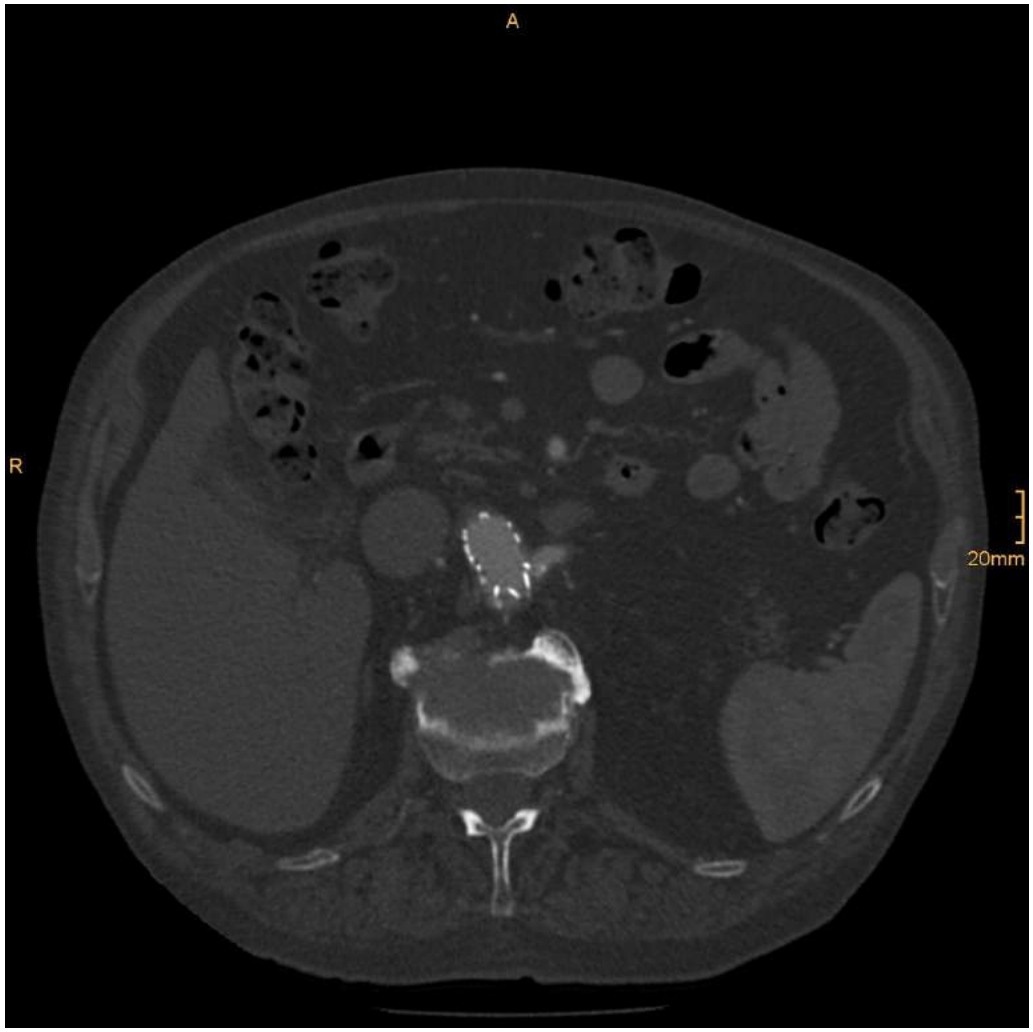
A
R
20mm

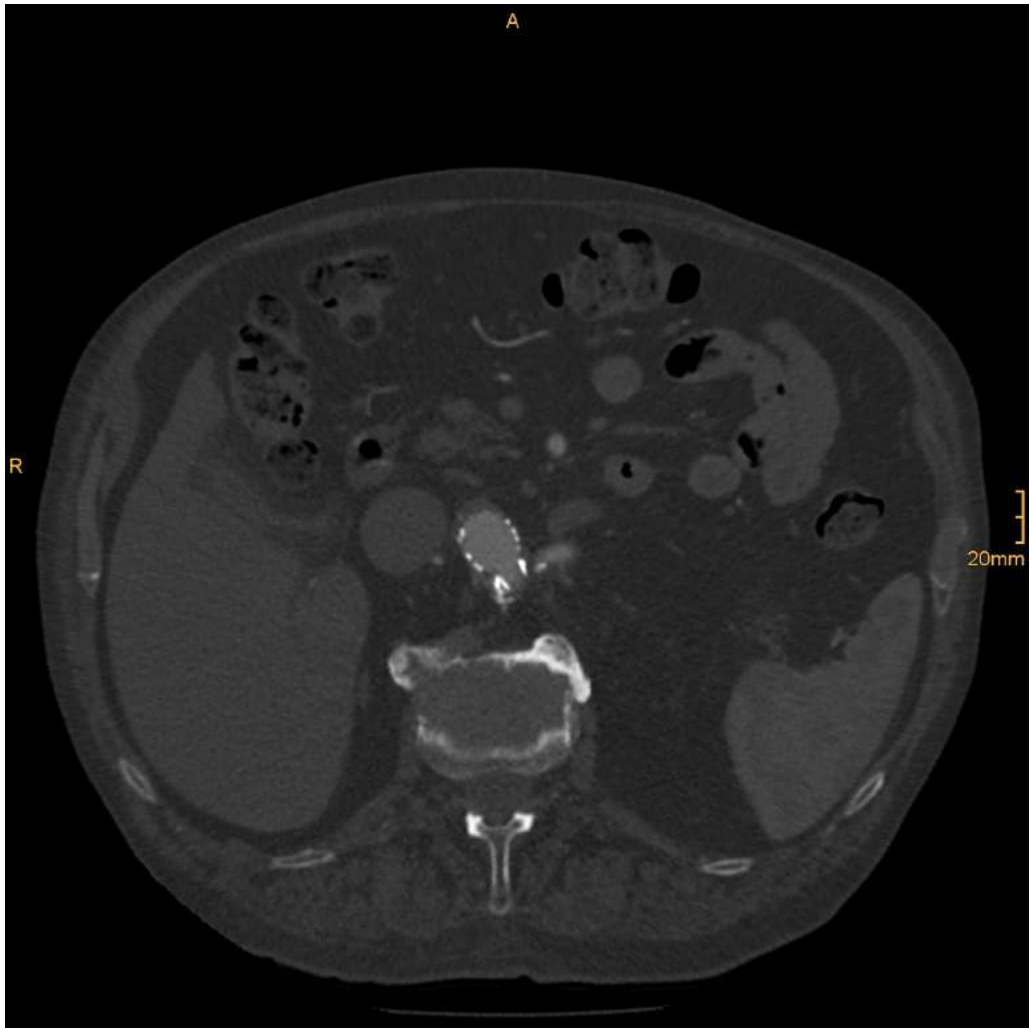
A
R
20mm


A
R
20mm


A
R
20mm


A
R
20mm


A
R
20mm

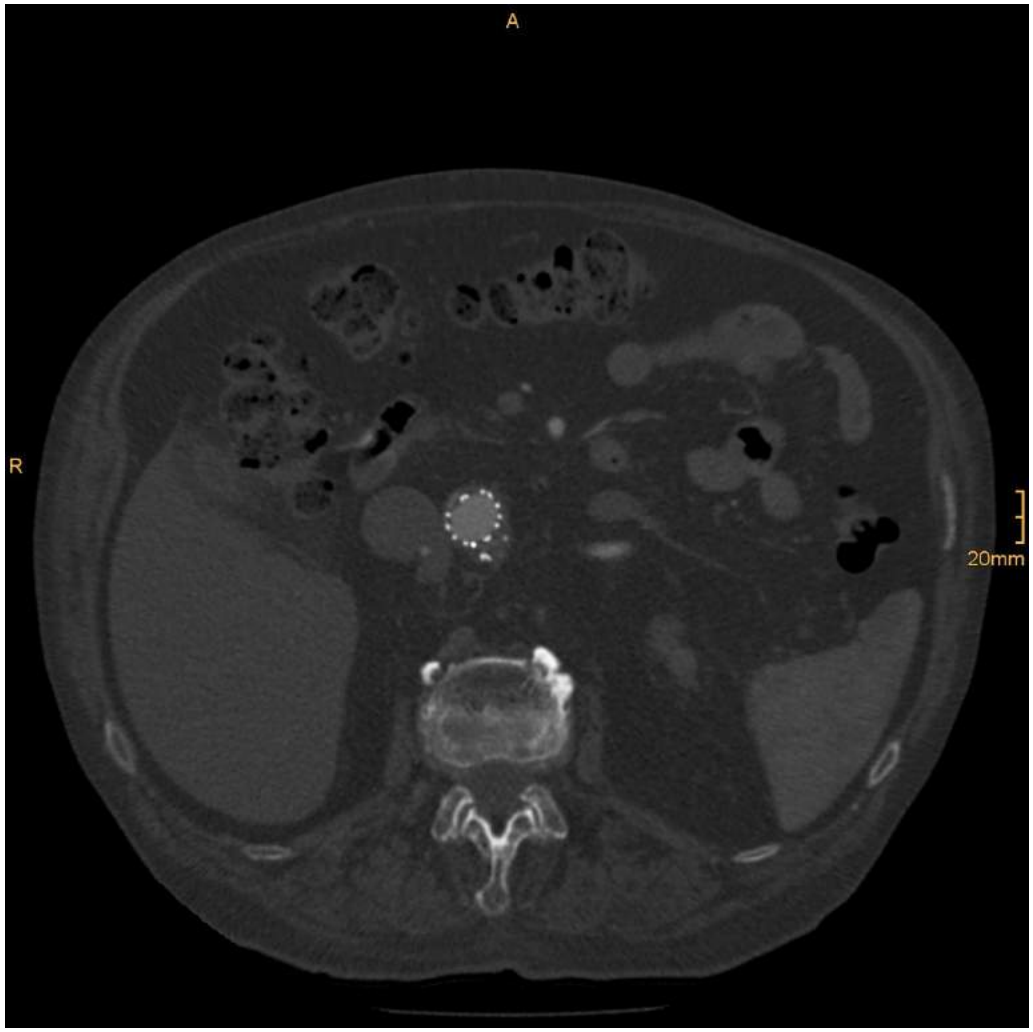
A
R
20mm


A
R
20mm


A
R
20mm


A
R
20mm


A
R
20mm

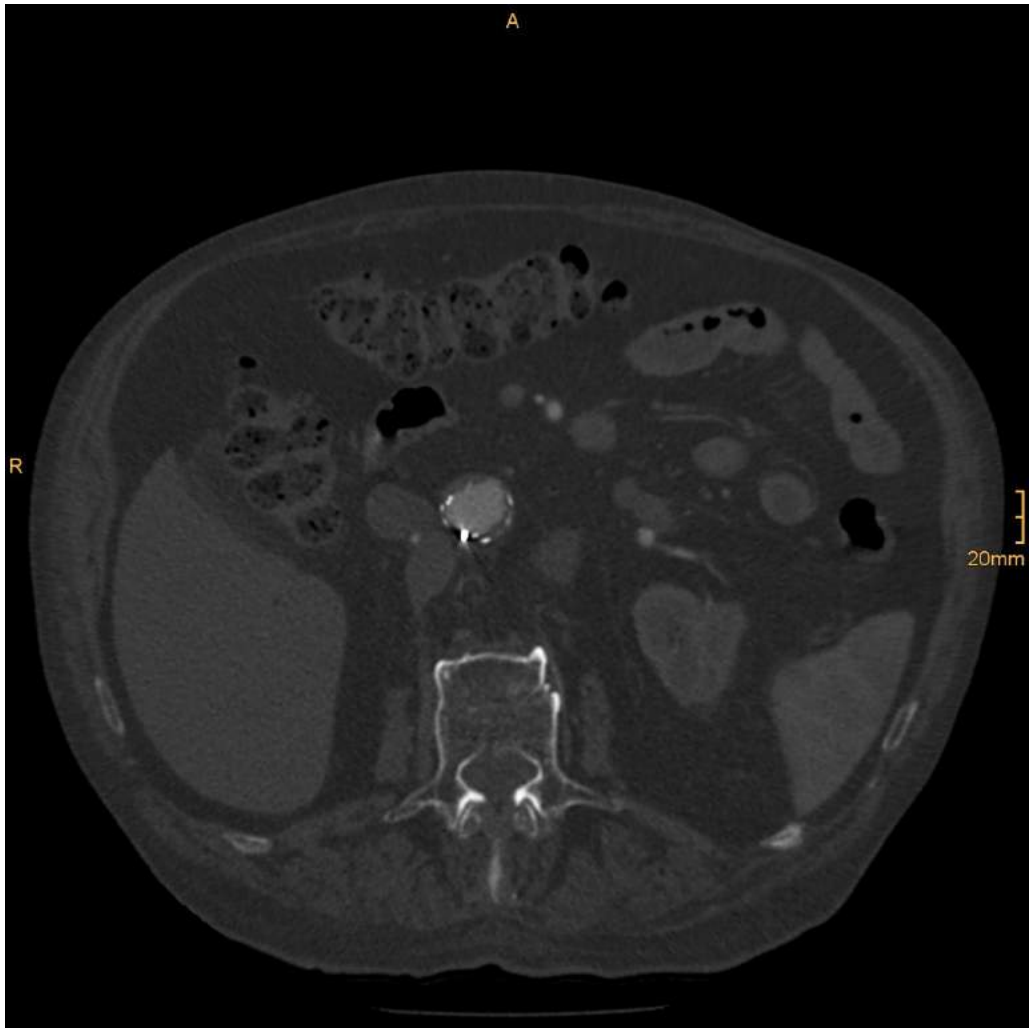
A
R
20mm

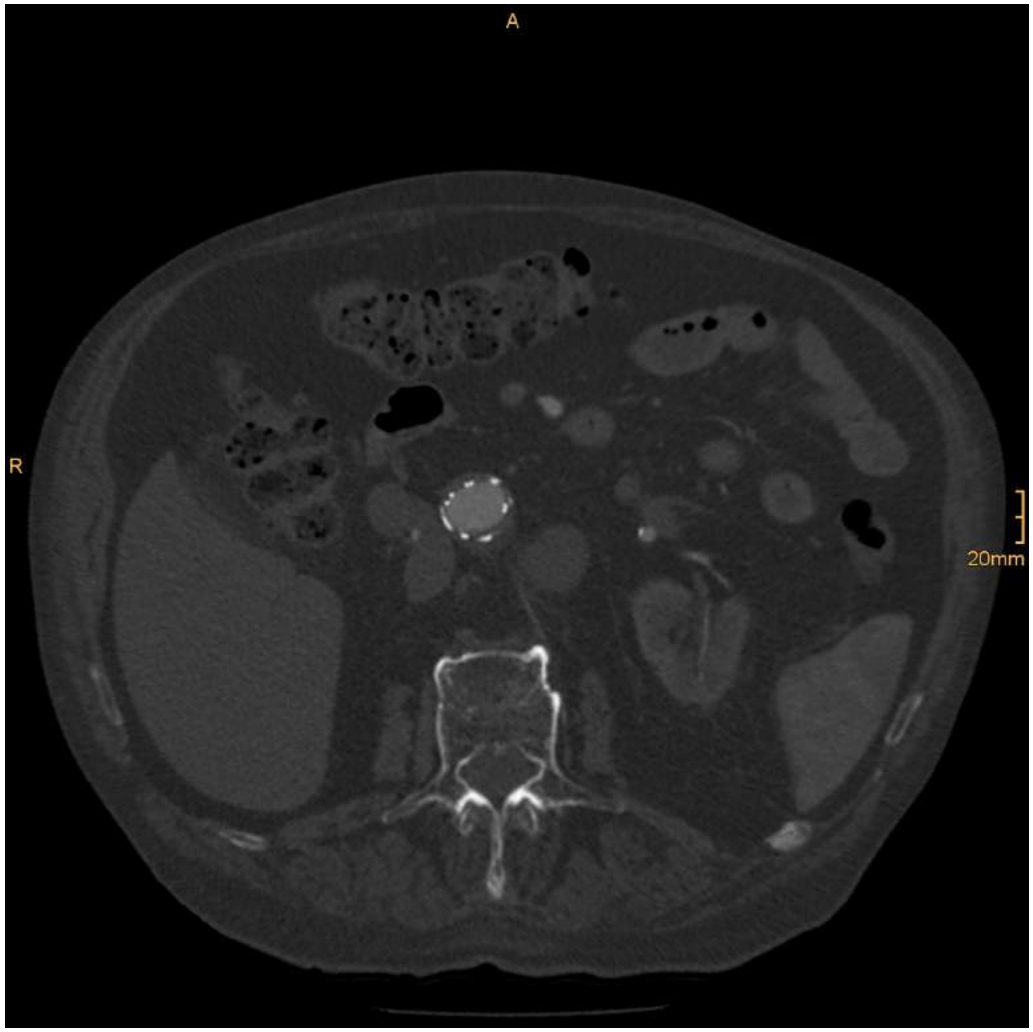
A
R
20mm


A
R
20mm


A
R
20mm

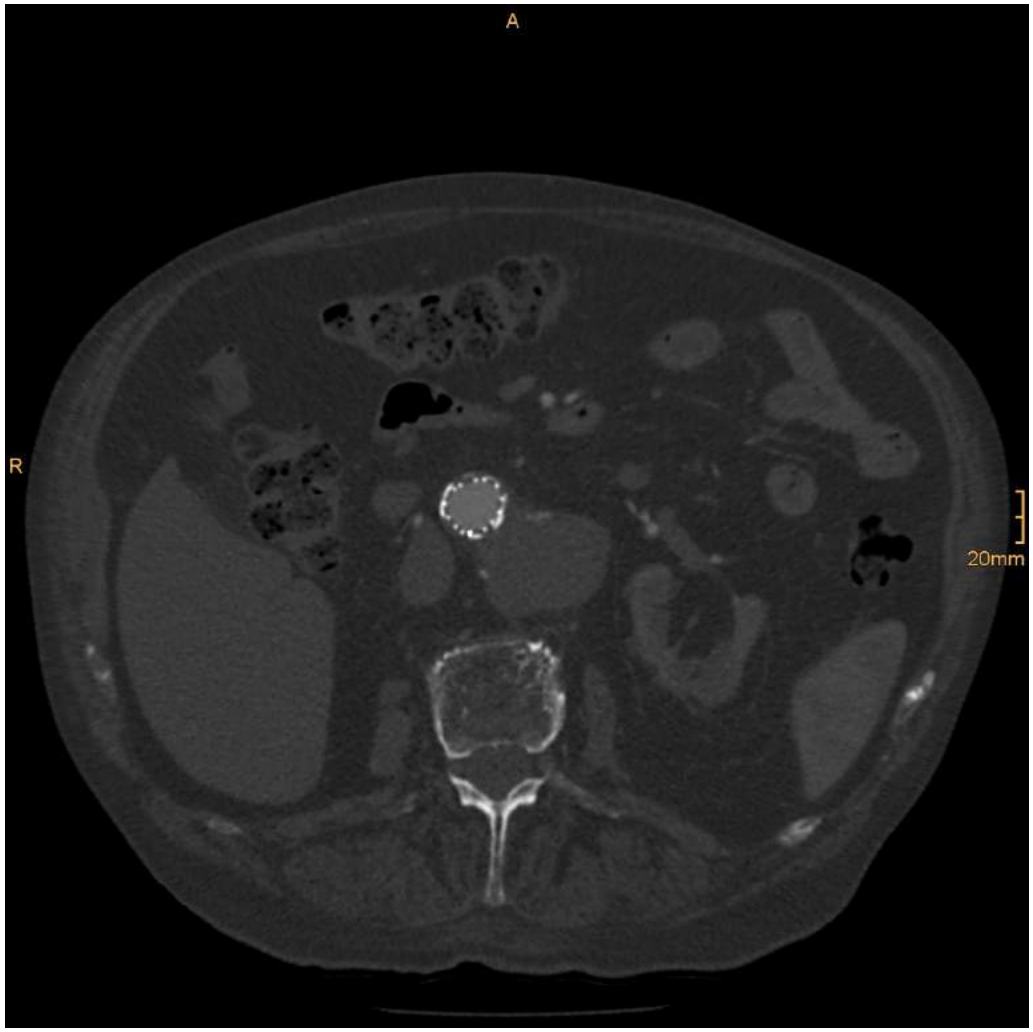
A
R
20mm

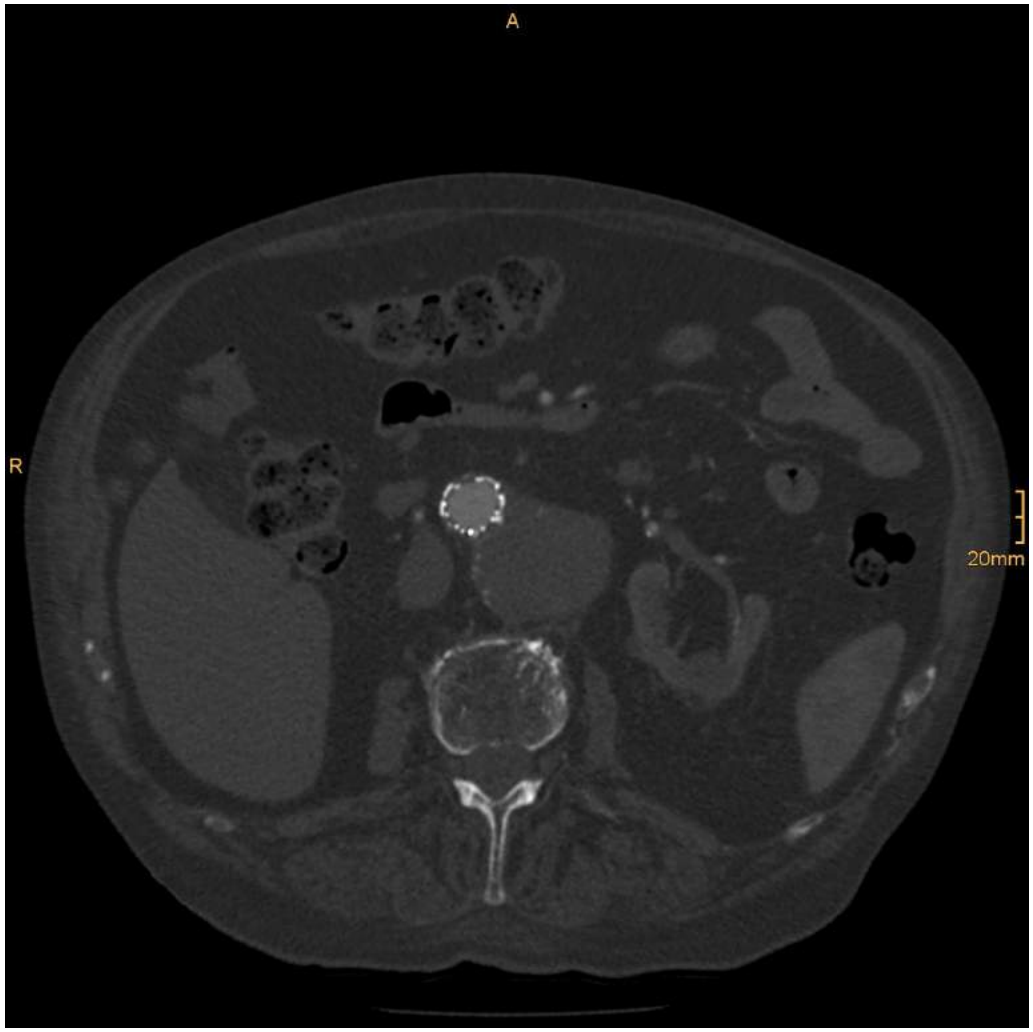
A
R
20mm

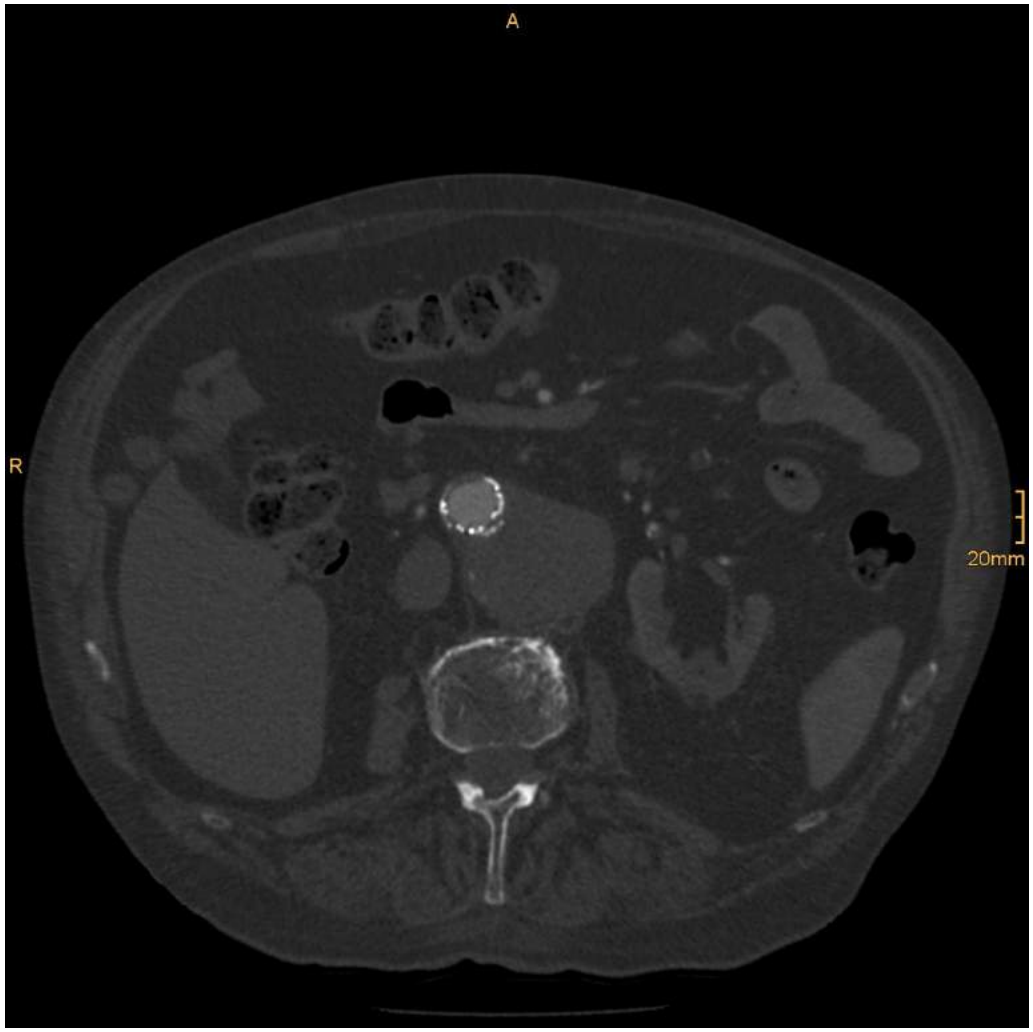
A
R
20mm

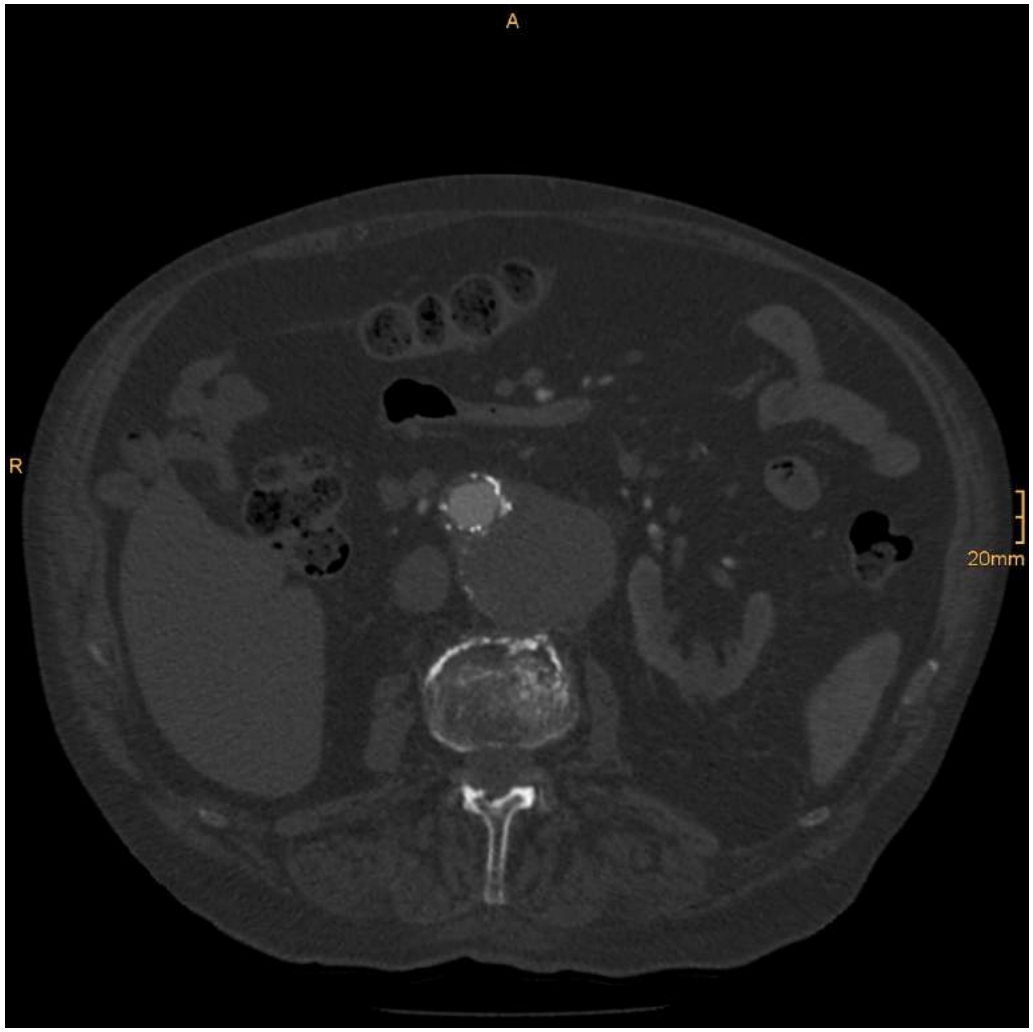
A
R
20mm

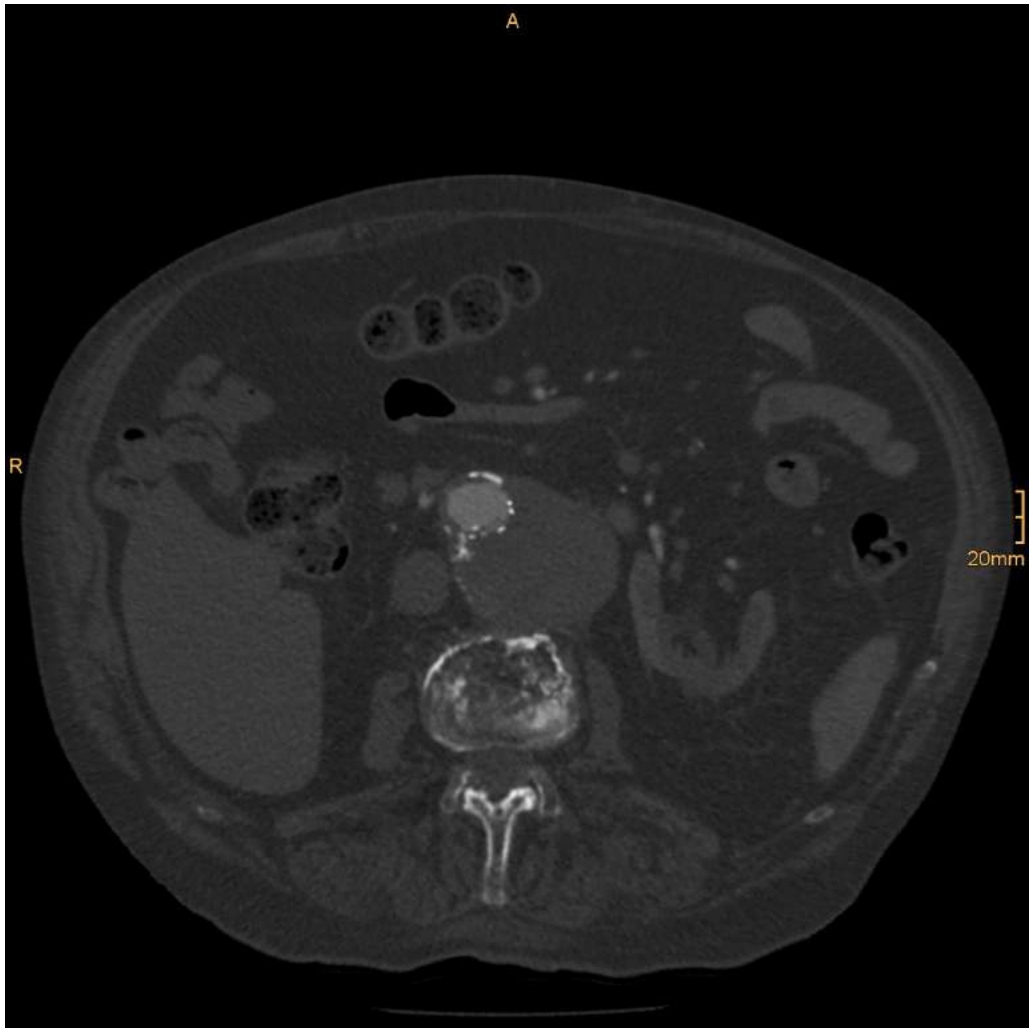
A
R
20mm

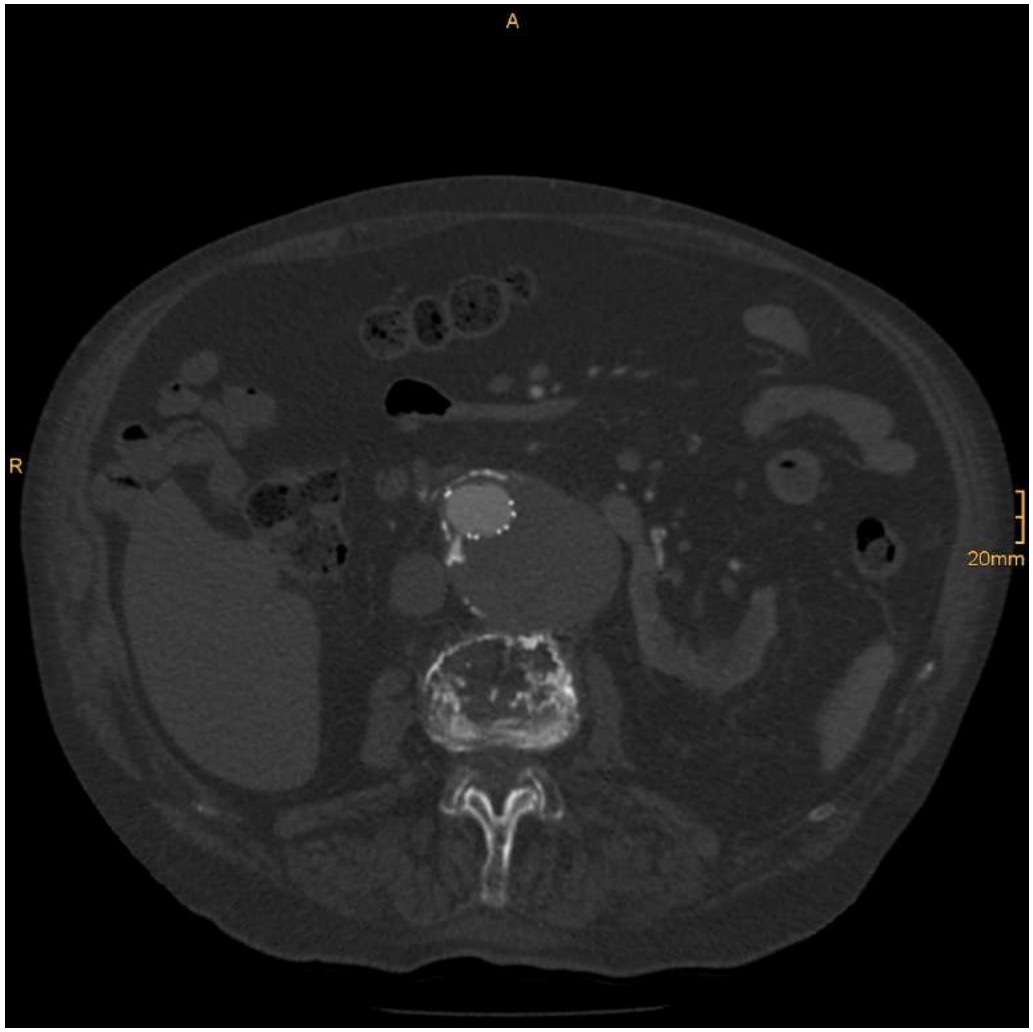
A
R
20mm


A
R
20mm


A
R
20mm


A
R
20mm

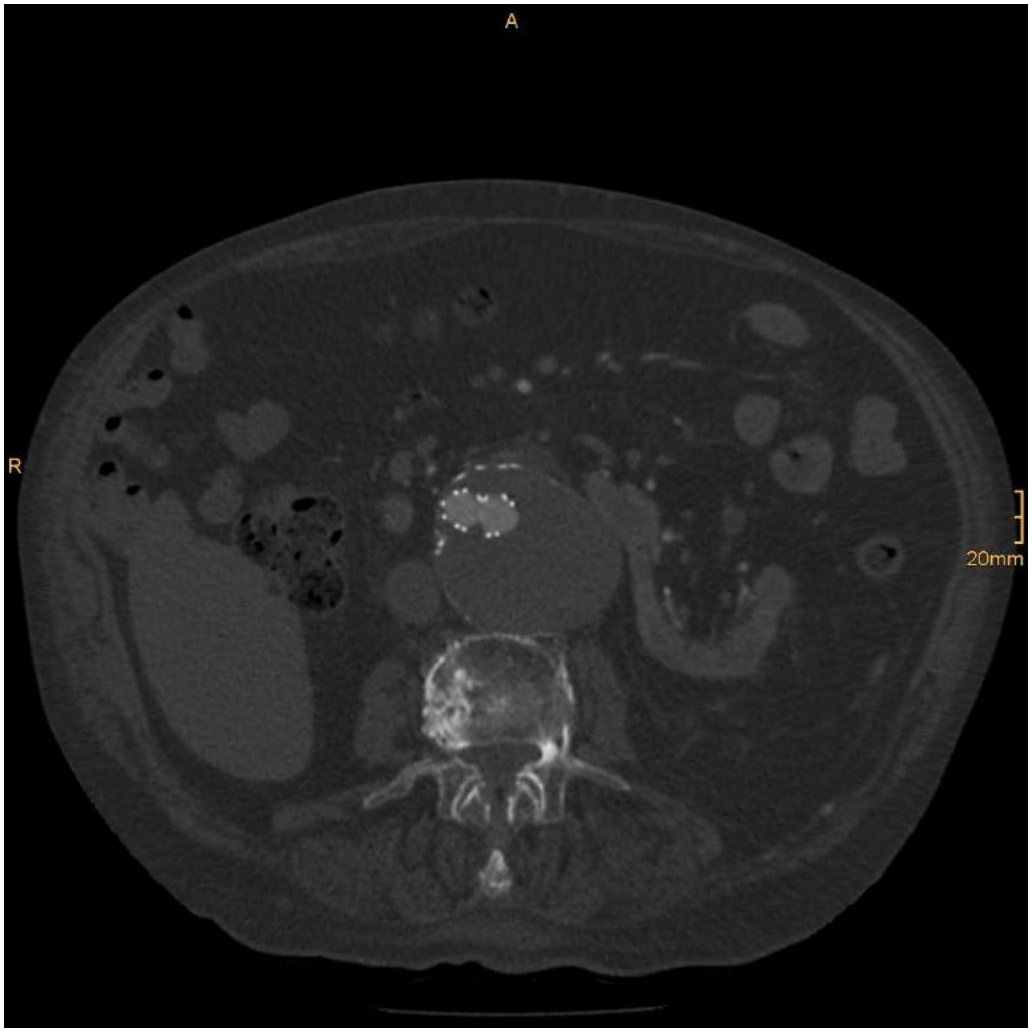
A
R
20mm

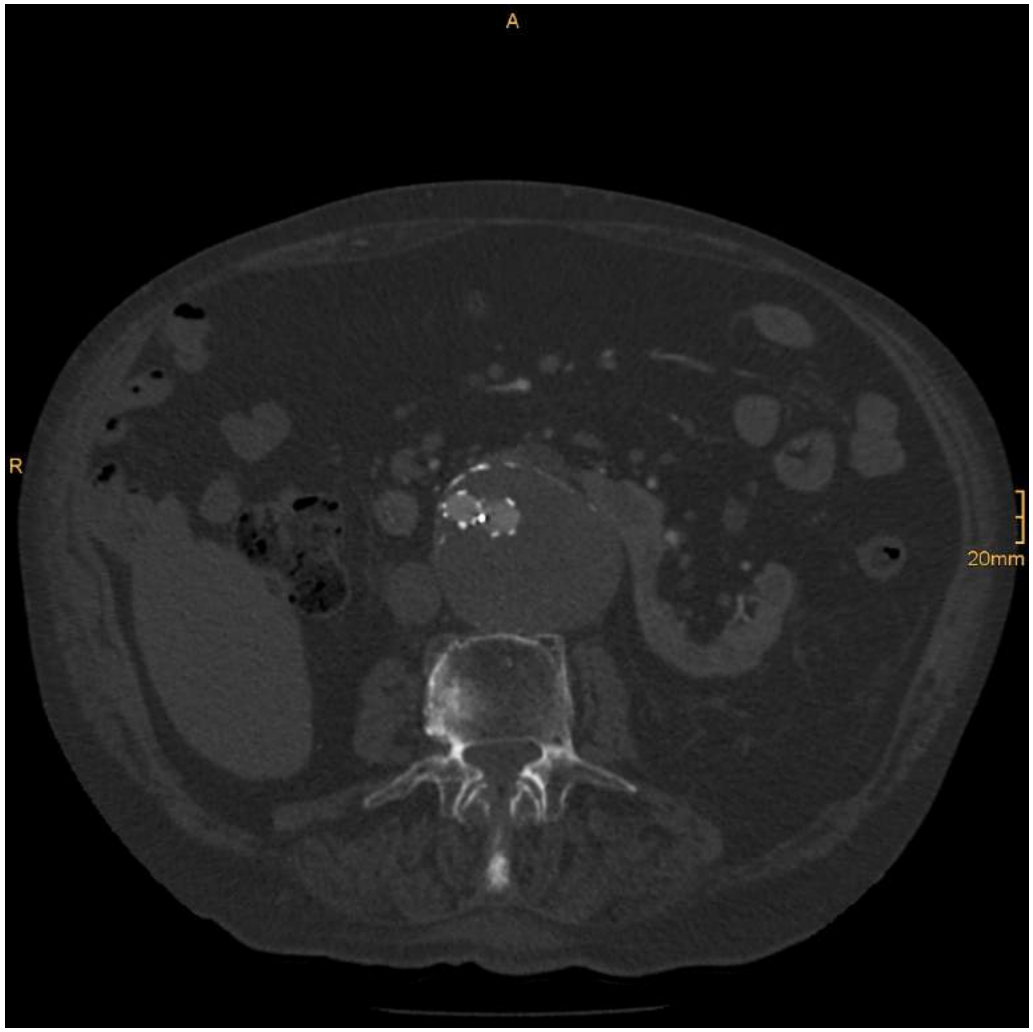
A
R
20mm

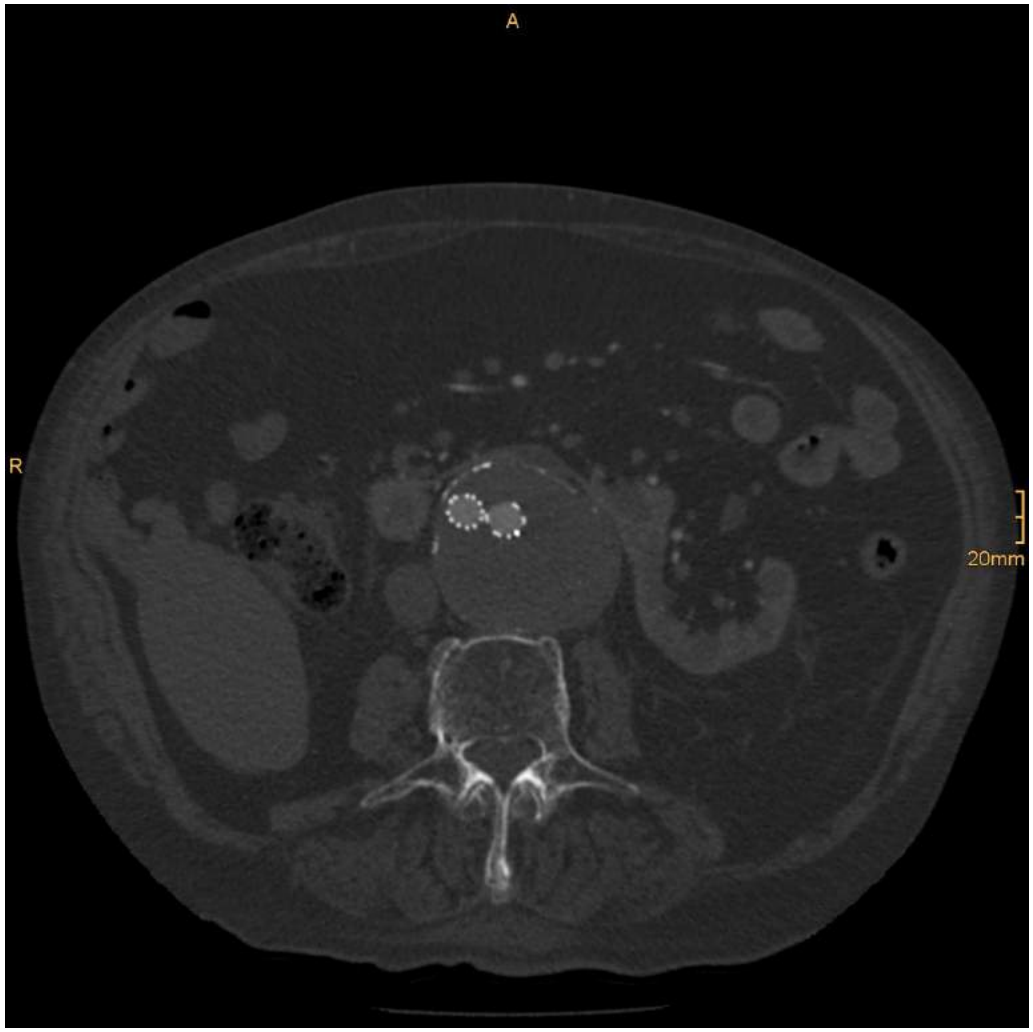
A
R
20mm

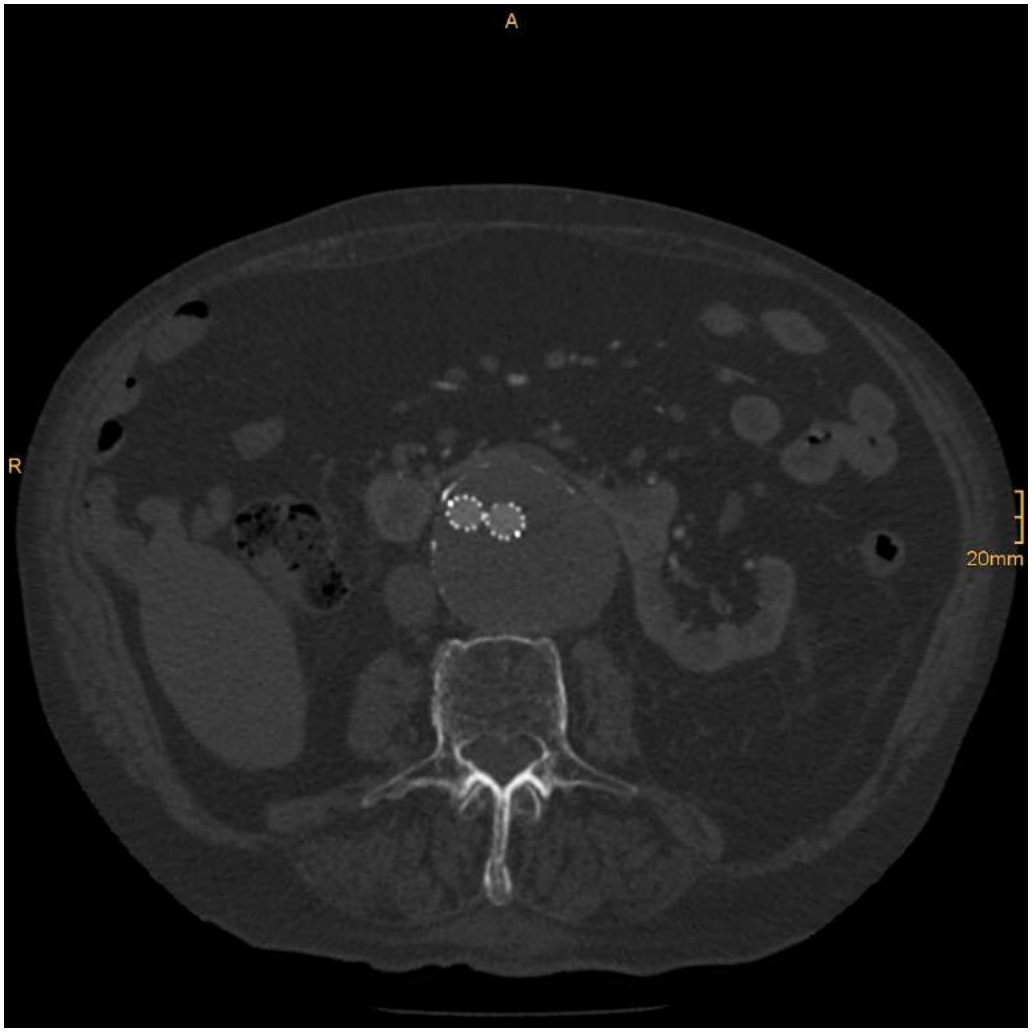
A
R
20mm

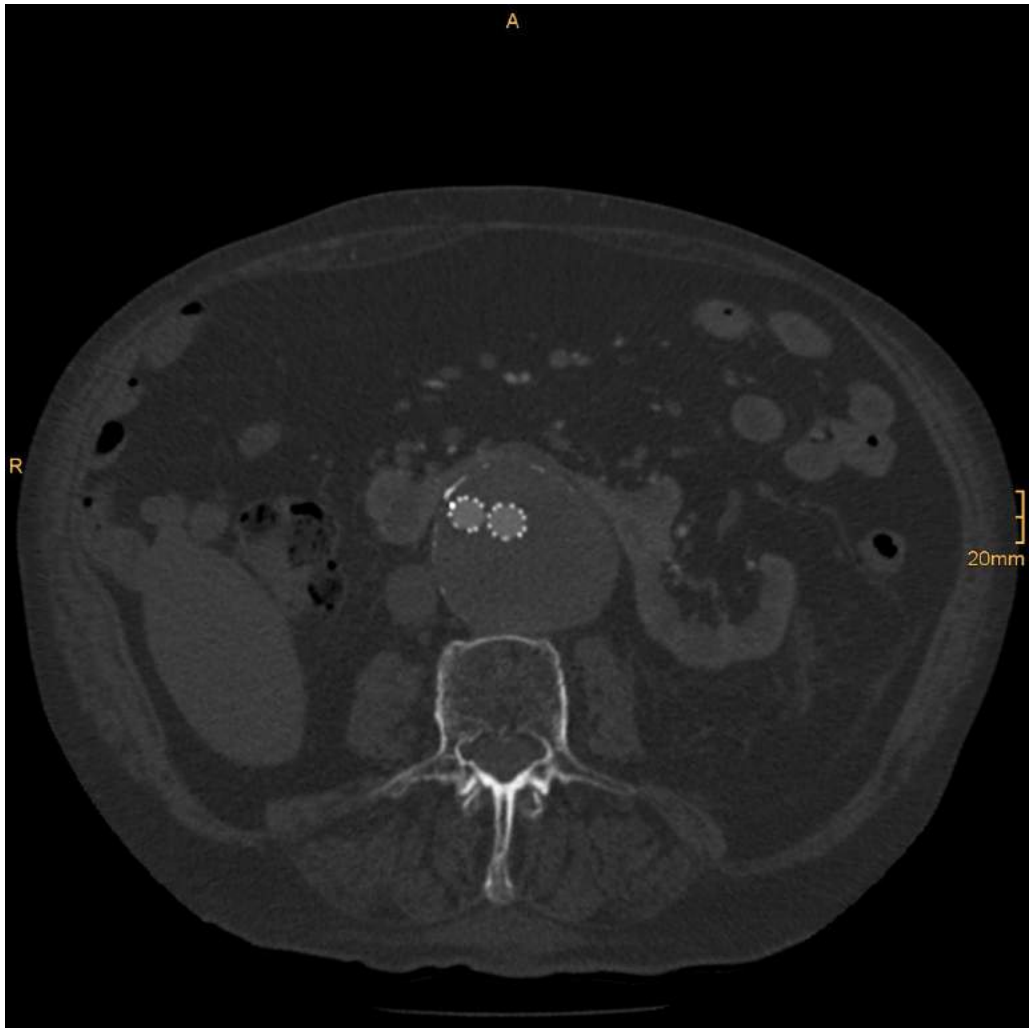
A
R
20mm

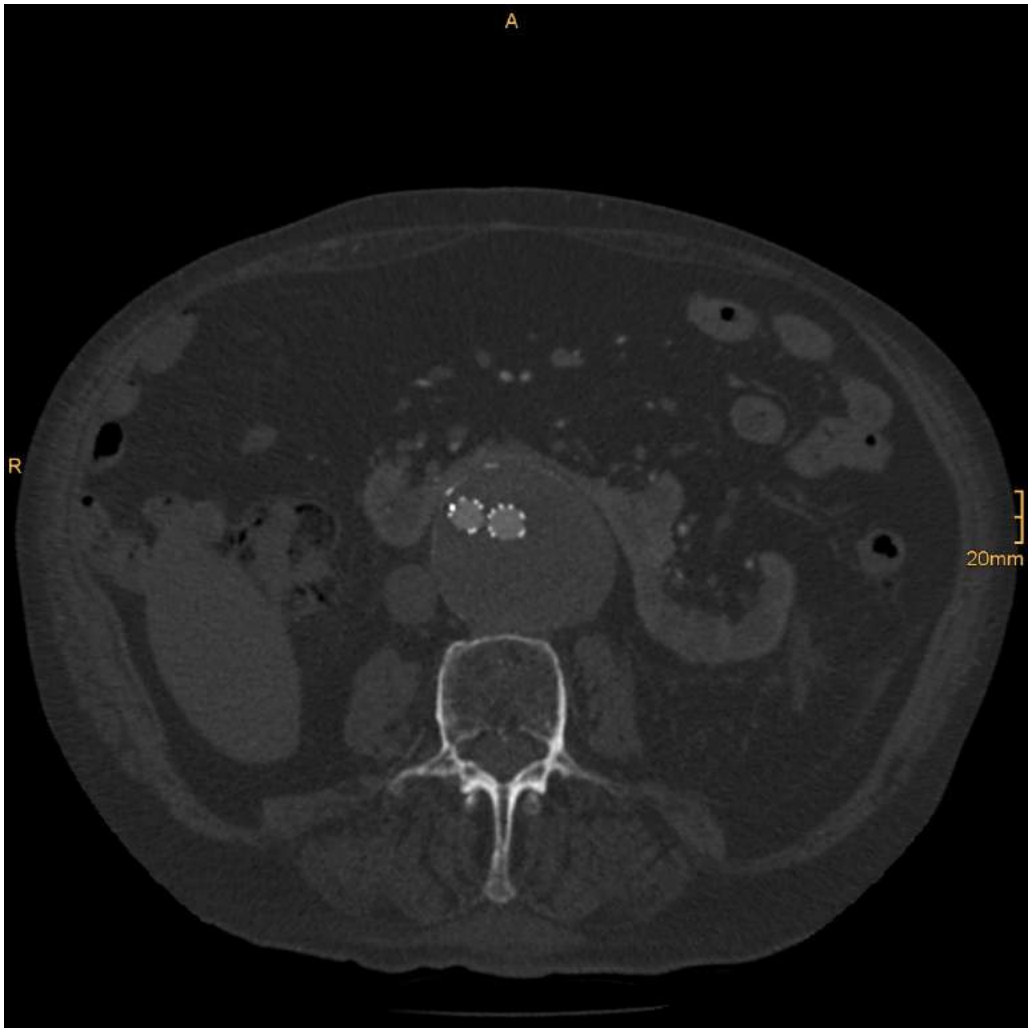
A
R
20mm

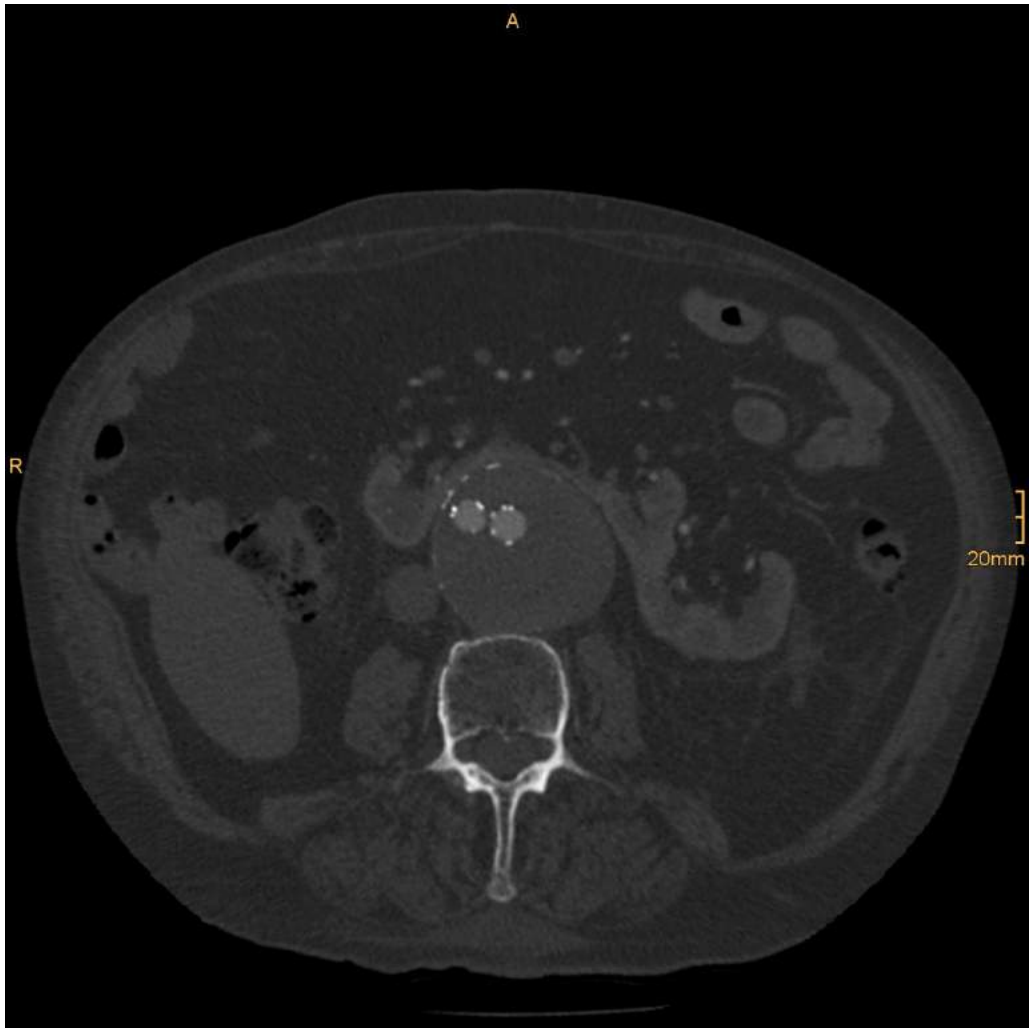
A
R
20mm

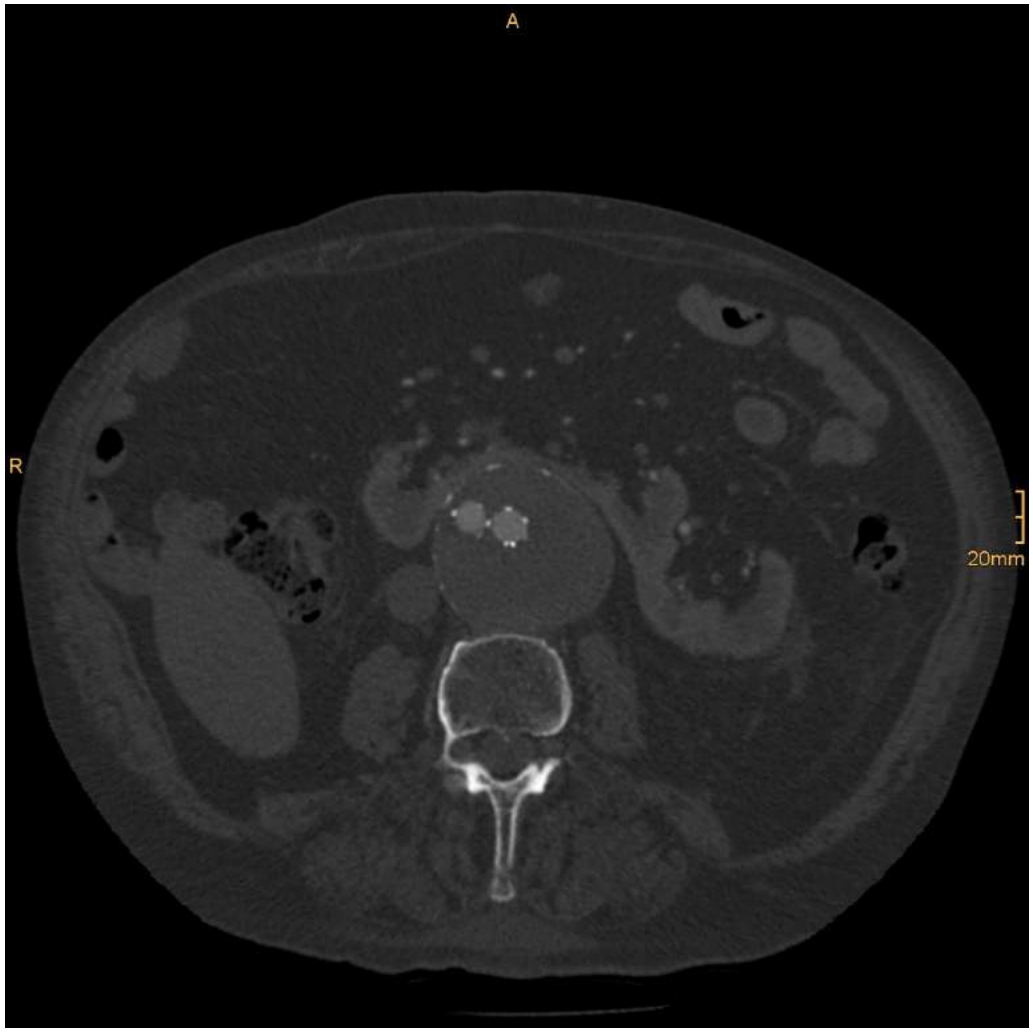
A
R
20mm

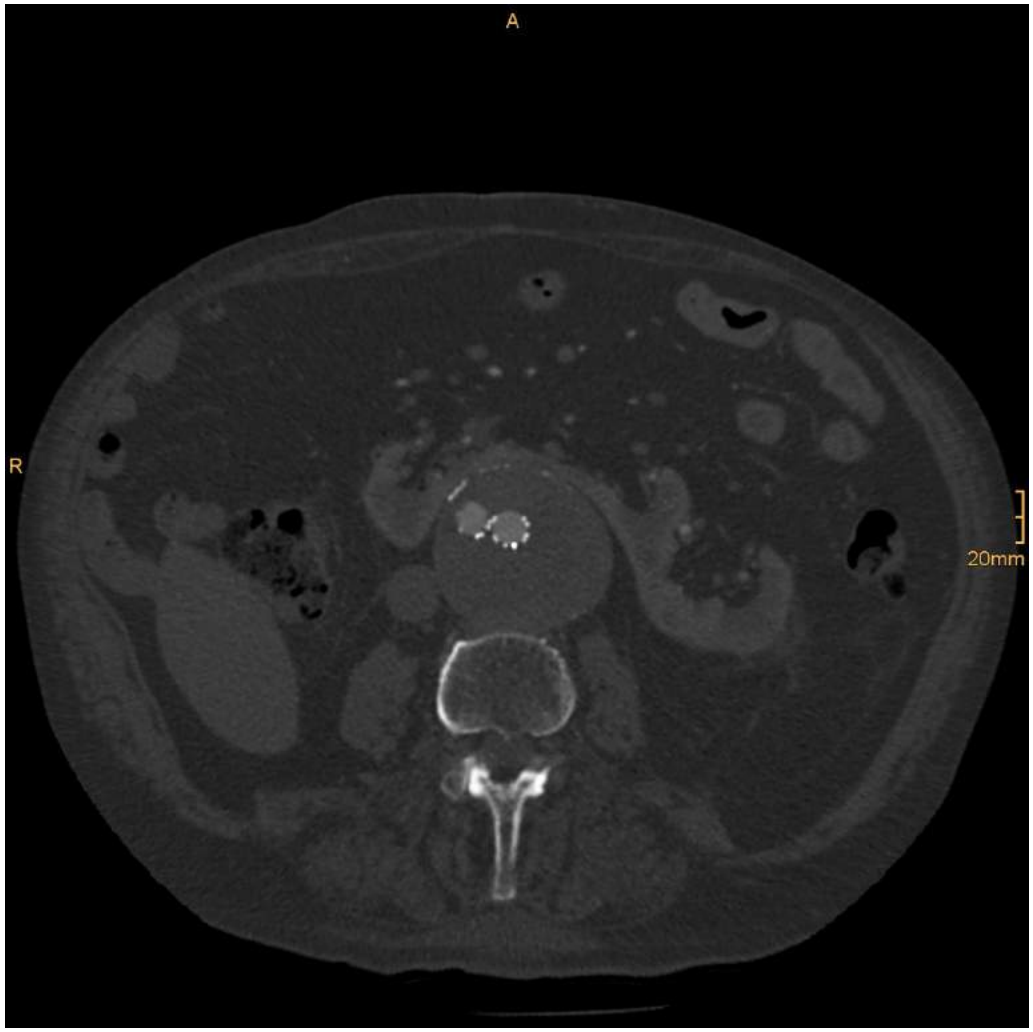
A
R
20mm

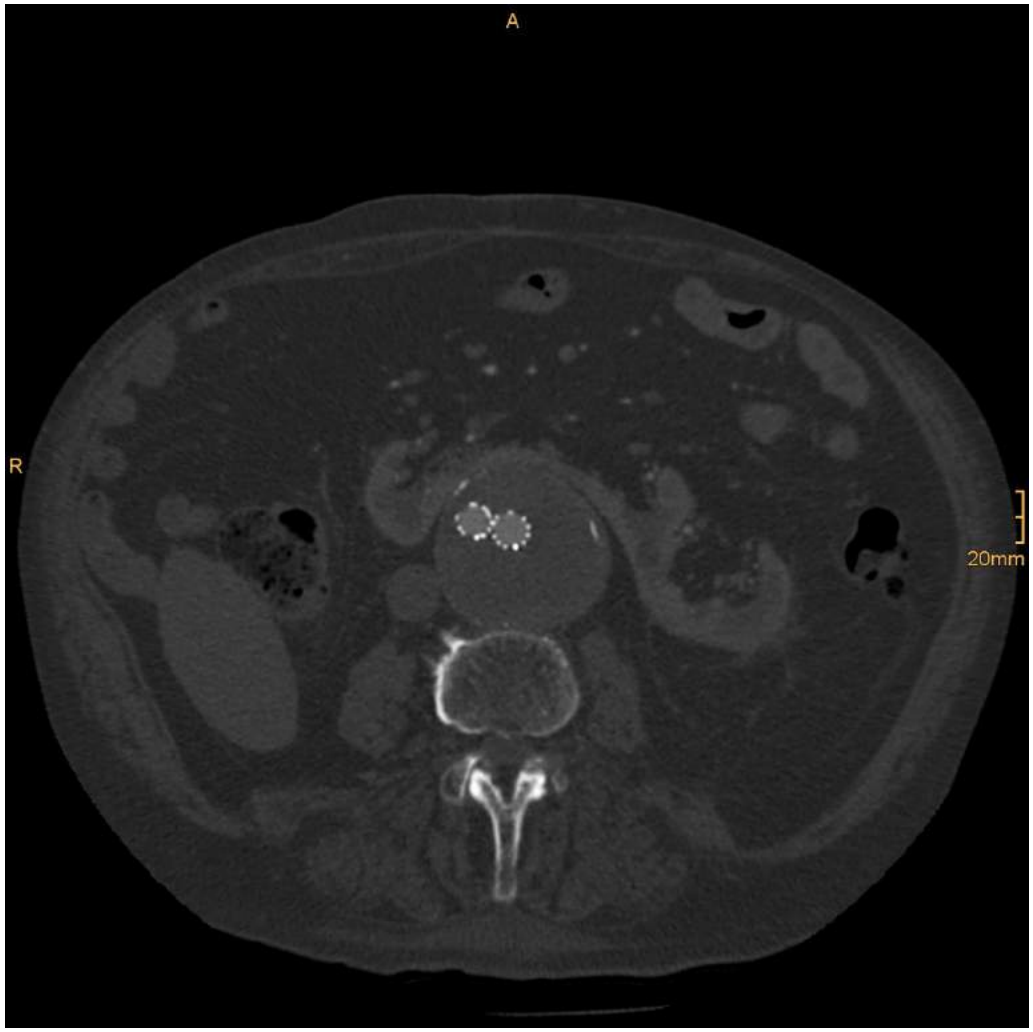
A
R
20mm


A
R
20mm

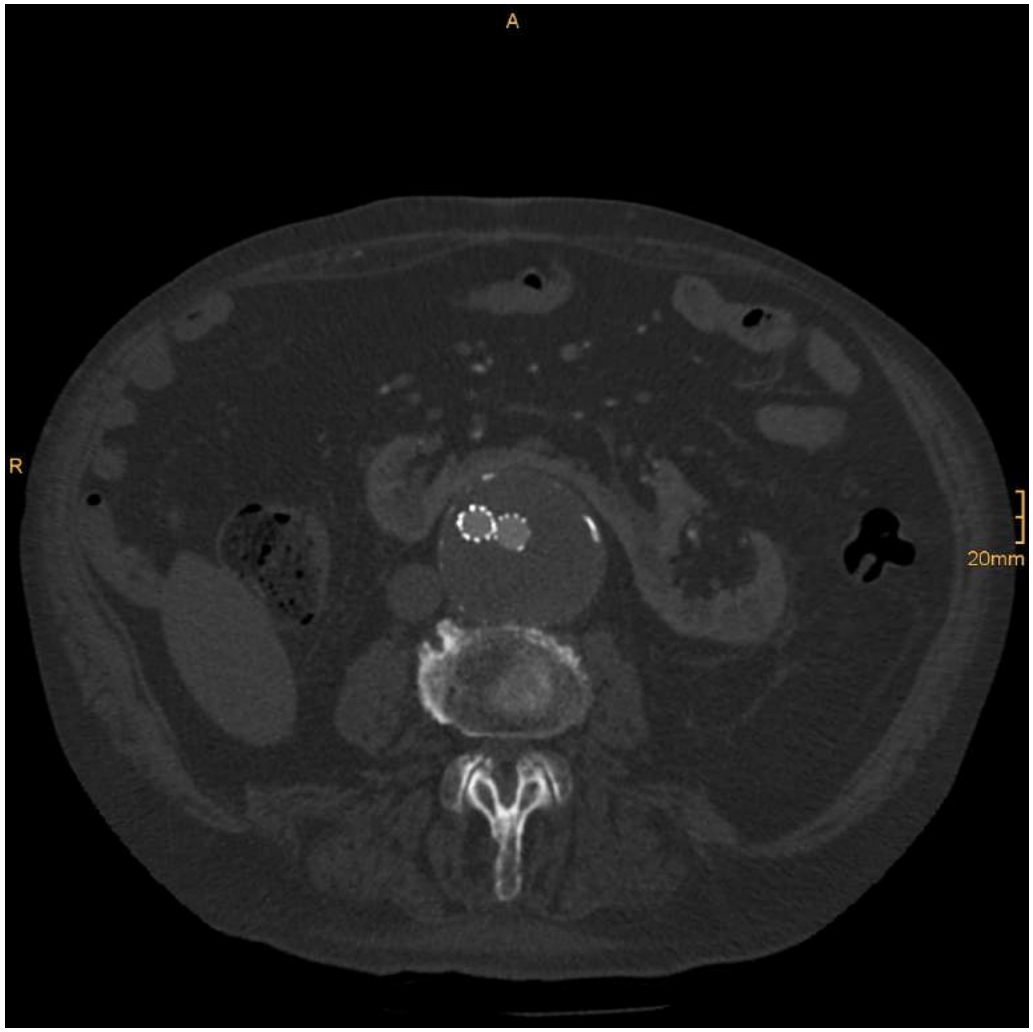
A
R
20mm

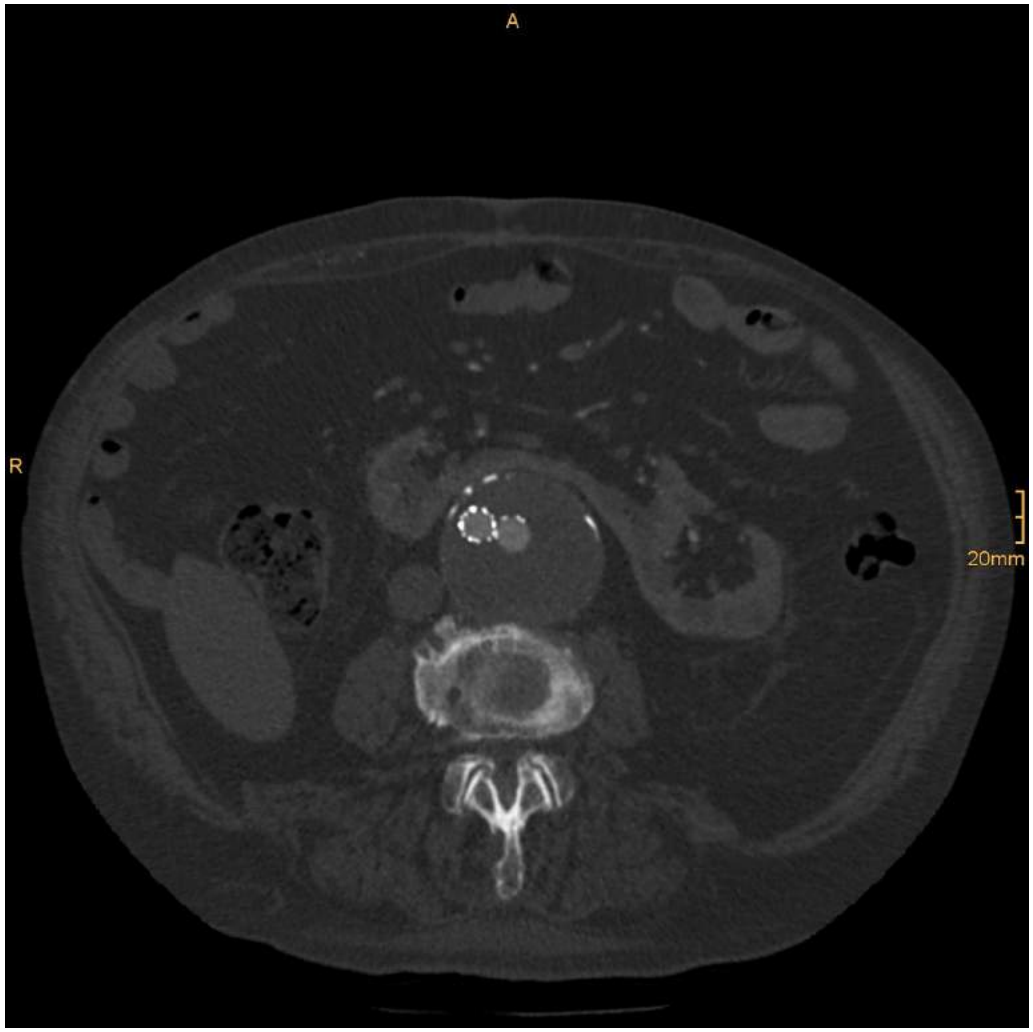
A
R
20mm

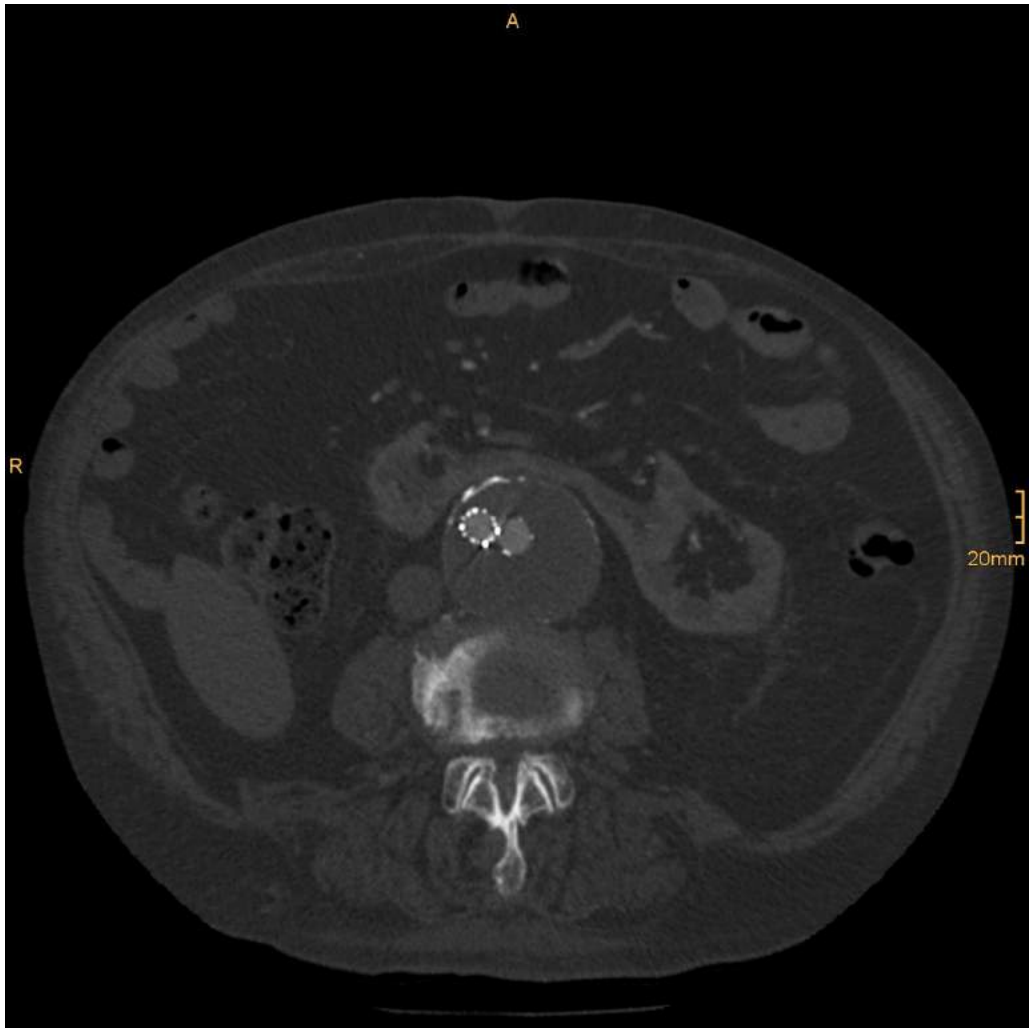
A
R
20mm

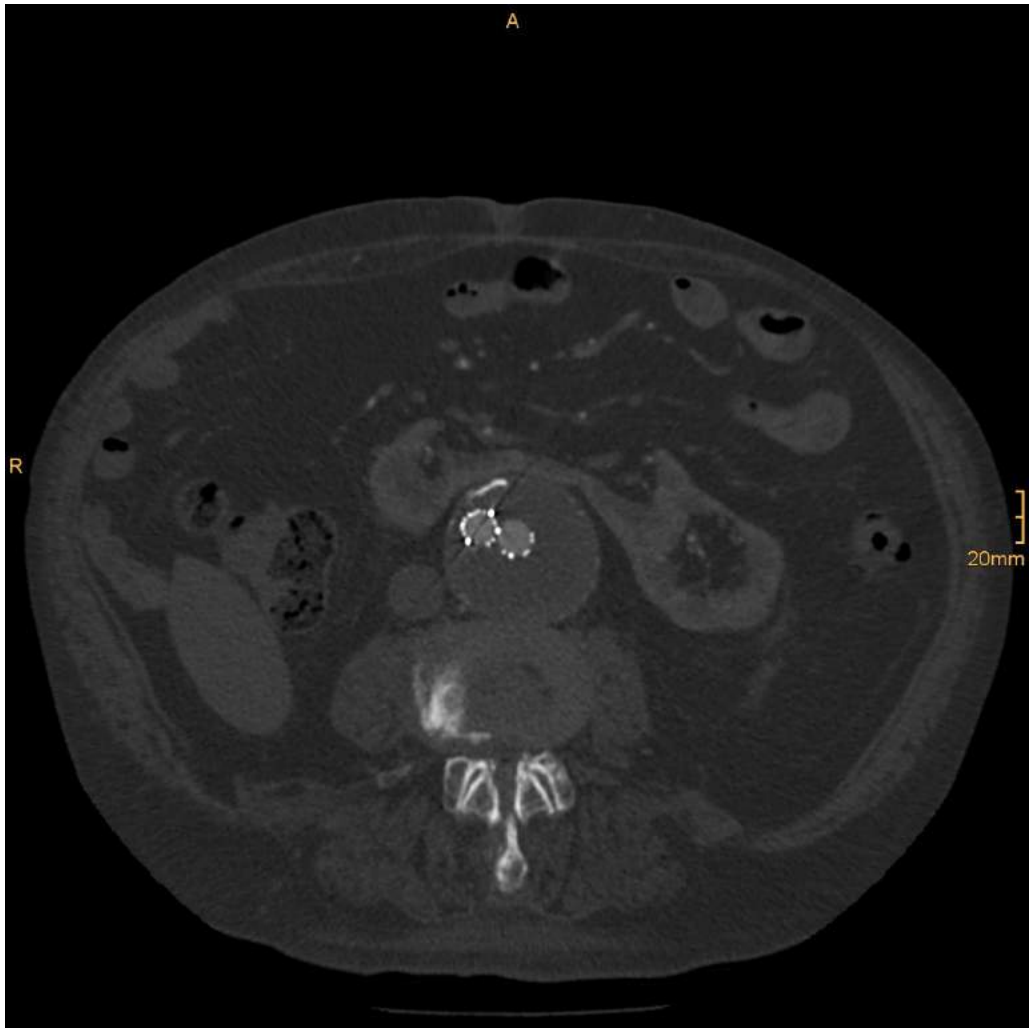
A
R
20mm

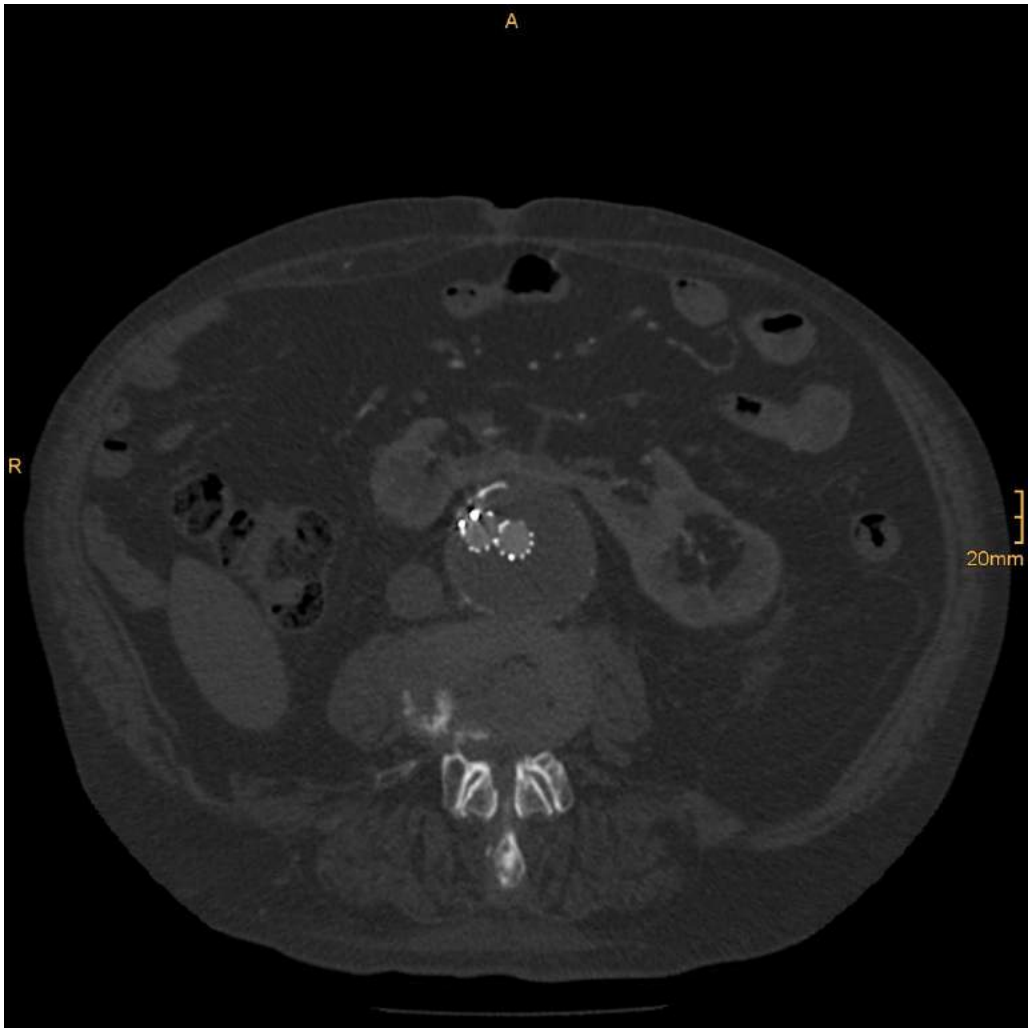
A
R
20mm


A
R
20mm

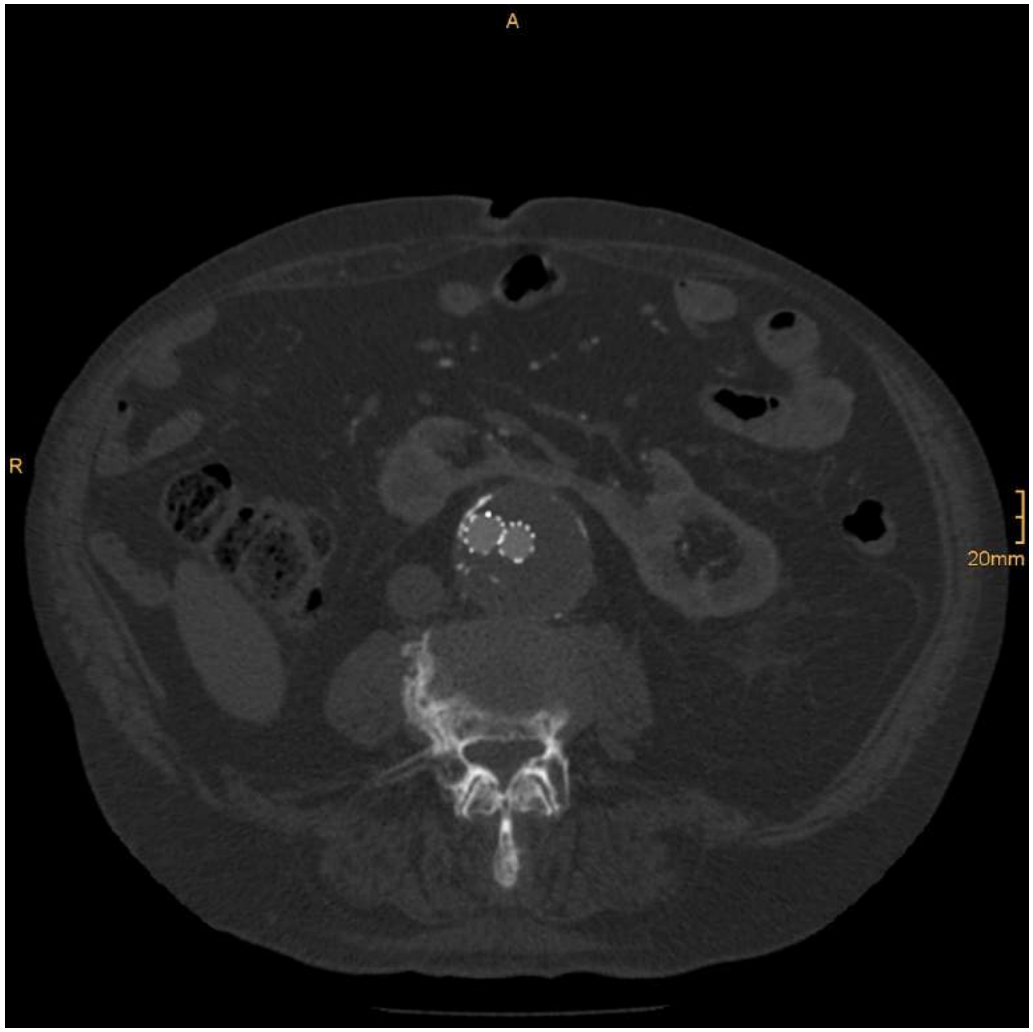
A
R
20mm

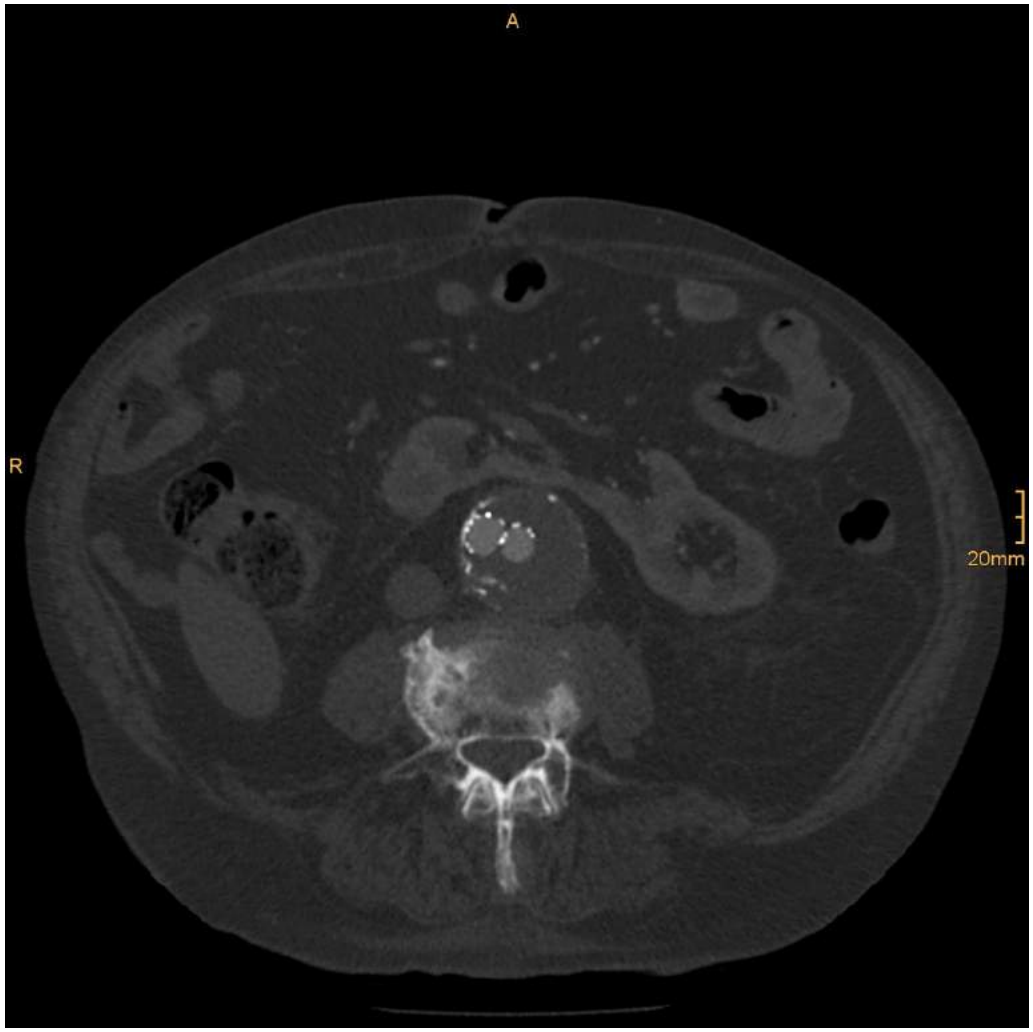
A
R
20mm

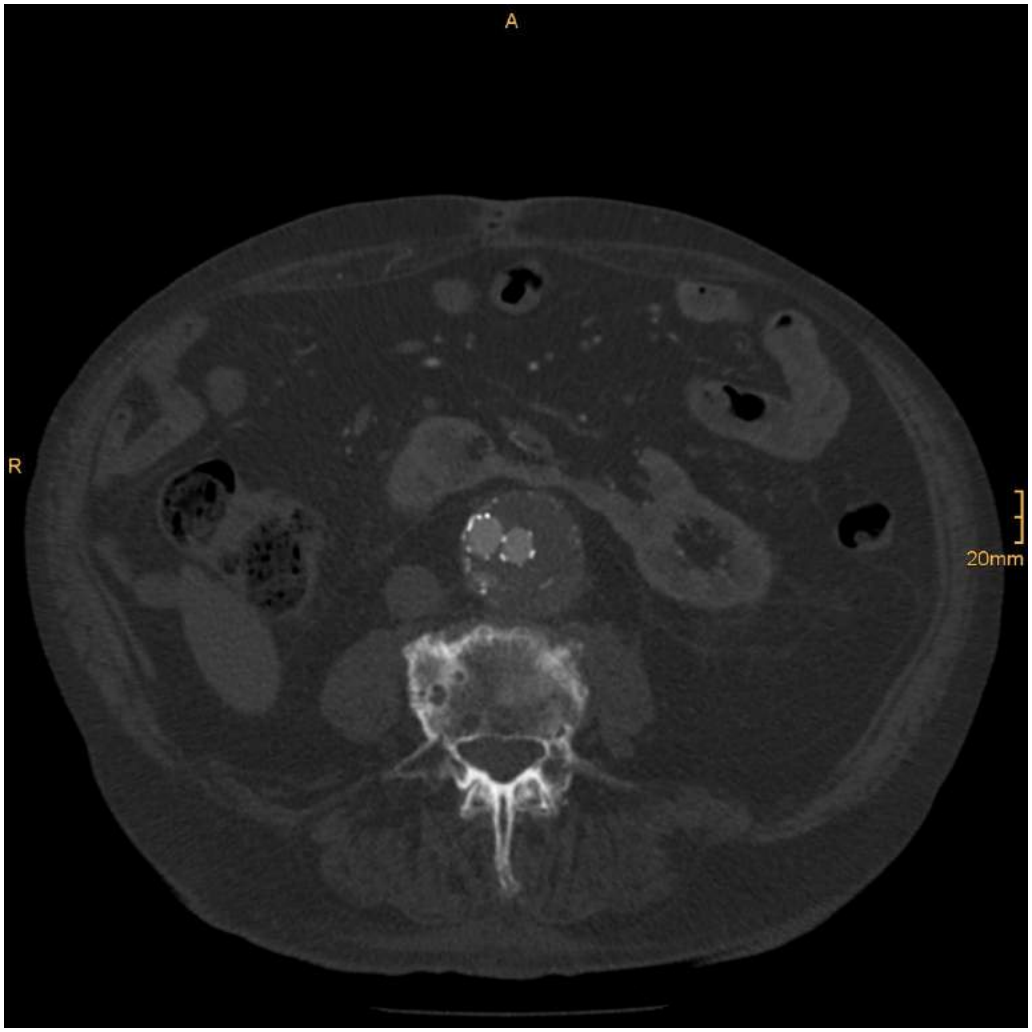
A
R
20mm


A
R
20mm

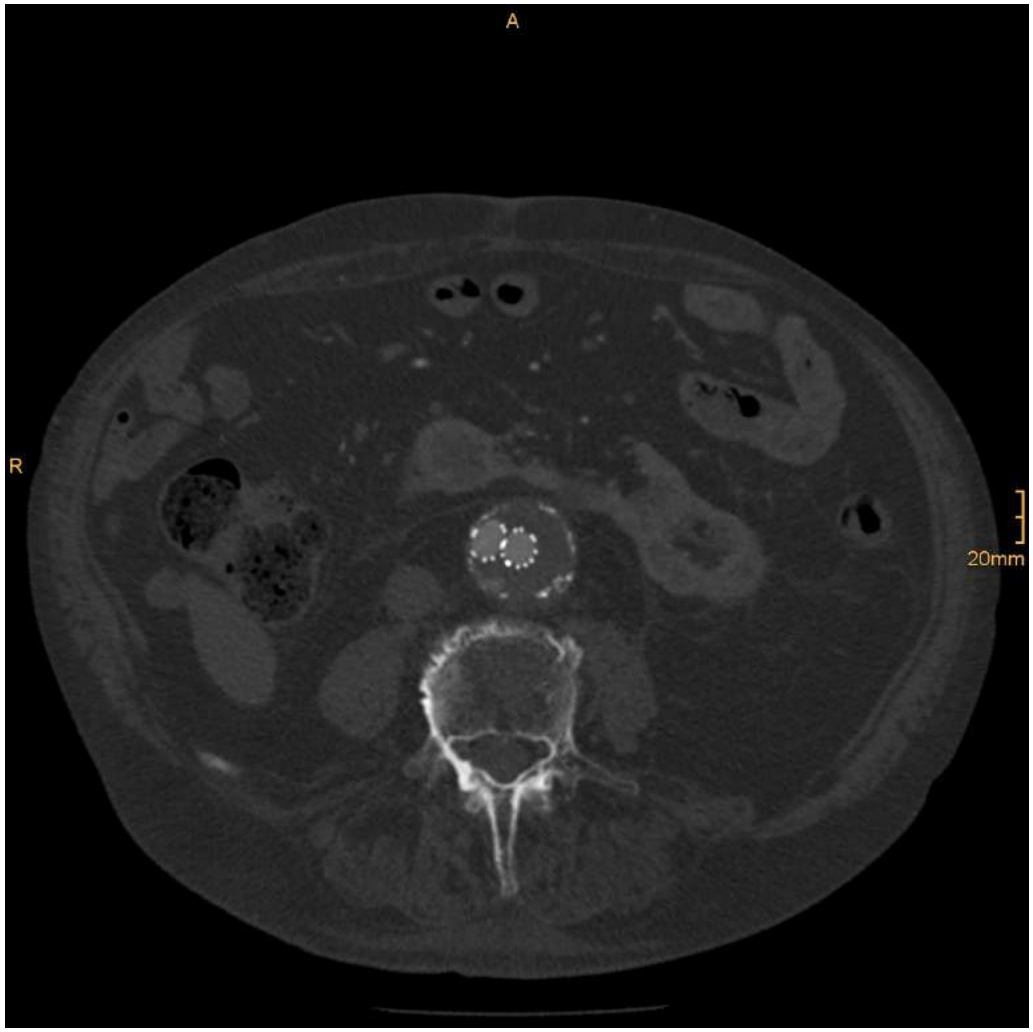
A
R
20mm

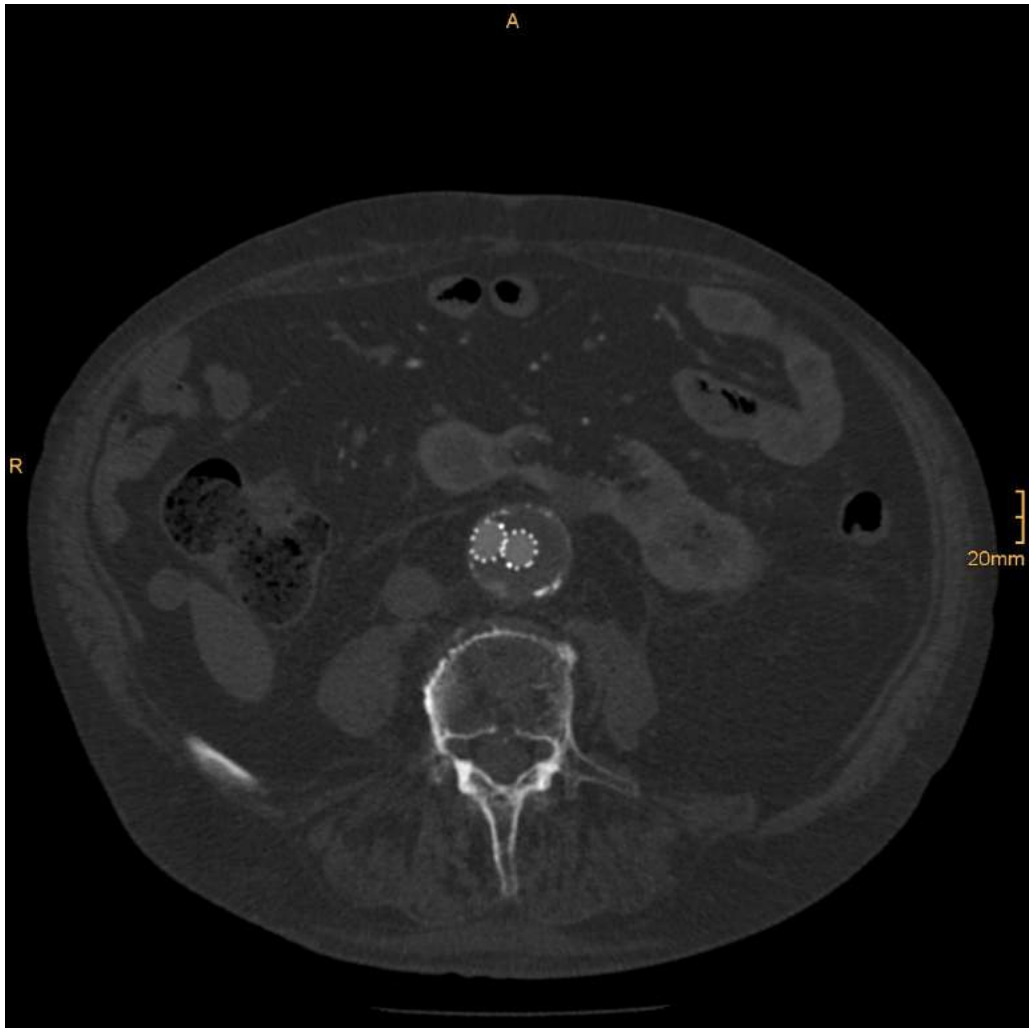
A
R
20mm

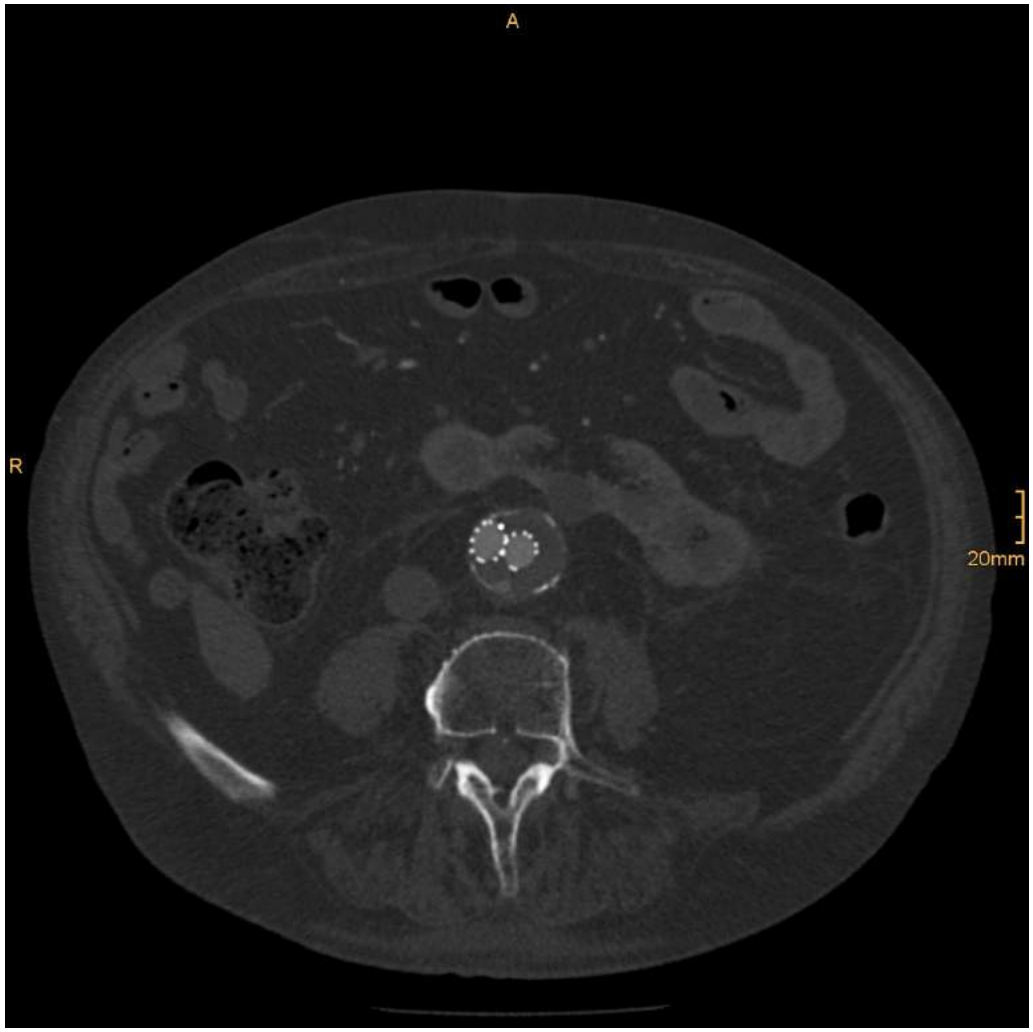
A
R
20mm

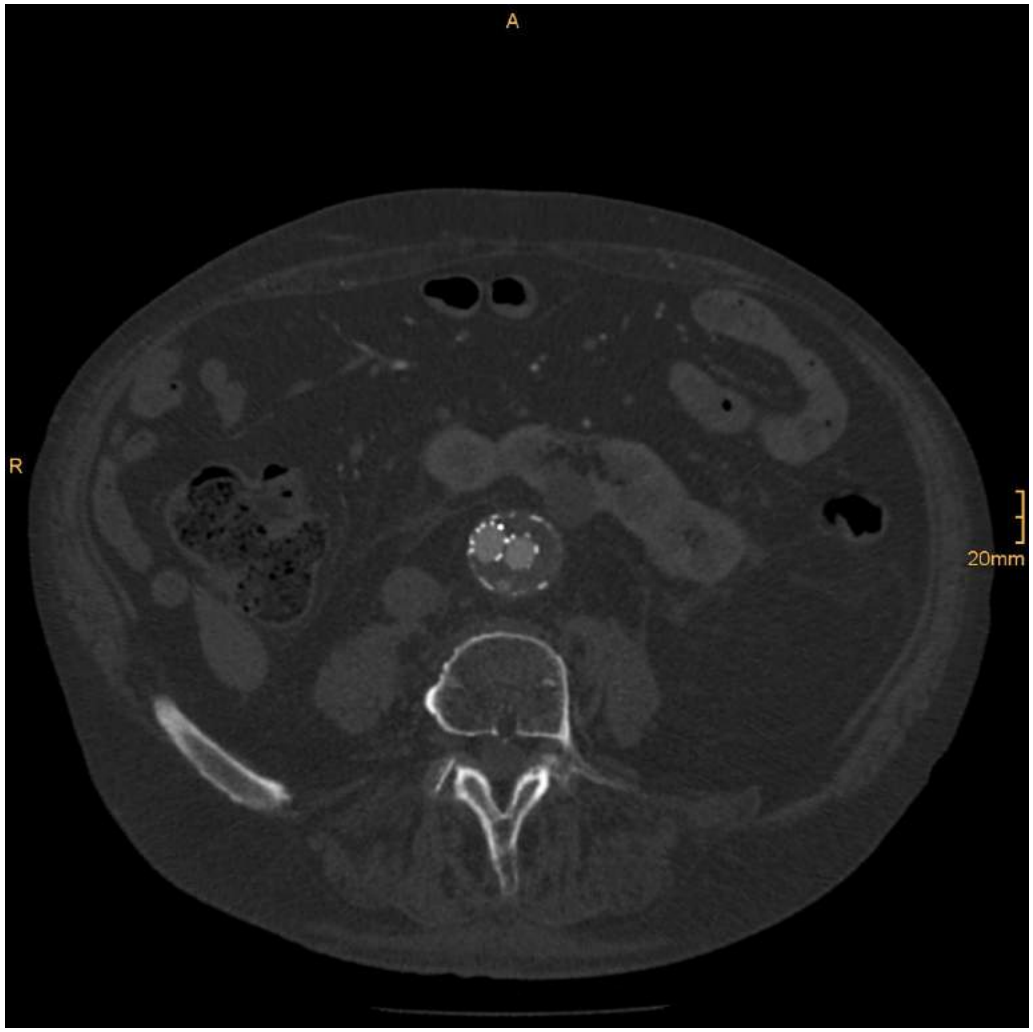
A
R
20mm


A
R
20mm

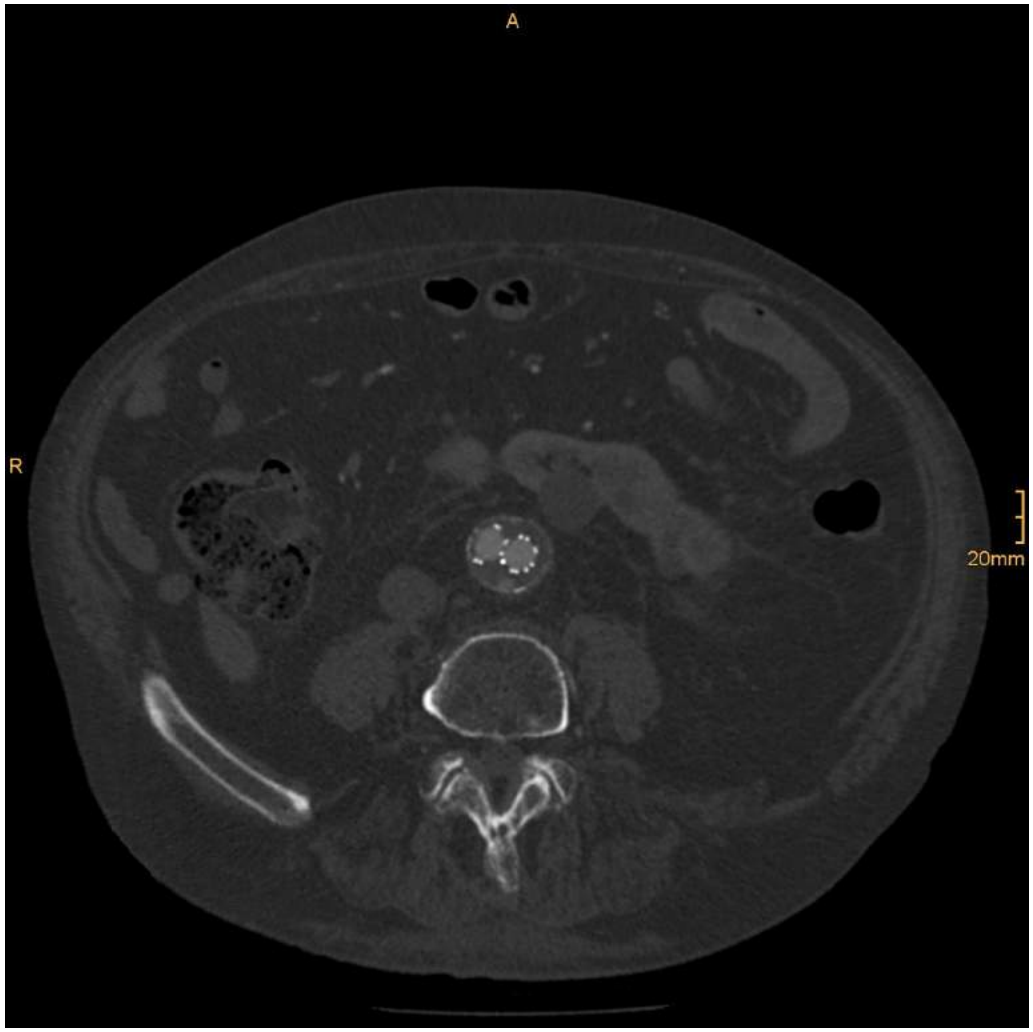
A
R
20mm

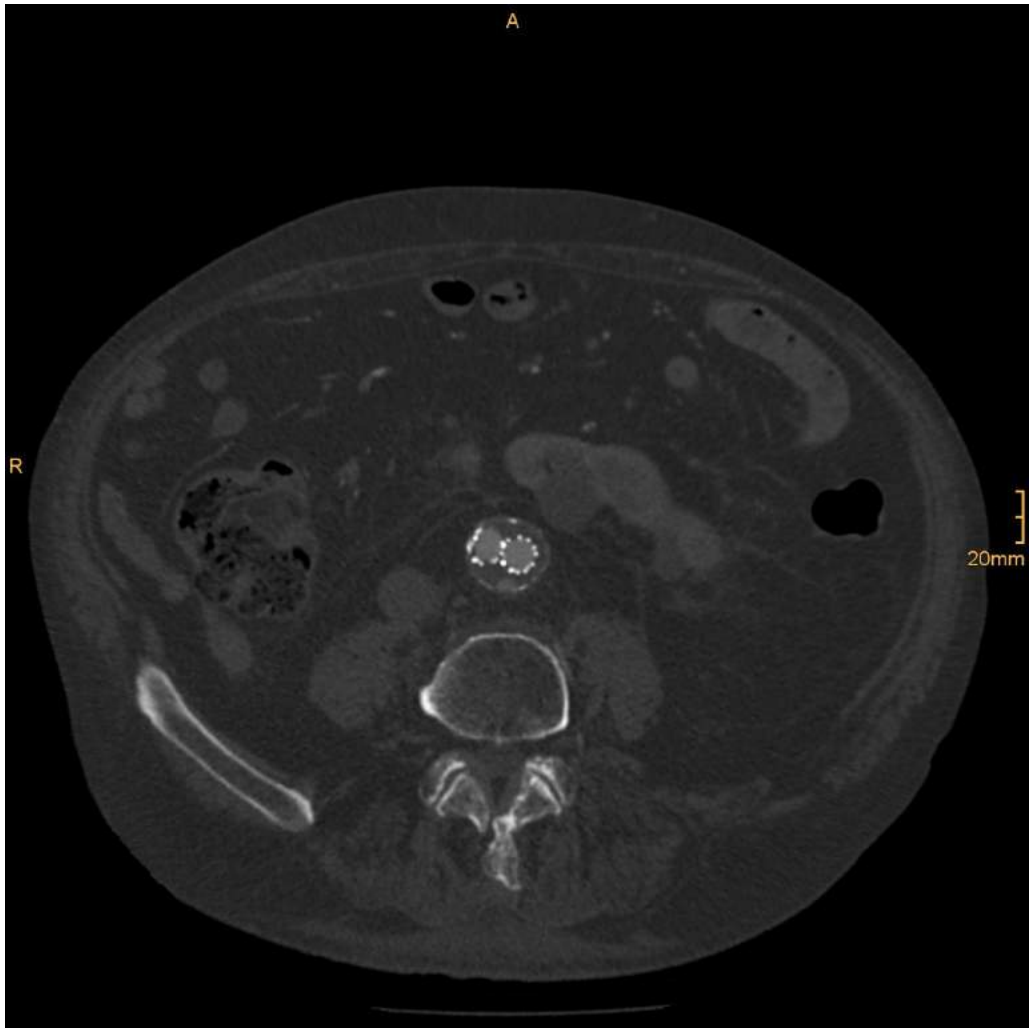
A
R
20mm


A
R
20mm


A
R
20mm

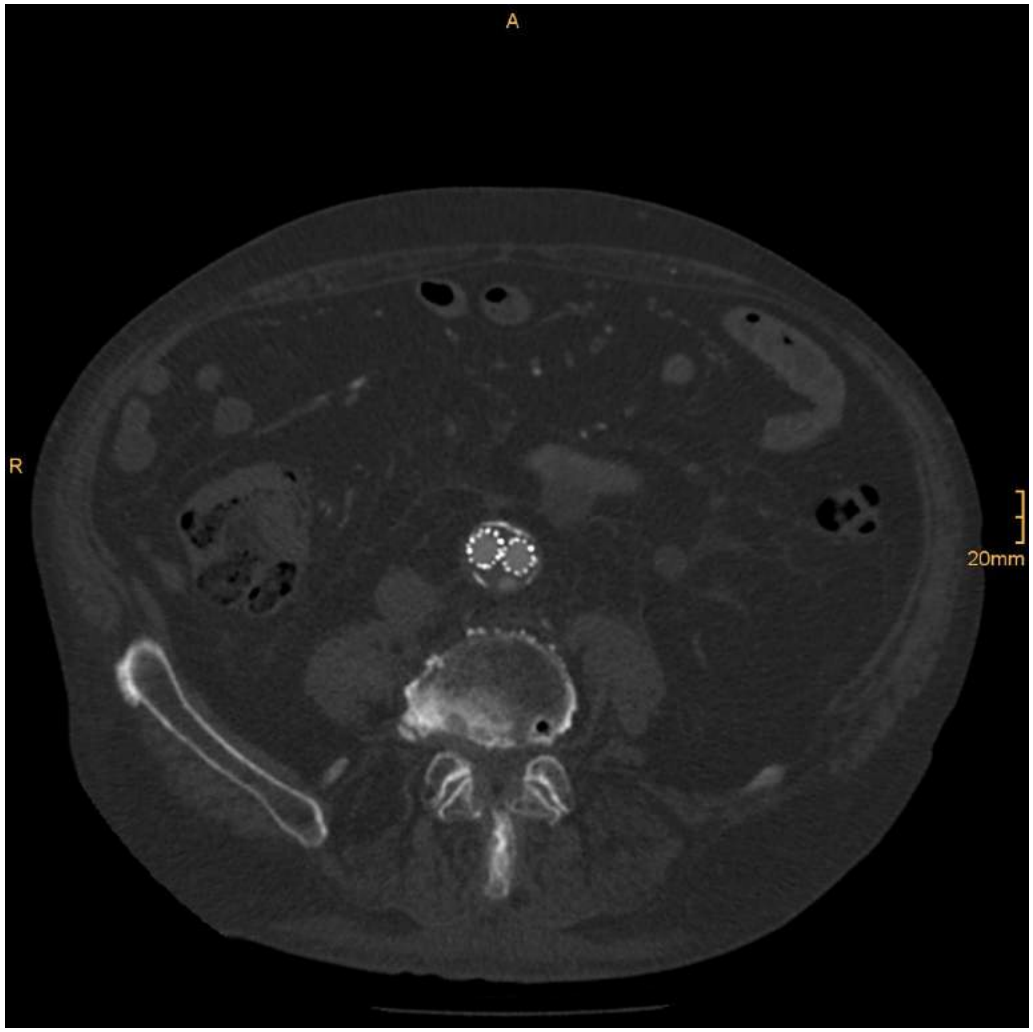
A
R
20mm

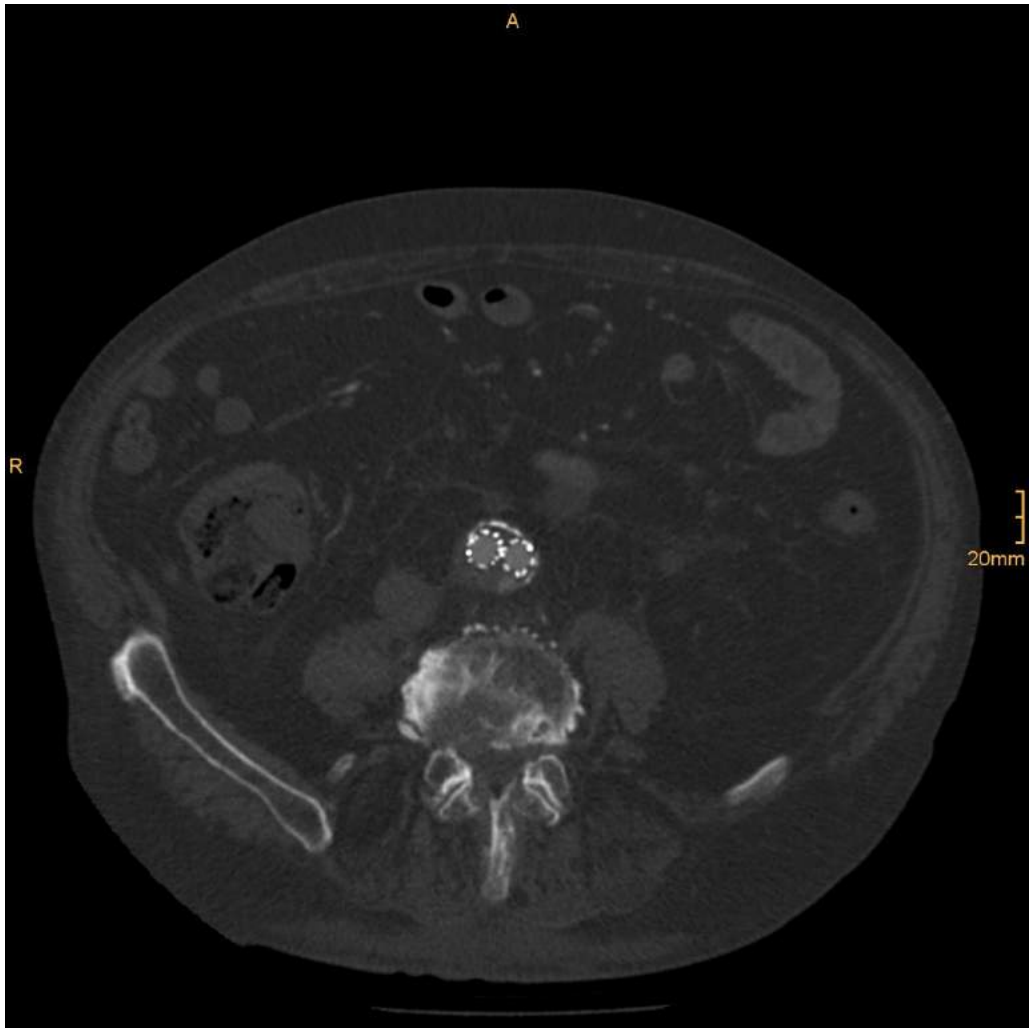
A
R
20mm

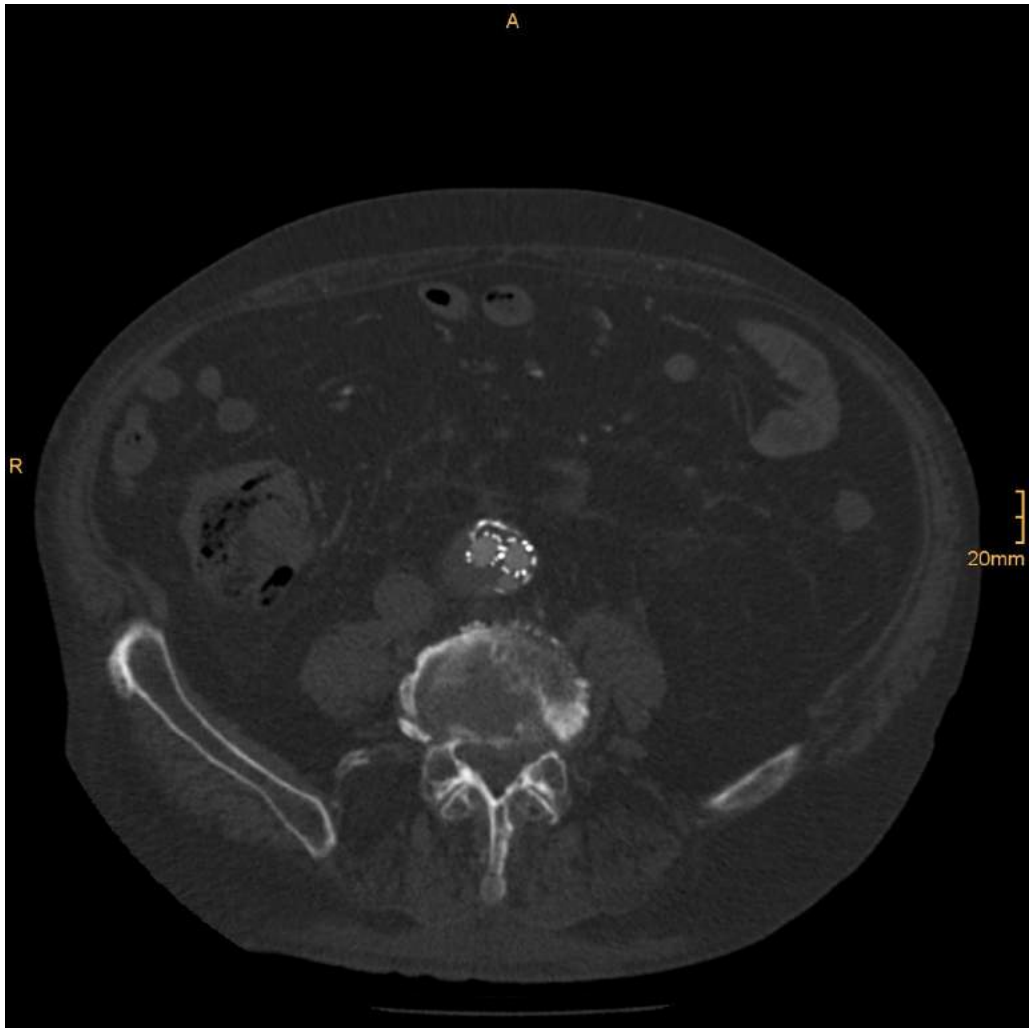
A
R
20mm


A
R
20mm


A
R
20mm


A
R
20mm


A
R
20mm

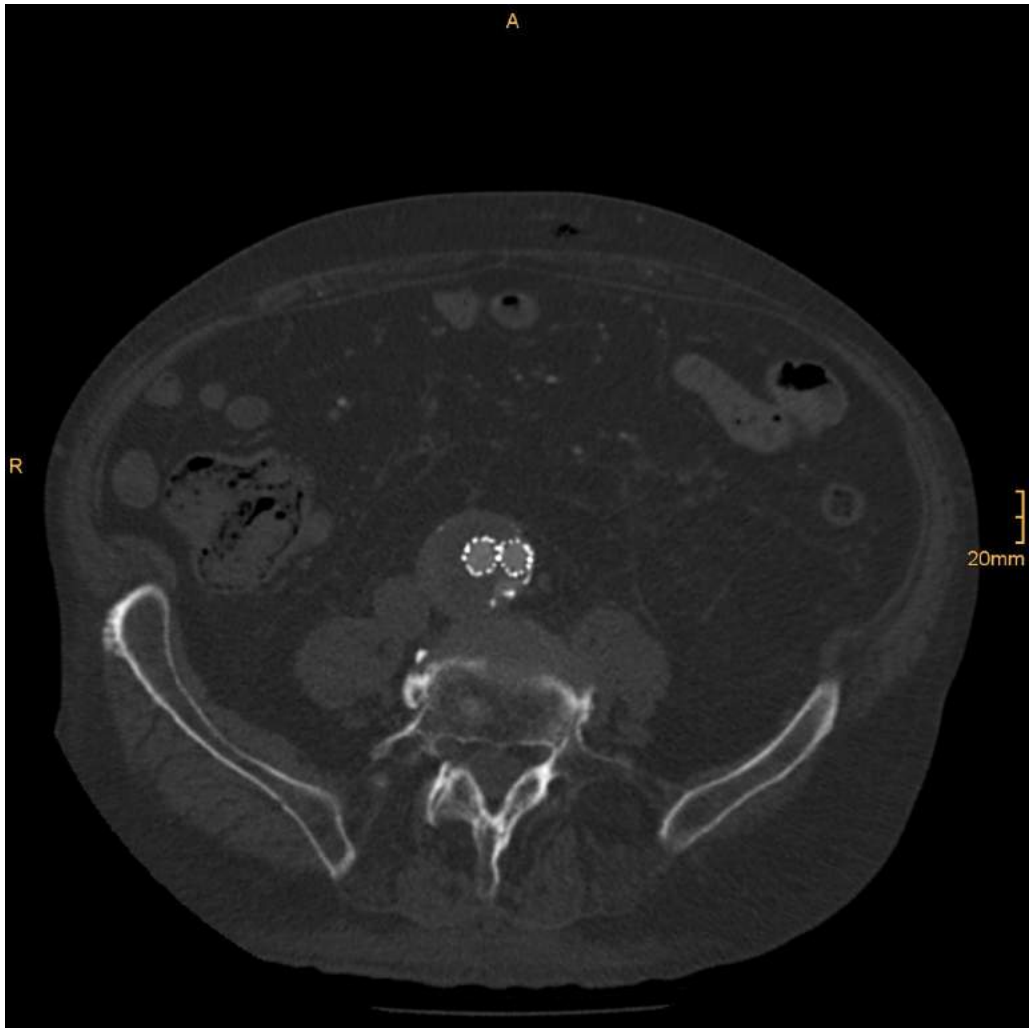
A
R
20mm


A
R
20mm

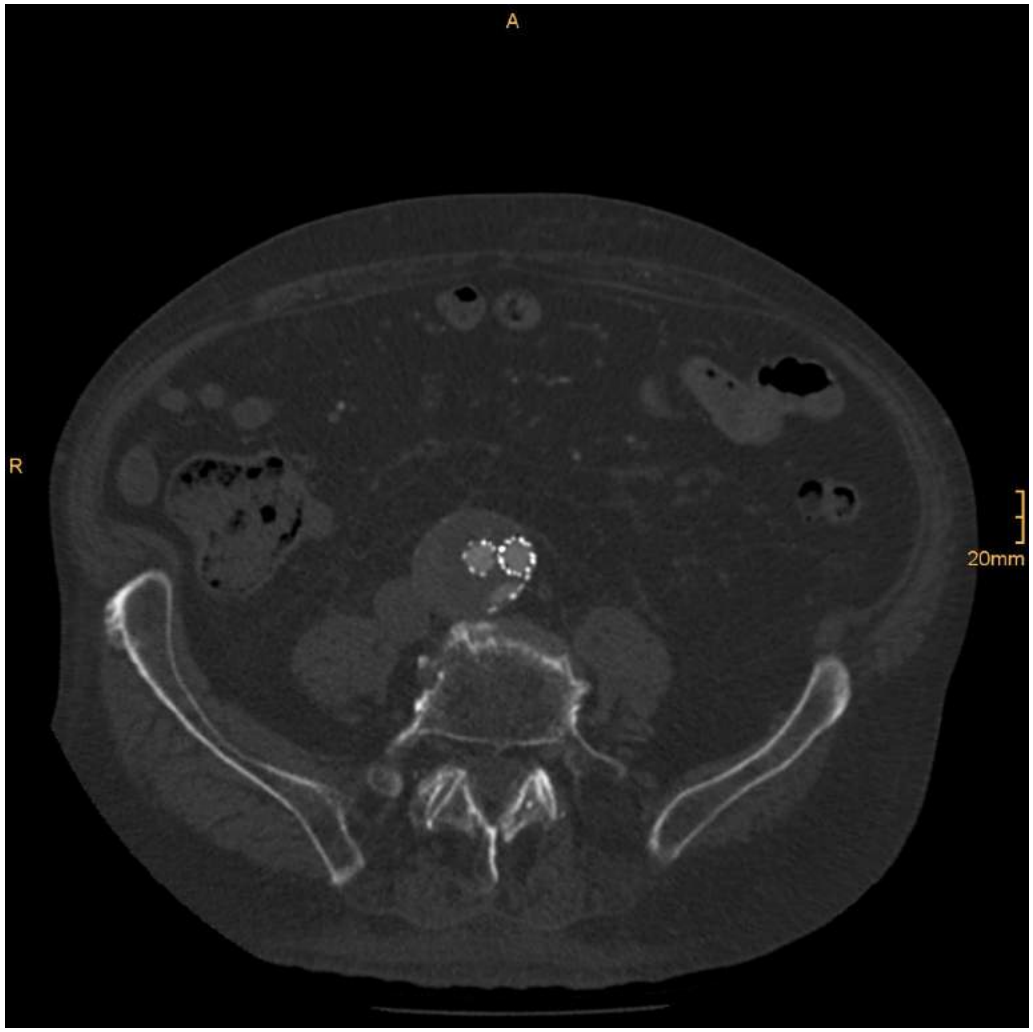
A
R
20mm

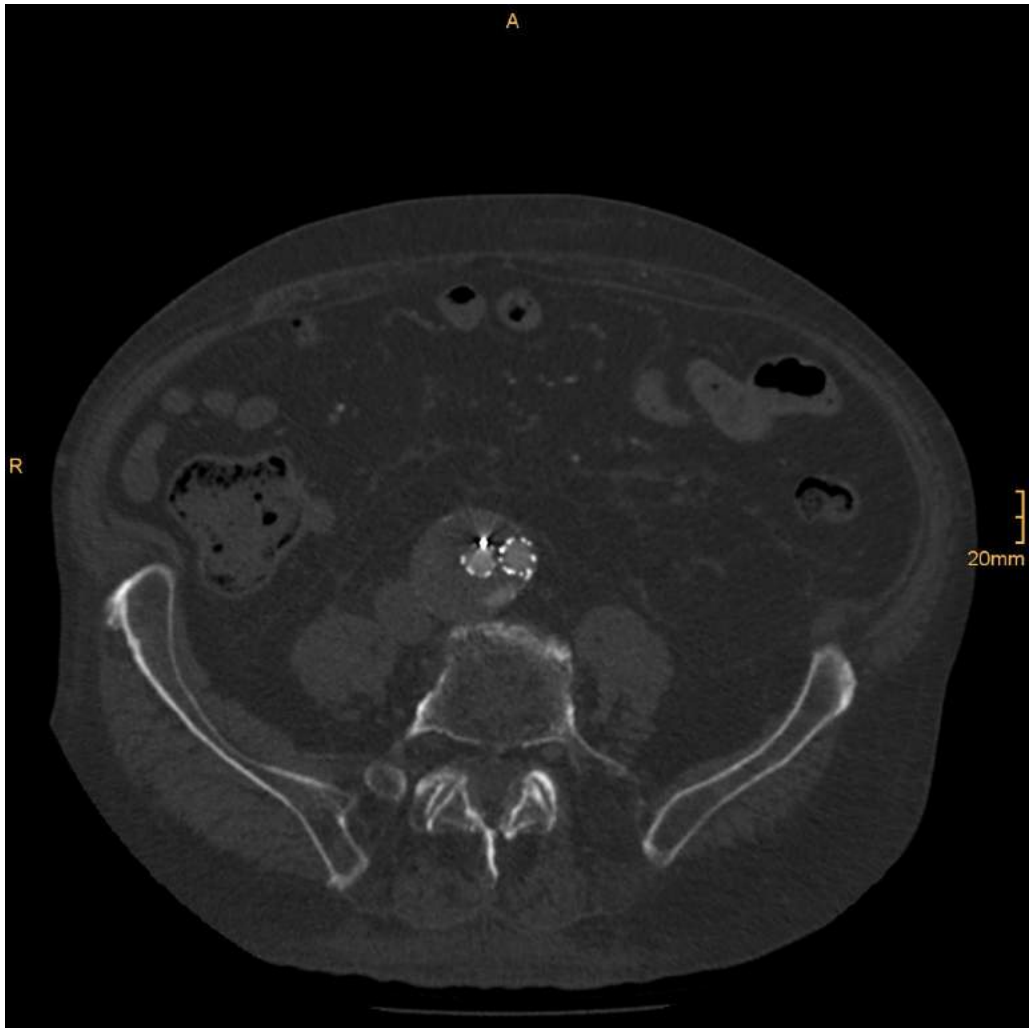
A
R
20mm


A
R
20mm


A
R
20mm


A
R
20mm


A
R
20mm


A
R
20mm


A
R
20mm

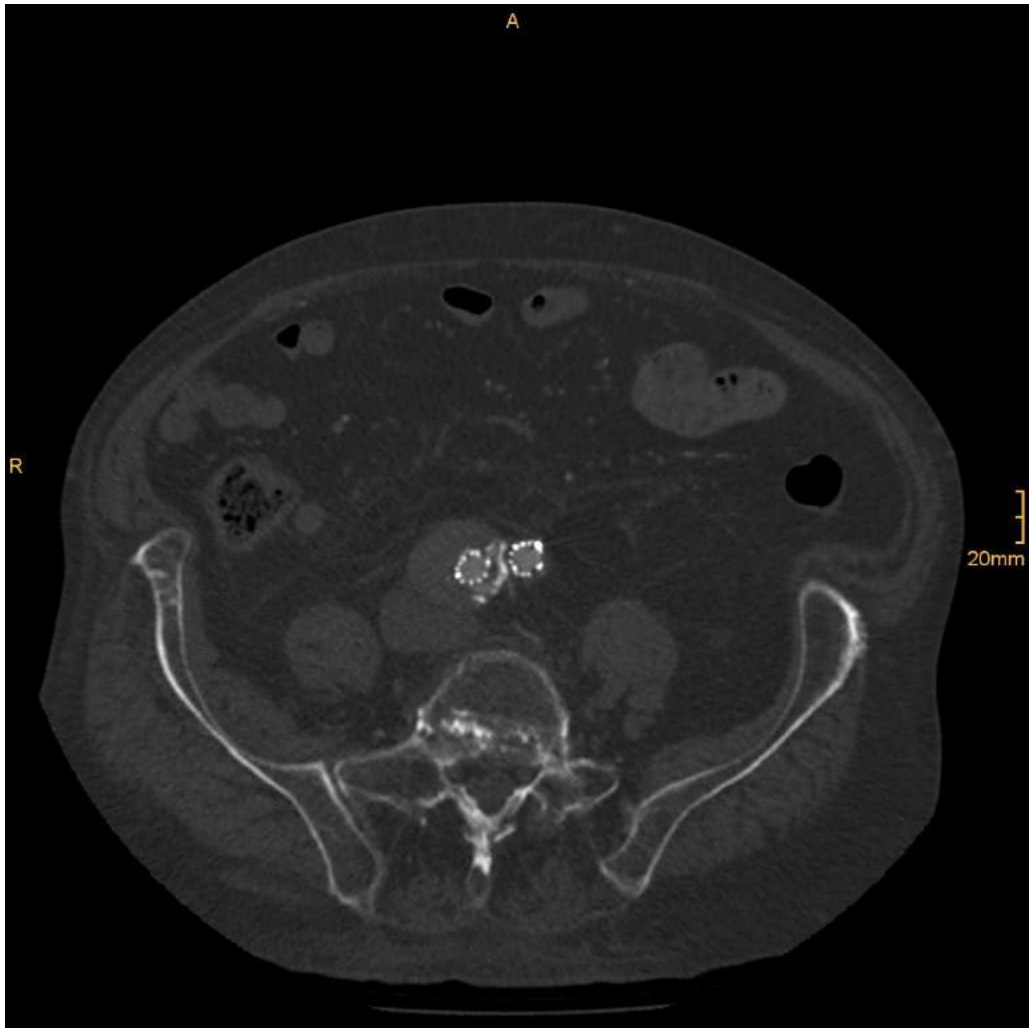
A
R
20mm


A
R
20mm


A
R
20mm


A
R
20mm


A
R
20mm

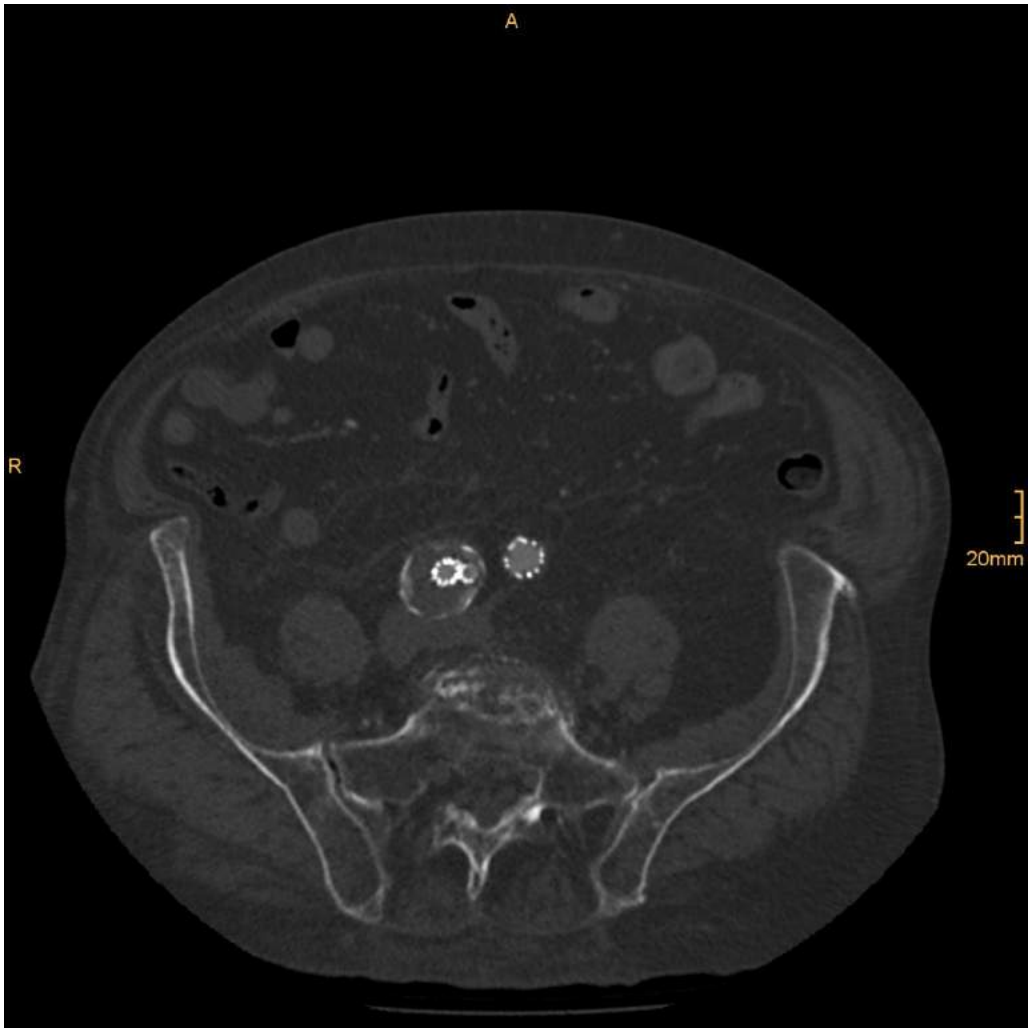
A
R
20mm

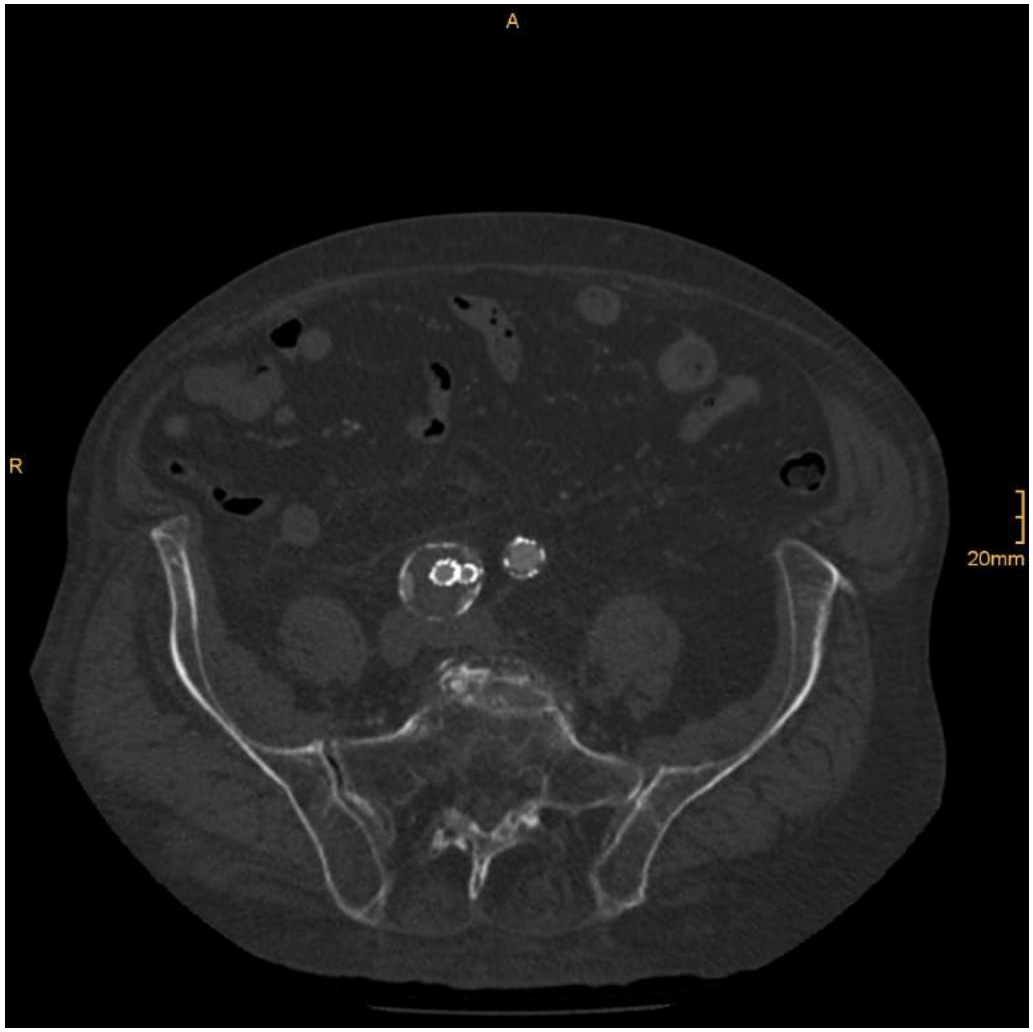
A
R
20mm

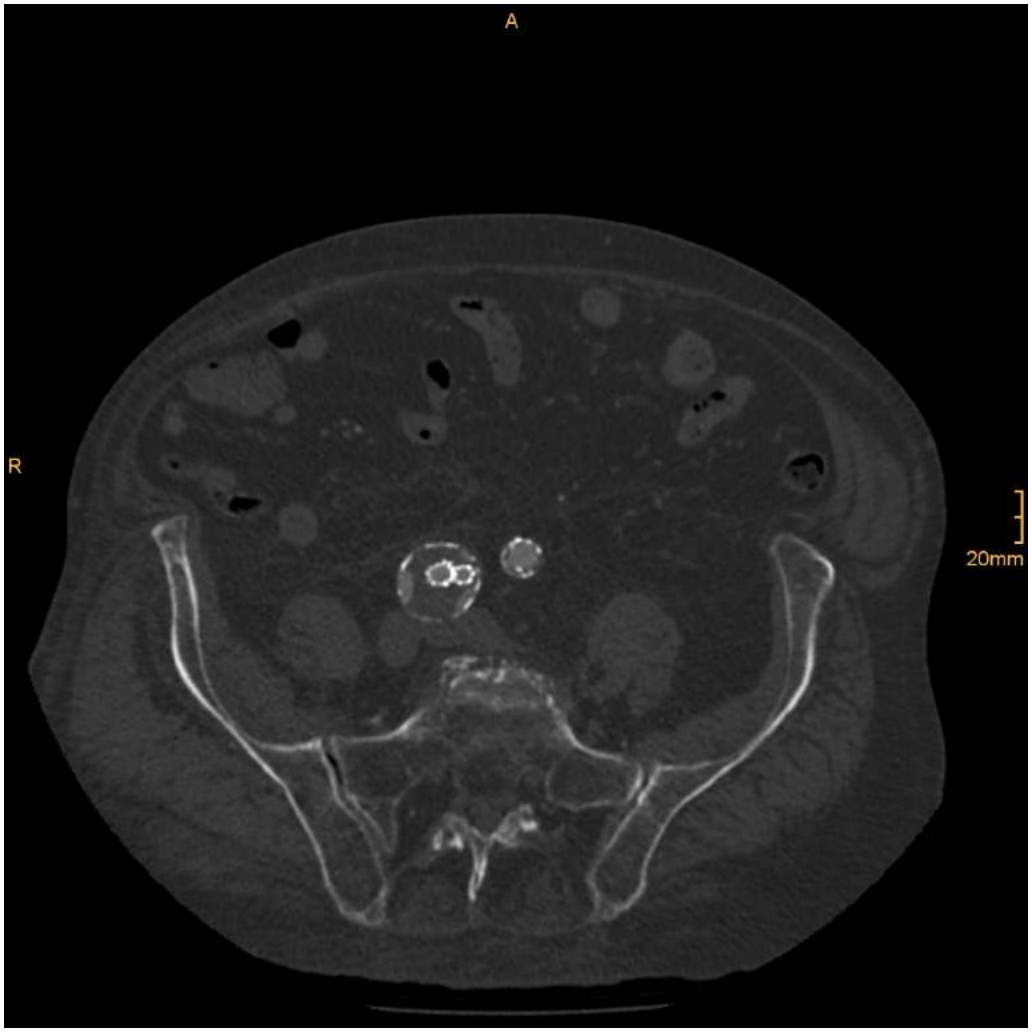
A
R
20mm


A
R
20mm


A
R
20mm


A
R
20mm


A
R
20mm


A
R
20mm


A
R
20mm


A
R
20mm


A
R
20mm


A
R
20mm


A
R
20mm


A
R
20mm


A
R
20mm


A
R
20mm


A
R
20mm


A
R
20mm


A
R
20mm


A
R
20mm

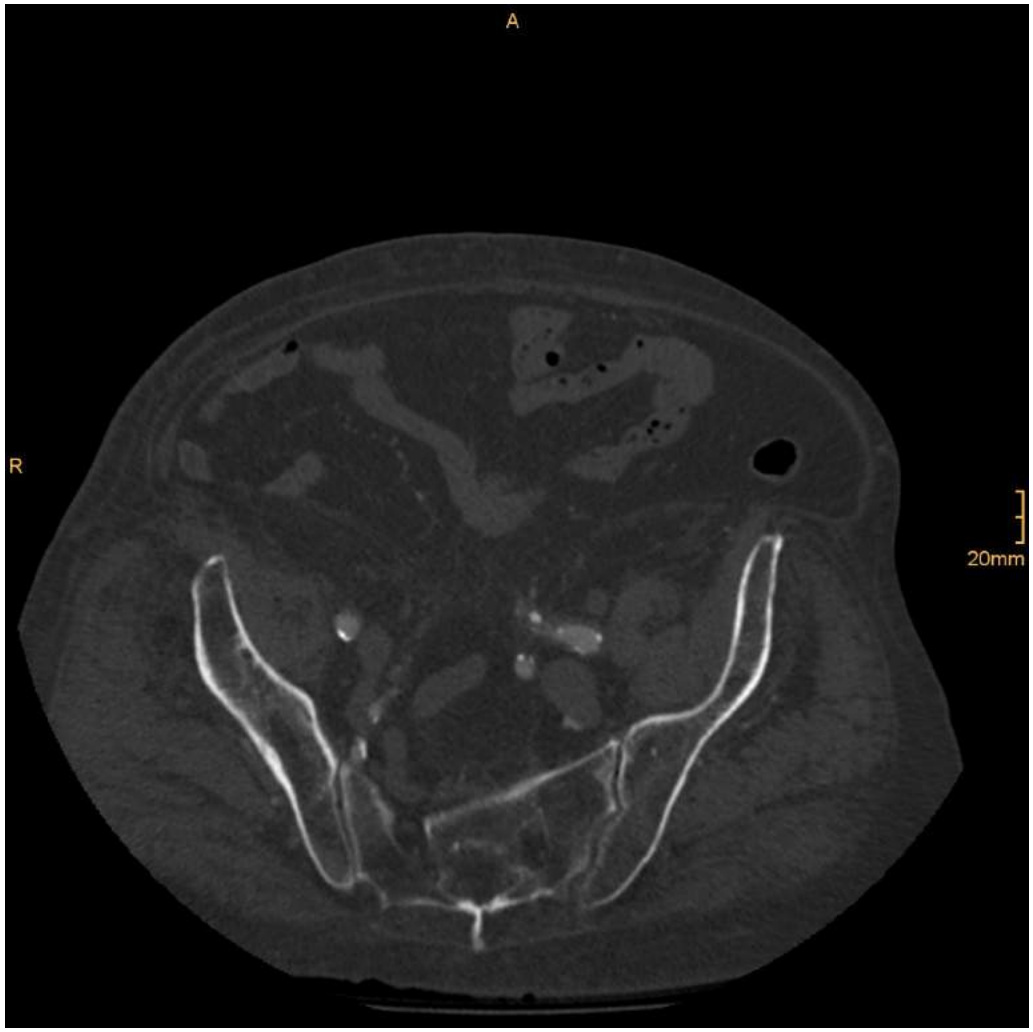
A
R
20mm

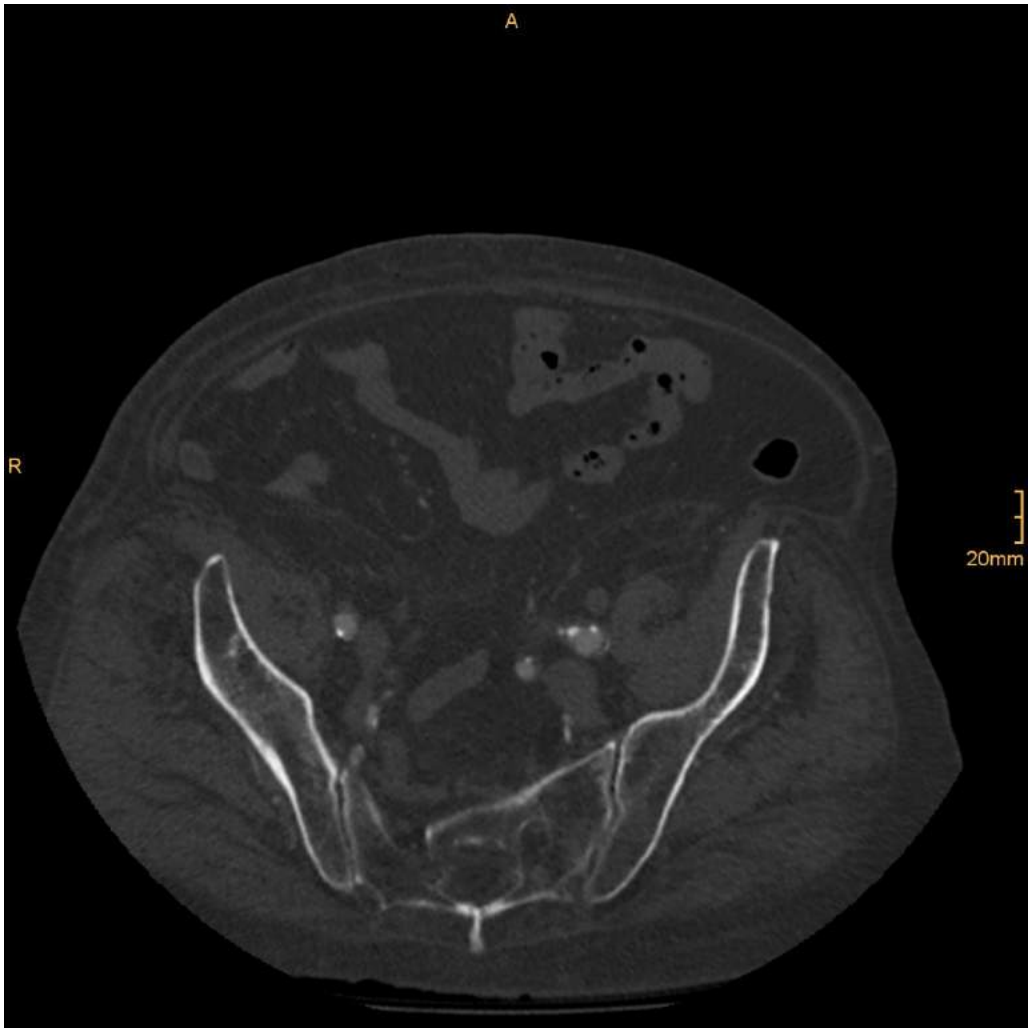
A
R
20mm

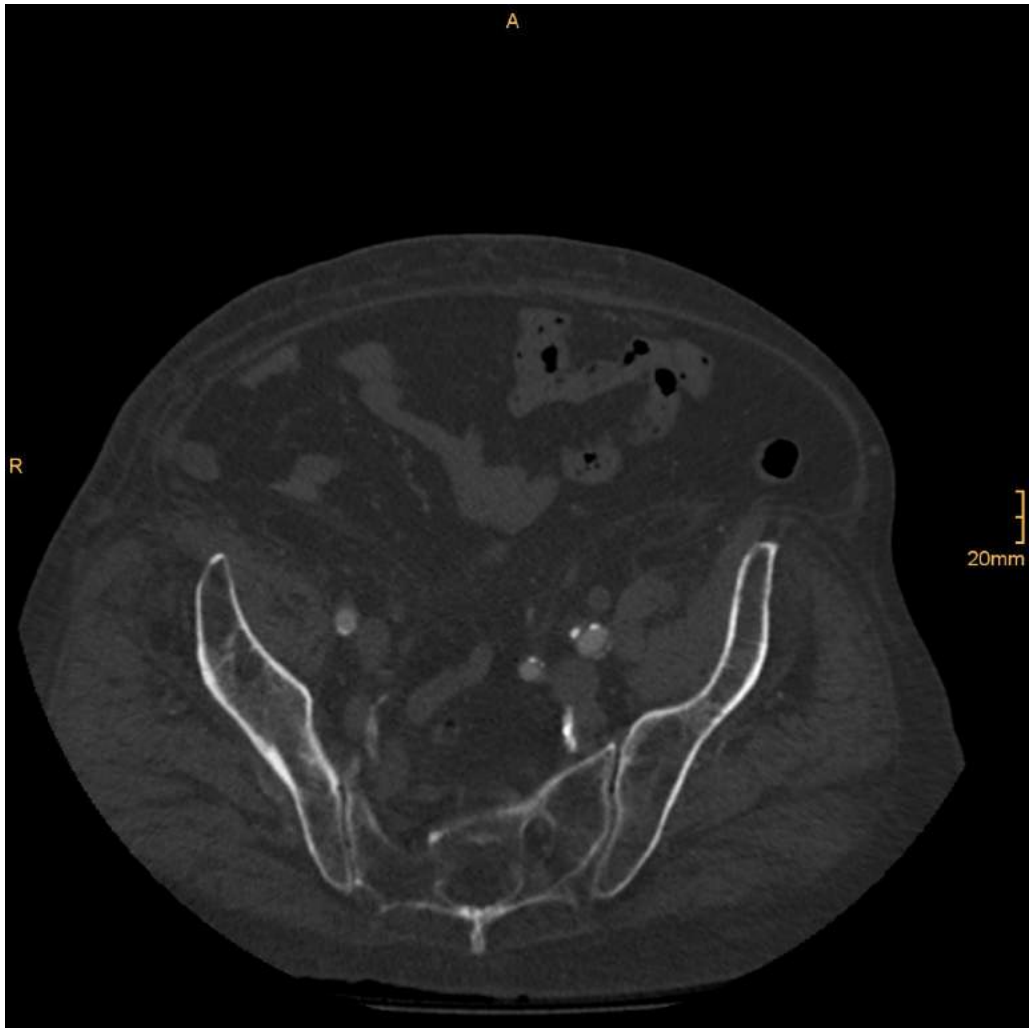
A
R
20mm

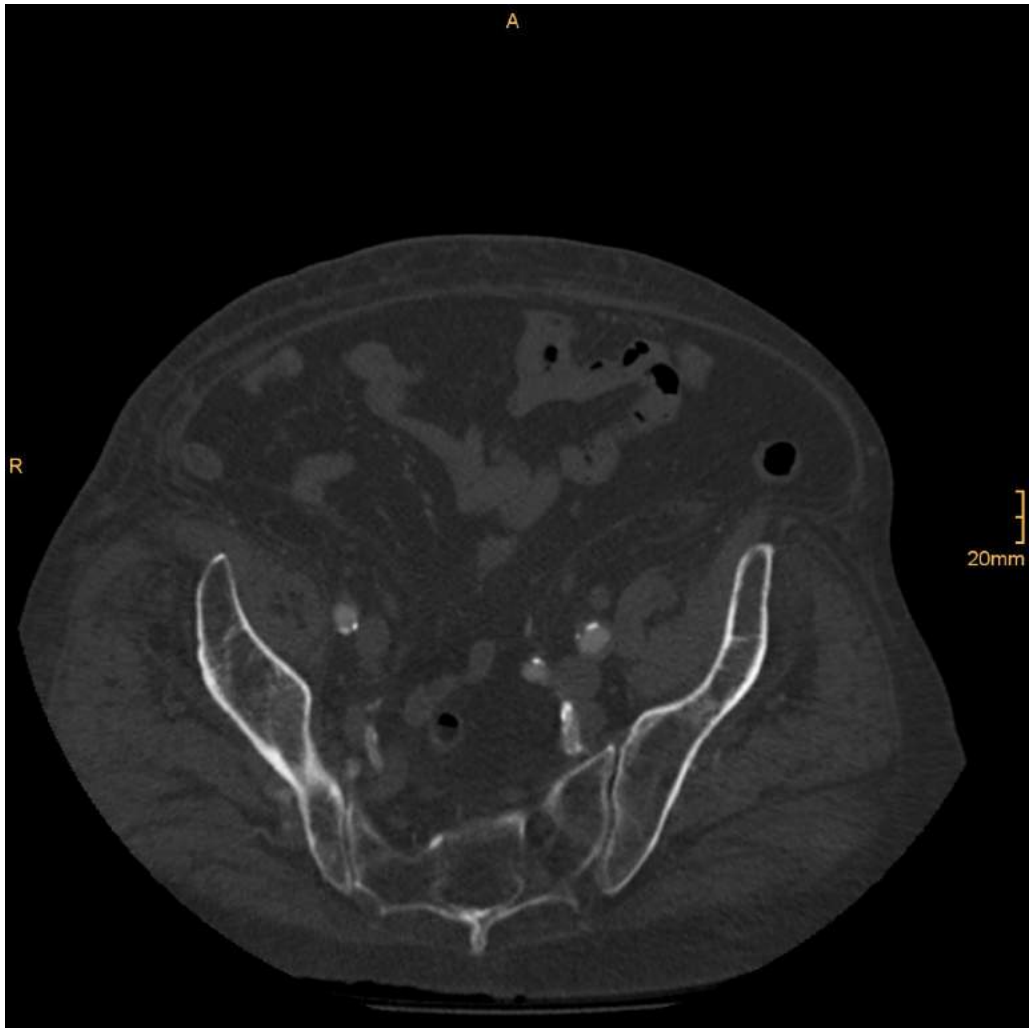
A
R
20mm

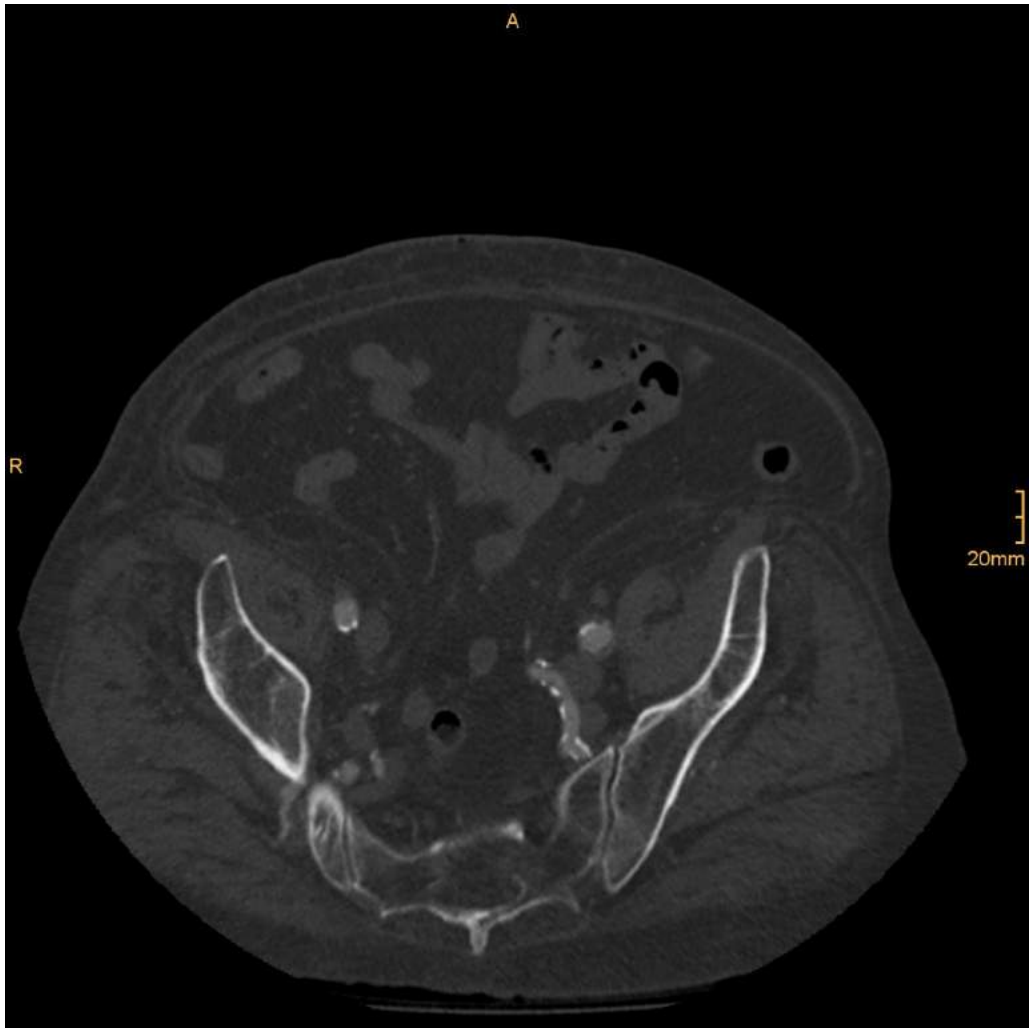
A
R
20mm


A
R
20mm


A
R
20mm

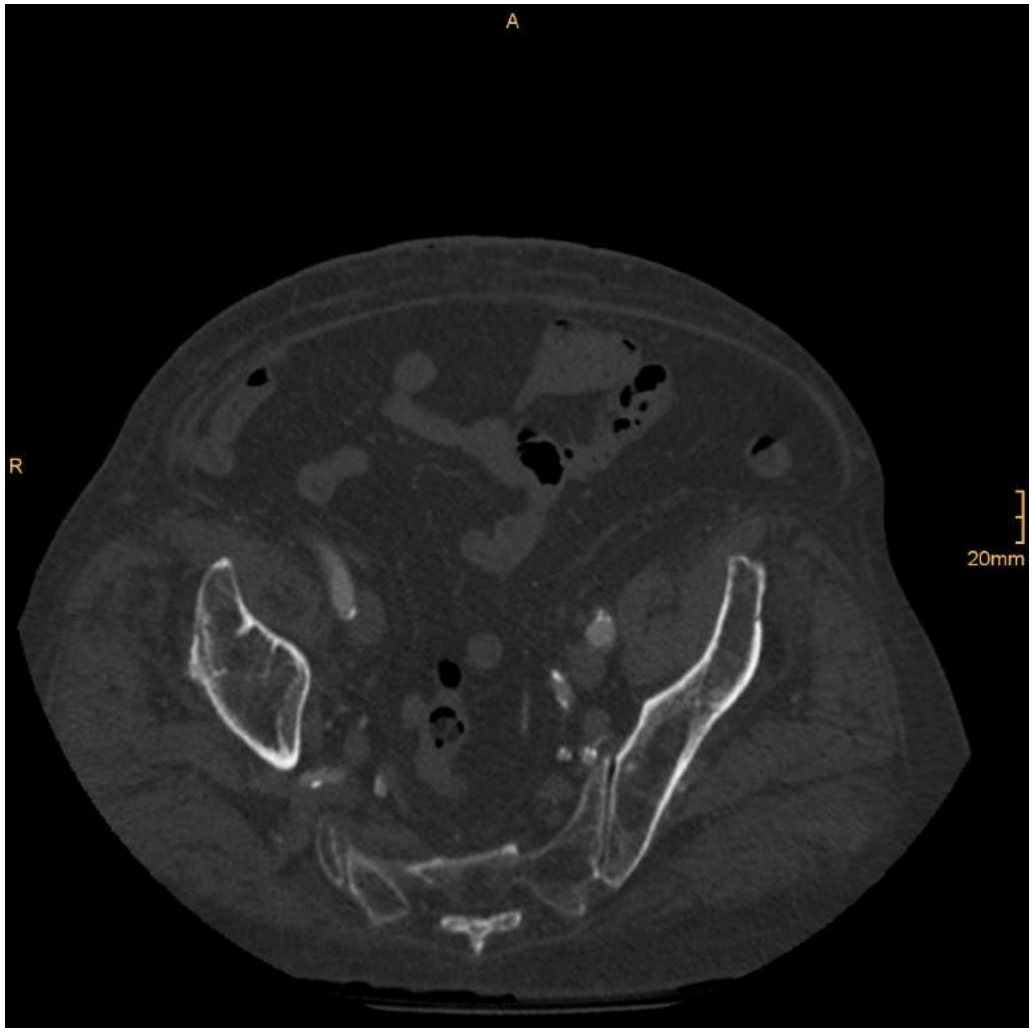
A
R
20mm

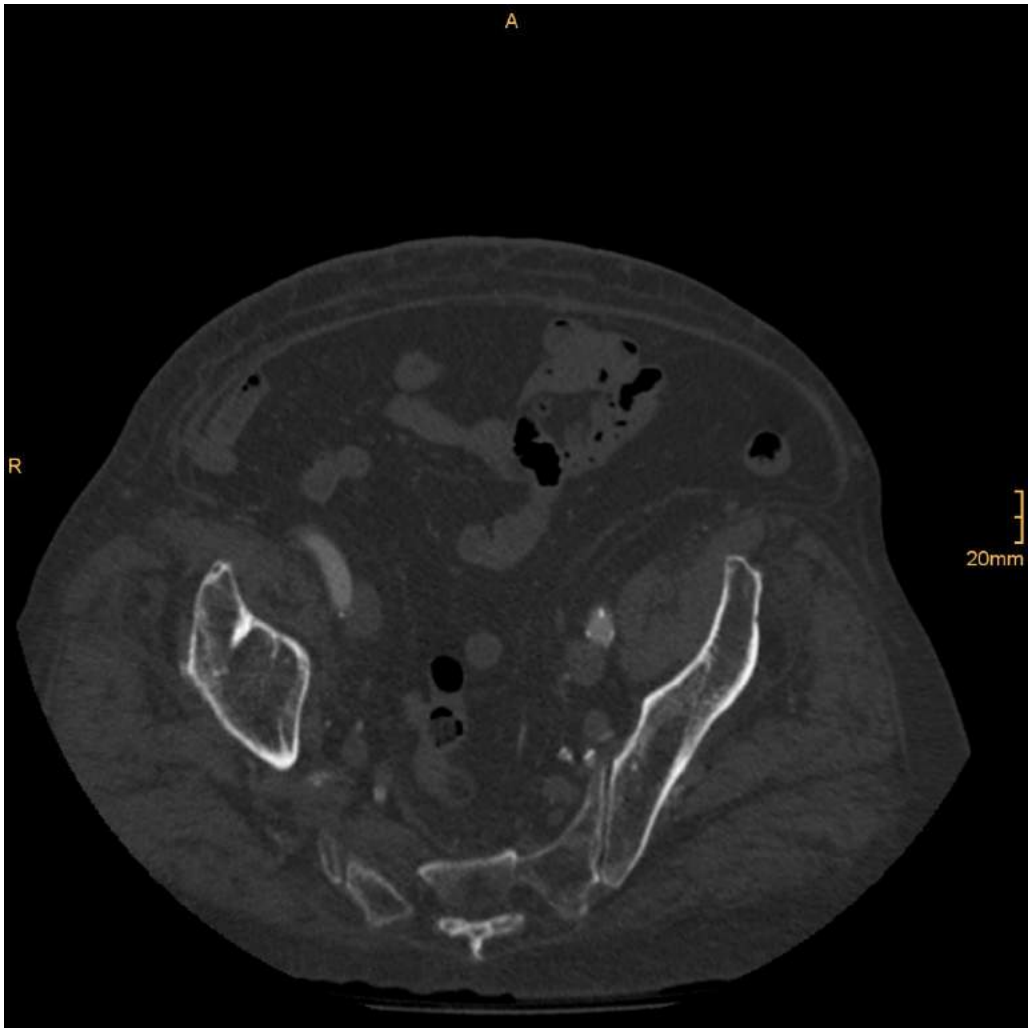
A
R
20mm

Niels-Stensen-Kliniken
Marienhospital Osnabrück

Own Data

- **N=7 (Male)**
- **Follow up: 26.8 Months (8-36 Months)**
- **Age: 76±10,4**
- **Technical Success: 100%**

•Follow Up:

- **No significant Endoleak**
- **No significant Migration**
- **No Occlusion**
- **No Deaths**

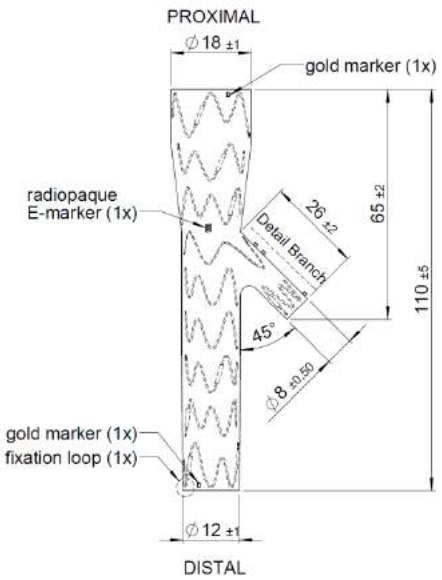

Niels-Stensen-Kliniken
Marienhospital Osnabrück

Basic Measurements

Country: Germany
City: Osnabrück
Hospital: Marienhospital
Doctor: Prof. Heckenkamp
Initials: M.W.
Birthday: 26.10.1937
Design: JME

E-xtra DESIGN ENGINEERING

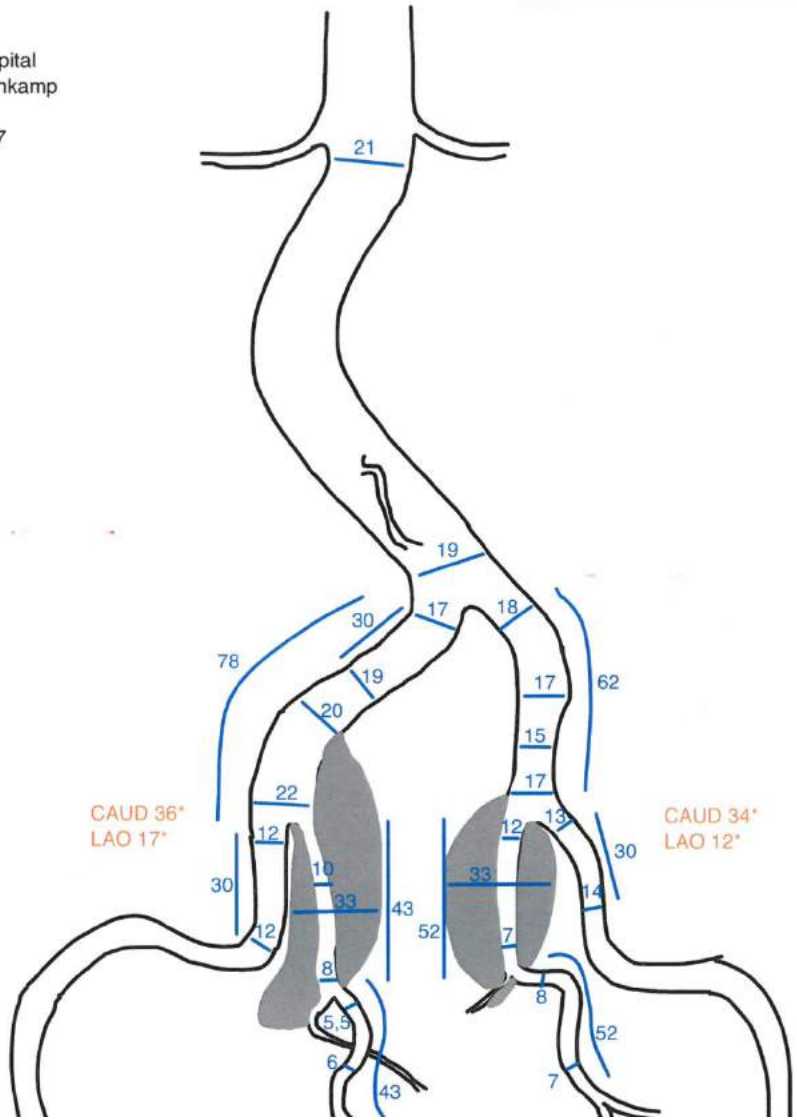

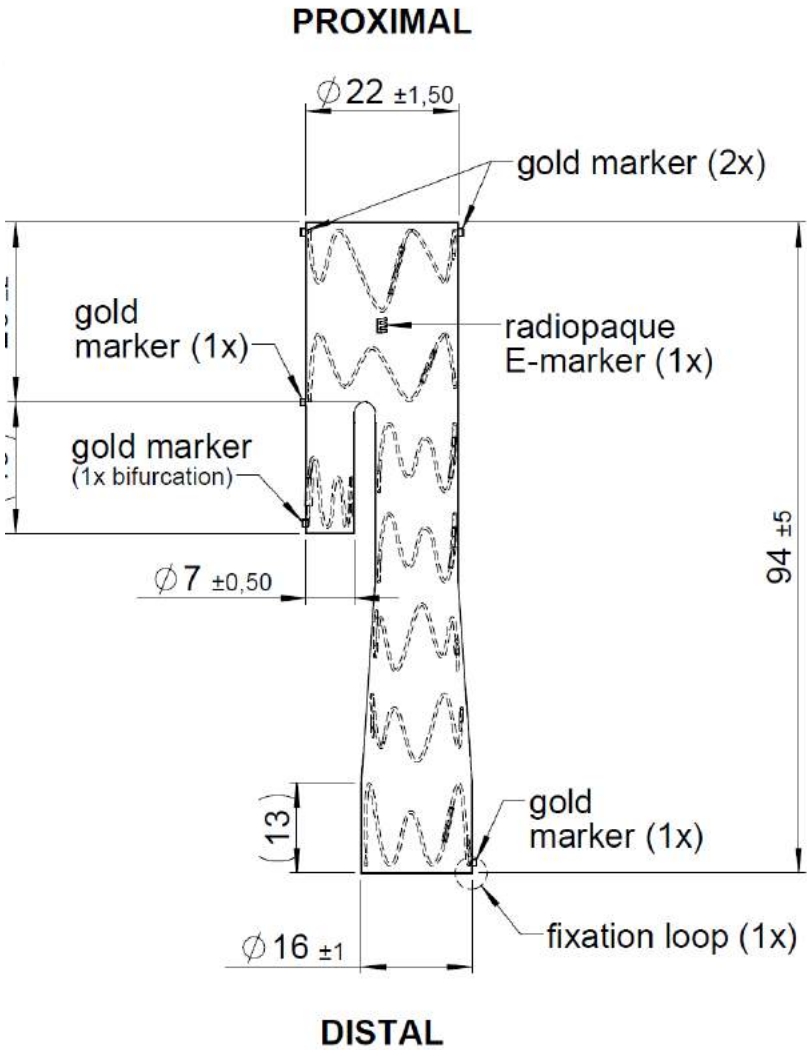

Summary

- **Pelvic Flow should be sustained**
- **Attractive alternative to open surgery**
  - **Is or will become Goldstandard**
- **E-liac fits for most anatomies**
  - **High 3D flexibility without kinking**
  - **Easy to use**
  - **Promising data**
- **Custom made solutions possible**
  - **Promising Data (Small Series)**