ZONE 2 ARCH REPAIR WITH GORE THORACIC BRANCH ENDOPROSTHESIS

Bernardo C. Mendes MD
Edward D. Gifford MD
Gustavo S. Oderich MD

Division of Vascular and Endovascular Surgery
Mayo Clinic, Rochester

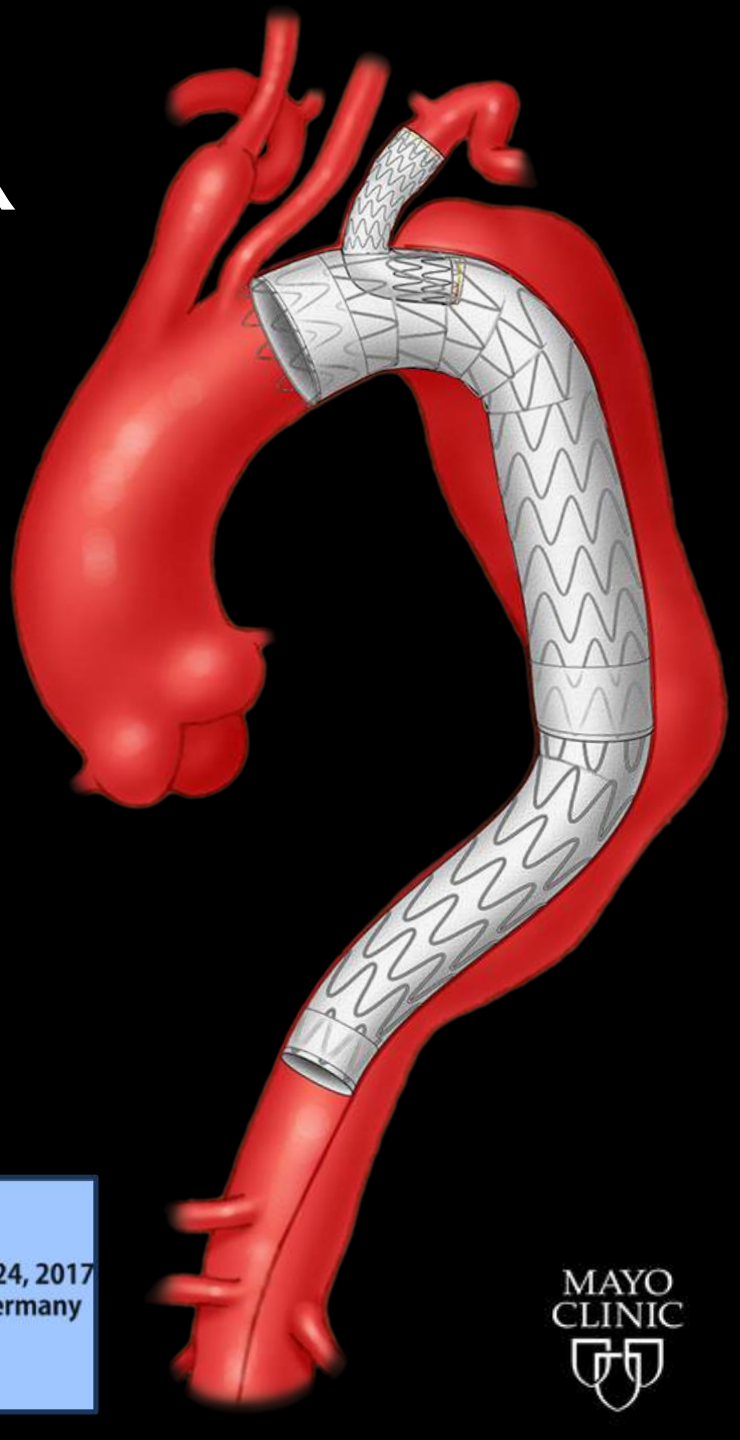

AORTIC LIVE 2017
October 23–24, 2017
Hamburg, Germany

MAYO CLINIC

FACULTY **DISCLOSURES**

Gustavo Oderich MD

- Consulting*
  Cook Medical Inc., WL Gore, Bolton Medical, GE, Synthax
- Research grants*
  Cook Medical Inc., WL Gore, Atrium Maquet
- Investigational, off-label use of devices
  Cook Fenestrated and Branched Grafts, Gore Branched Technology

* All consulting fees and research educations grants paid to Mayo Clinic

MAYO CLINIC

CASE **PRESENTATION**

- 73M with chronic type B aortic dissection
- Aneurysmal degeneration of thoracic aorta
- Recurrent admissions for chest pain
- Cardiovascular risk factors
  - Hypertension
  - Hyperlipidemia
  - Previous smoker

MAYO CLINIC

PREOPERATIVE **ASSESSMENT**

- Sestamibi scan negative for ischemia
- ECG with first degree AV block, sinus bradycardia
- EF 60%
- FEV 1 2.7L
- Serum creatinine 1.6 mg/dL
- Hemoglobin 14.2 g/dL

MAYO CLINIC

PHYSICAL **EXAM**

- Vitals HR 61 RR 16 T 36.3 BP 120/69
- General No acute distress
- Heart RRR, no gallop, no murmurs
- Lungs Clear bilaterally
- Abdomen Nontender, no palpable pulsatile mass
- Pulses

	Radial	Brachial	Carotid	Fem	Pop	DP	PT
R	4+	4+	4+	3+	3+	2+	3+
L	4+	4+	4+	3+	3+	2+	3+

MAYO CLINIC

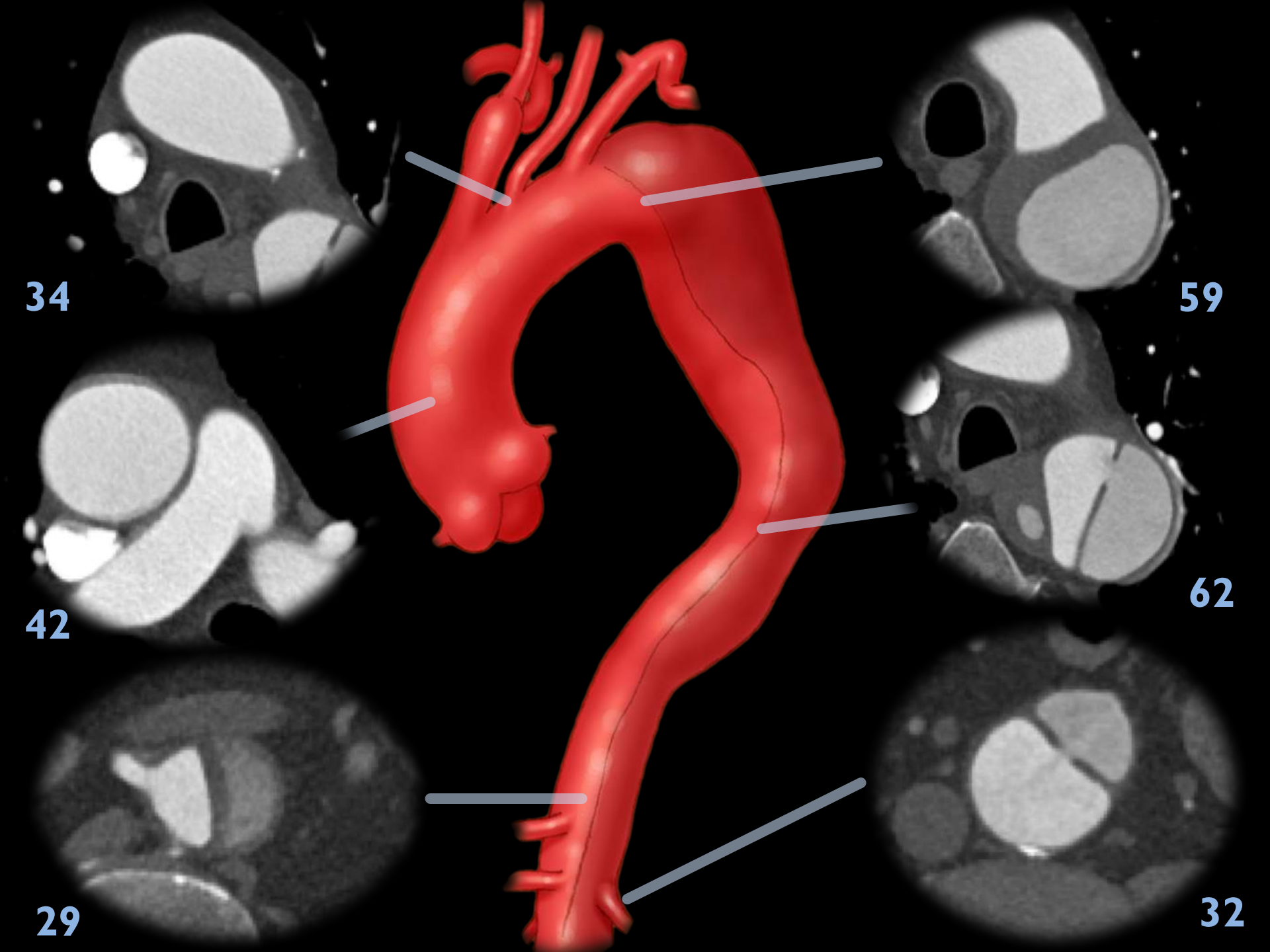
34
59
42
62
29
32

GORE **TBE**

- Off-the-shelf
- Diameter 21 – 53 mm
- One retrograde branch 8 – 20 x 60 mm
- Distal portal edge distance 20 - 25 - 40 mm
- Device length 10 – 20 cm

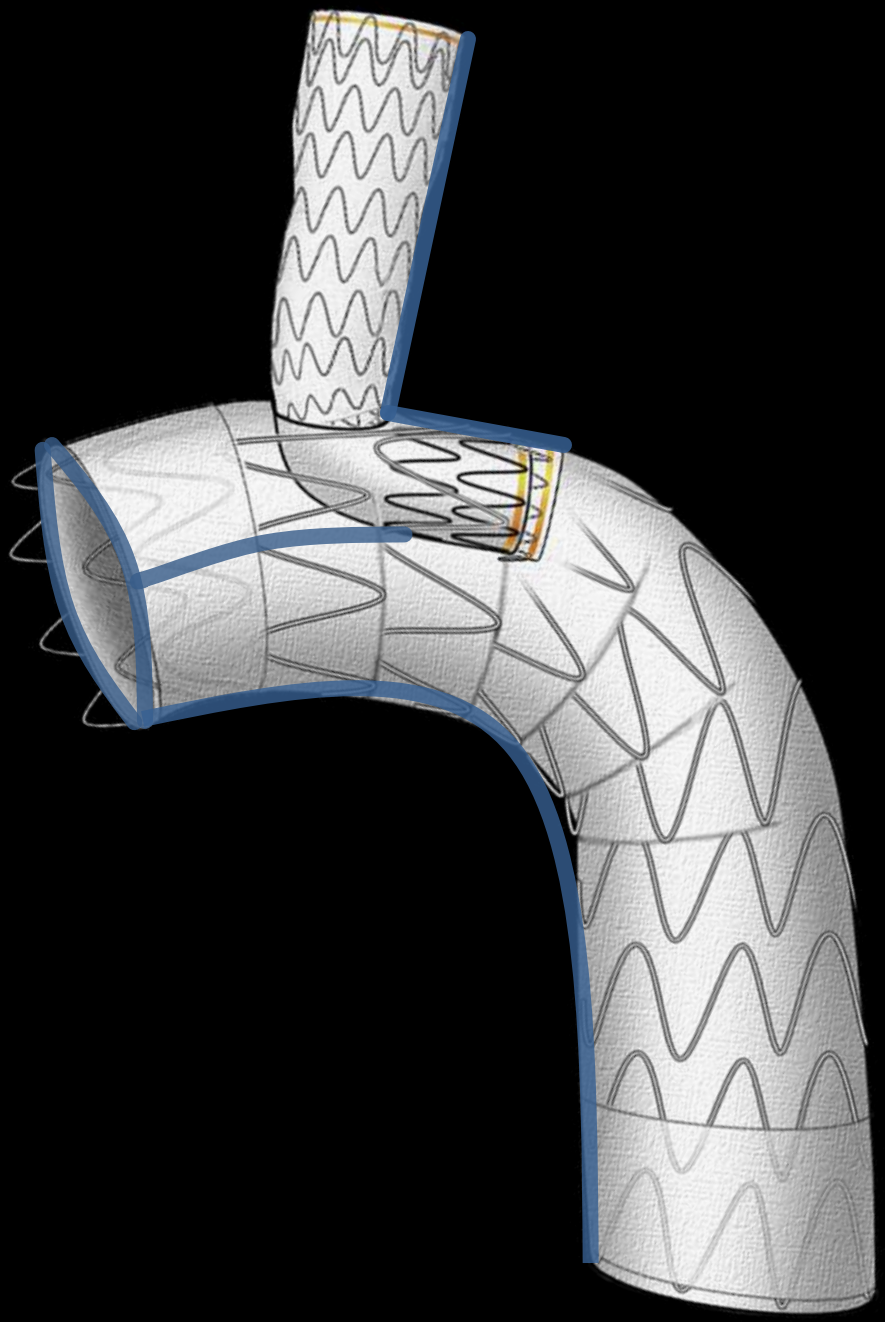

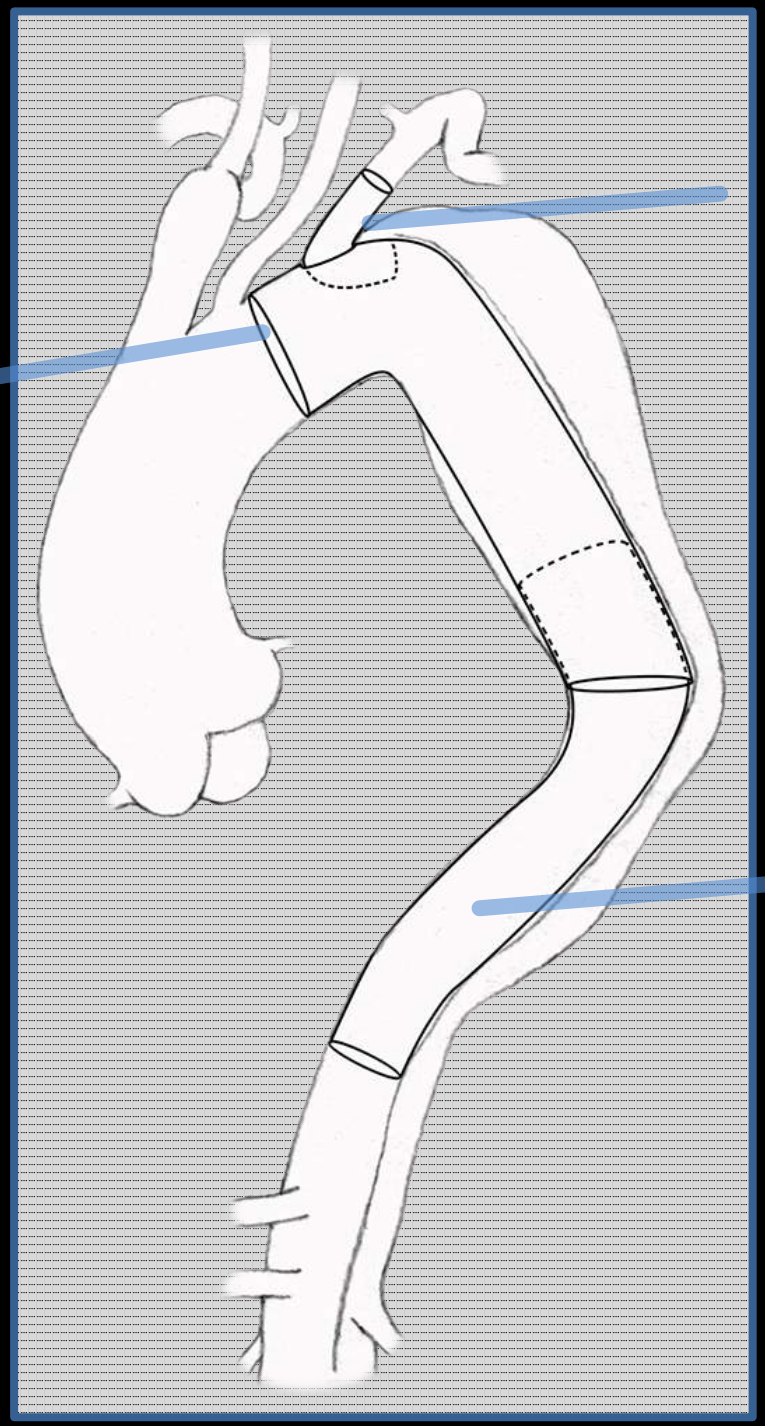

MAYO CLINIC

MAYO
CLINIC

HOSPITAL **COURSE**

- No complications
- Discharged on POD #4
- 30-days follow-up
  - Asymptomatic, recovering as expected

MAYO
CLINIC

MAYO CLINIC

150 Years

SERVING HUMANITY