THE ROLE OF WORK STATIONS ON ASSESSMENT AND PLANNING OF ENDOVASCULAR AND OPEN TAAA REPAIR

Tim Resch Md PhD
Associate Professor of Vascular Surgery
Chief, Vascular Center
Dept of Thoracic and Vscular Surgery
Skane University Hospital
Sweden

Vascular Center
Malmö/Lund
Sweden

LUND UNIVERSITY
Faculty of Medicine

Disclosure

Speaker name: Timothy Resch

.....

I have the following potential conflicts of interest to report

COOK Medical - Consulting, Speakers Bureau, IP, Research support

Medtronic – Advisory Board

Aortica – Advisory Board

Cordis – Research Support

GORE – Research Support, Speakers Bureau

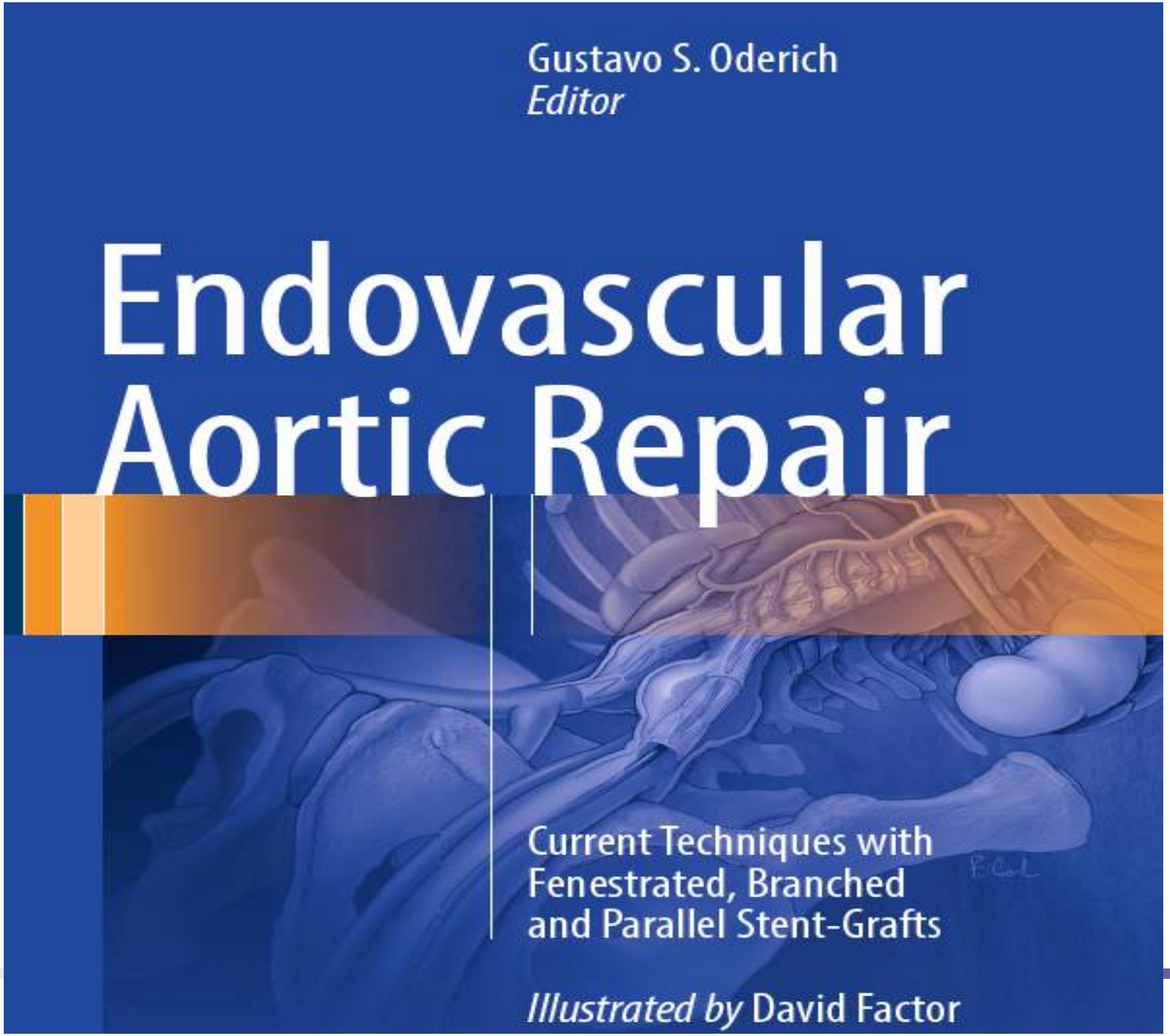
Gustavo S. Oderich
Editor
Endovascular Aortic Repair
Current Techniques with Fenestrated, Branched and Parallel Stent-Grafts
Illustrated by David Factor

Planning

Surgery

Follow Up


ErgonomicHome

It’s All About The Seal!

- Conical
- Thrombuslined
- Short
- Angulated
- Wide

Surrogate Markers for Healthy Aorta

Result of Progessive disease

- Aortic dilatation
  - Procedure failure

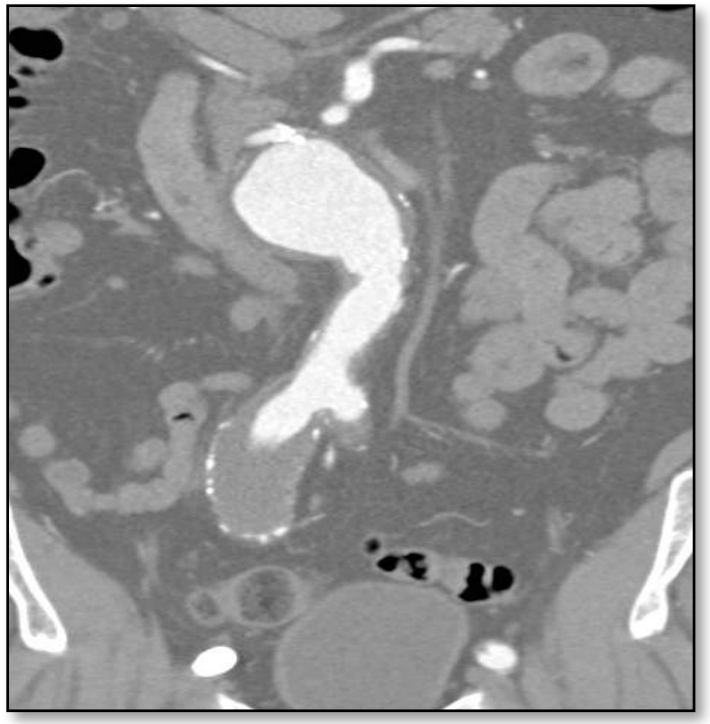

AbuRahma JVS Oct 2009
Sonesson JVS Nov 1998
Resch JVIR Mar 1999

Risk factors for Type 1 EL = Failing Aorta

- Poor sealing zone
  - >10% diameter change in sealing z 15mm
- Sealing Zone site
  - Juxta-renal aorta more vulnerable

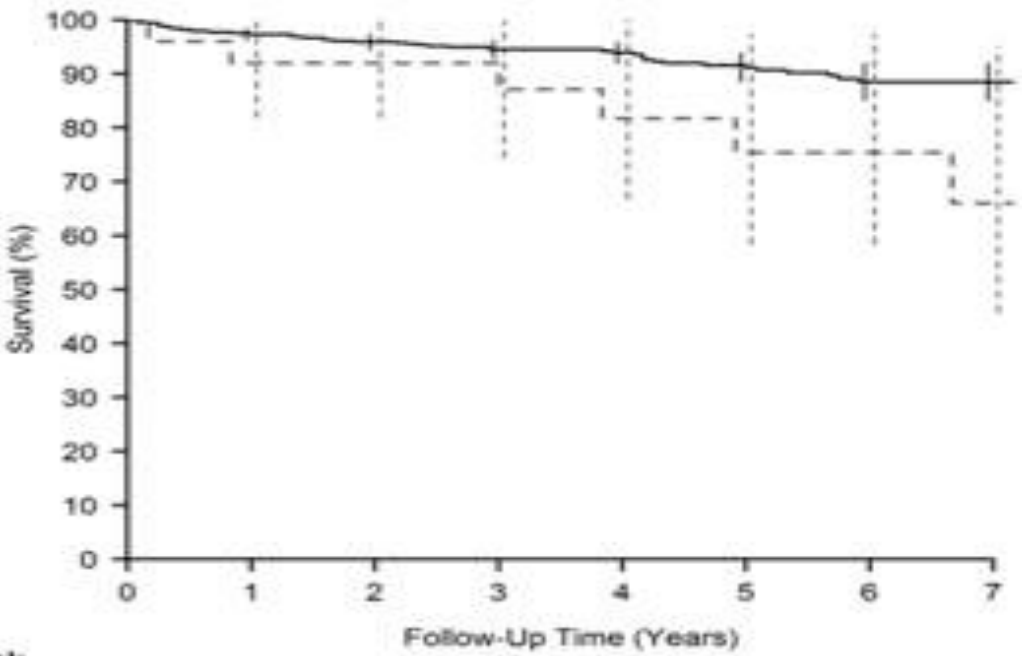

Number at Risk								
No Endoleak	898	704	552	416	299	216	143	88
Endoleak	26	23	21	19	15	12	10	6

O'Callaghan, Mastracci et al, JVS 2015

Associated factors, timing, and technical aspects of late failure following open surgical aneurysm repairs

Raphael Coscas, MD,[a] Roy K. Greenberg, MD,[a,b] Tara M. Mastracci, MD,[a] Matthew Eagleton, MD,[a] Woong C. Kang, MD,[a] Catherine Morales, BS,[a] and Adrian V. Hernandez, MD, PhD,[c] *Cleveland, Ohio*

Objective: In contrast to endovascular repair (EVAR), the absence of rigorous imaging follow-up after open surgical repair (OSR) has rendered the perception that late failure (LF) is rare. Better understanding of associated factors with LF will help define OSR follow-up paradigms and perhaps alter initial repair strategy to facilitate treatment of LF. The aim of this study is to evaluate aspects of LF requiring intervention after OSR.

Methods: From 1998 to 2008, data were collected prospectively on 1097 patients who underwent an aortic endovascular repair. Patients undergoing intervention for LF contiguous with prior OSR were subjected to further analysis. The indication for reintervention was a maximal diameter >60 mm. Univariable and multivariable linear regression models were used to compare patients and disease variables (18 variables regarding age, comorbidities, family history, etiology, and extent) with time to LF.

Incomplete OSR

More extensive aneurysms

Older

more aggressive follow-up given their propensity to present with LF. The threshold and strategies guiding reintervention in the setting of LF is dependent upon many factors relating to the structure and the morphology of the aorta and implanted graft, the type of anastomosis, and patient comorbidities. Therefore, surgeons should consider LF treatment options when planning an aneurysm repair in an effort to optimize any later interventions, and have specifically tailored follow-up paradigms. (J Vasc Surg 2010;52:272-81.)

Late aortic and graft-related events after thoracoabdominal aneurysm repair

W. Darrin Clouse, MD,[a] Luke K. Marone, MD,[a] J. Kenneth Davison, MD,[b] David J. Dorer, PhD,[c] David C. Brewster, MD,[a] Glenn M. LaMuraglia, MD,[a] and Richard P. Cambria, MD,[a] *Boston, Mass*

Purpose: Unlike abdominal aortic aneurysm repair, little information exists regarding aortic-related morbidity (synchronous/metachronous aneurysm or graft-related complications) after thoracoabdominal aneurysm (TAA) repair. This study was performed to define such events and identify factors related to their development.
Methods: Over a 15-year interval, 333 patients underwent TAA repair (type I, n = 90; 27%; type II, n = 59; 18%; type III, n = 118; 35%; and type IV, n = 66; 20%). Late aortic events were defined as aortic disease causing death or necessitating further intervention or graft-related complications (infection, pseudoaneurysm, branch occlusion) after hospital discharge. Variables were assessed for their association with aortic events with Cox proportional hazards regression.
Results: In-hospital mortality occurred in 28 patients (8.4%), which left 305 available for follow-up (mean length of follow-up, 26 months; interquartile range, 2.7 to 38.4 months). After TAA repair, aneurysm remained in 60 patients

Incomplete OSR
More extensive aneurysms
Females

Conclusion: Late aortic events occur in at least 10% of patients after TAA repair and are usually the result of native aortic disease in remote (or noncontiguous) aortic segments. Graft-related complications, in particular, degeneration of inclusion anastamoses, are rare. Female gender, original presentation with rupture, and unresected disease identify those at highest risk. These findings verify the anatomic durability of TAA repair and suggest indefinite aortic surveillance is indicated for those at risk of events. (J Vasc Surg 2003;37:254-61.)

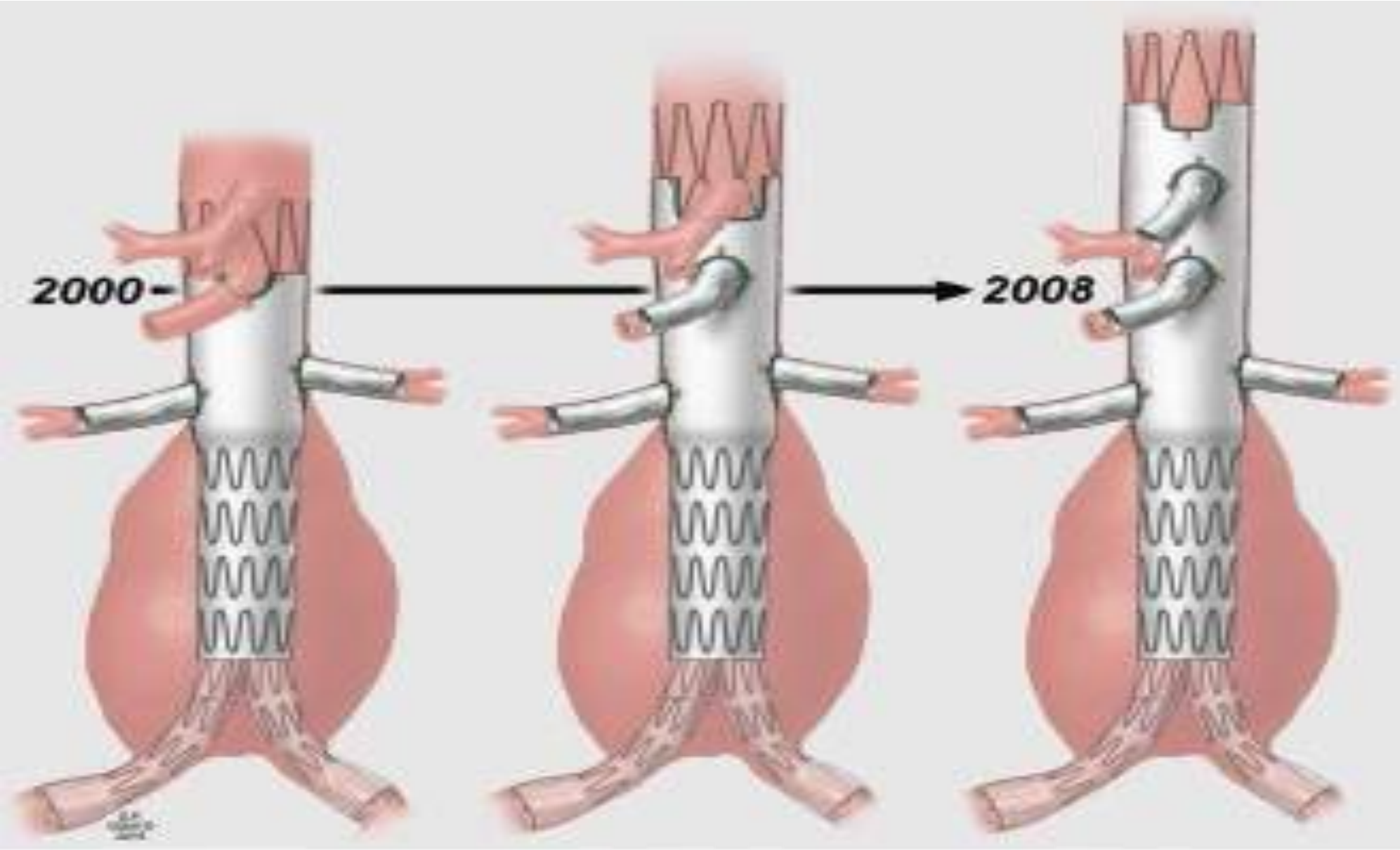
2000
2008

Lille-Malmo Experience
Fenestrated Endografts for Juxtarenal AAAs

288 Patients (2002-2012)
Early experience with first 50 patients (~4.7 yr)

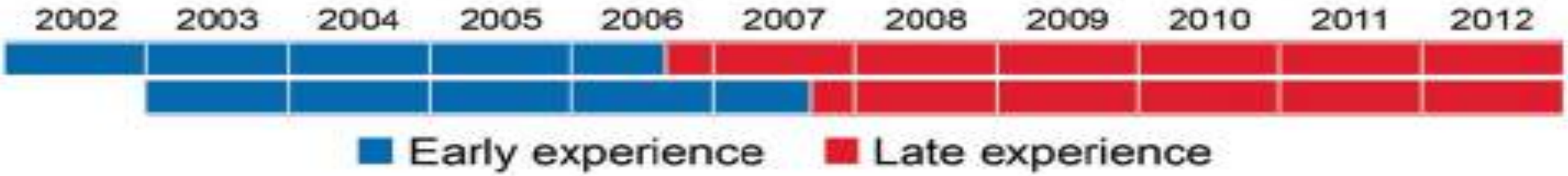

	Early experience n=100	Late experience n=188	
Fenestrations	2.7±0.8	3.2±0.8	0.001
2 fen	35	11	
4 fen	7	30	

	Early experience (%) n=100	Late experience (%) n=188	
Fenestrations	2.7±0.8	3.2±0.8	0.001
Fluoroscopy	84 min	65 min	0.05
Contrast volume	254 ml	184 ml	0.05
30-day Mortality (%)	2	2	NS

ANATOMIC CONSIDERATIONS FOR COMPLEX AORTIC REPAIR

Anatomical Planning Considerations

Visceral anatomy

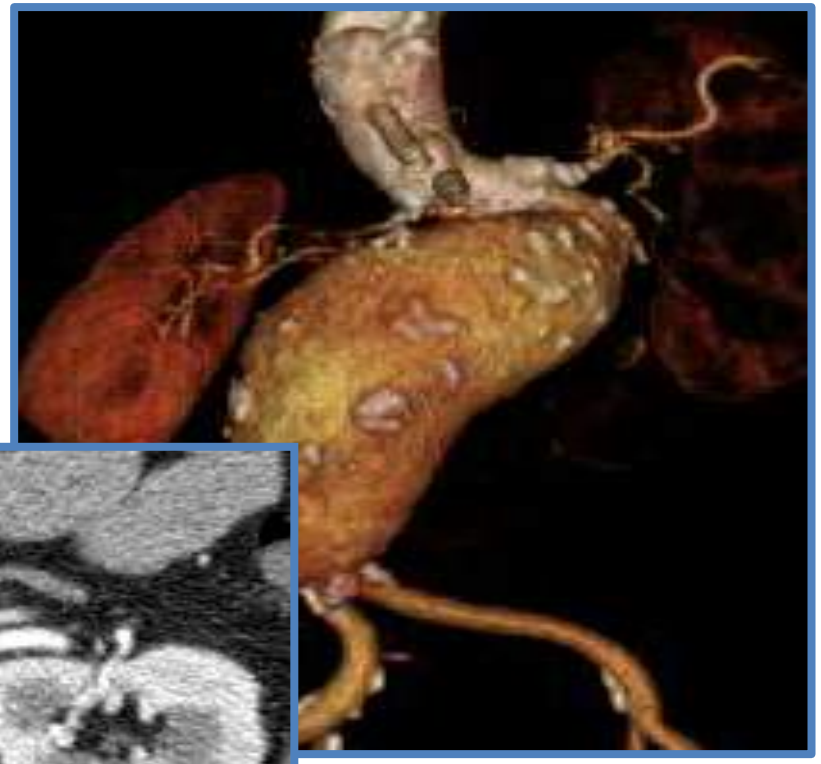

Angulation

'Shaggy aorta'

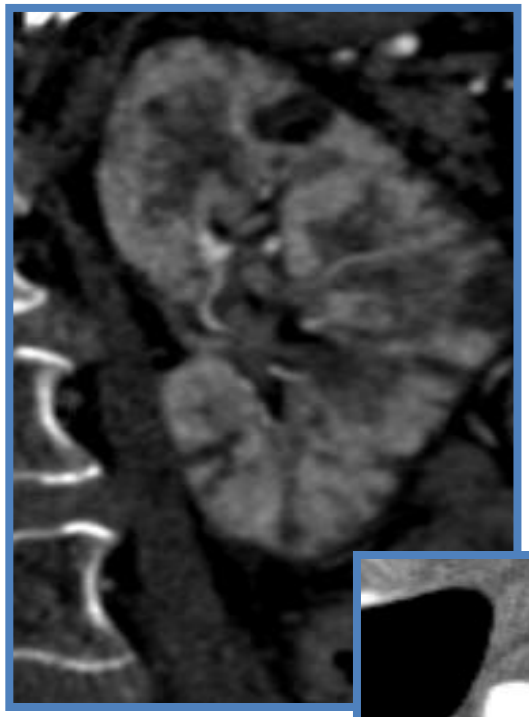

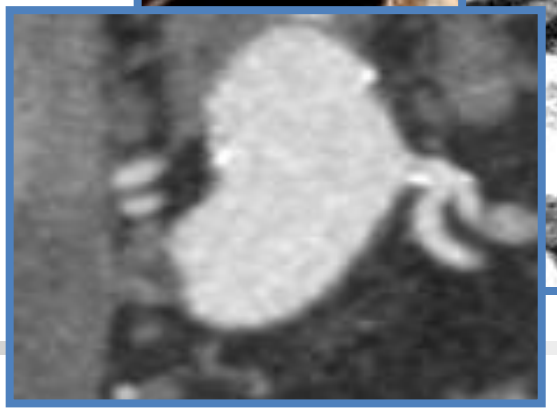

Renal issues

CrossMark

From the Society for Vascular Surgery

Implications of renal artery anatomy for endovascular repair using fenestrated, branched, or parallel stent graft techniques

Bernardo C. Mendes, MD,[a] Gustavo S. Oderich, MD,[a] Leonardo Reis de Souza, MD,[a] Peter Banga, MD,[a] Thanila A. Macedo, MD,[b] Randall R. DeMartino, MD,[a] Sanjay Misra, MD,[b] and Peter Gloviczki, MD,[a]
Rochester, Minn

JVS 2016)

- N=520
  - 1009 Main renal arteries
  - 177 accessory renals
- **18% non suitable for endo due to renal issues**

Target Vessel Revascularization

Branches

- TV in wide aorta >30
- Caudally oriented TV/TV Stents
- Proximal Extension of Disease
- Previous Device Short Body?

Fenestrations

- Previous infrarenal repair
  - Type 1 EL
- Cranially oriented TV/TV Stents
  - Previous Renal Stents
  - Juxta/Suprarenal AA
- Healthy Supravisceral Aorta

Tailor Graft to Patient in Planning

Branches vs. Fenestrations

Directional Branch

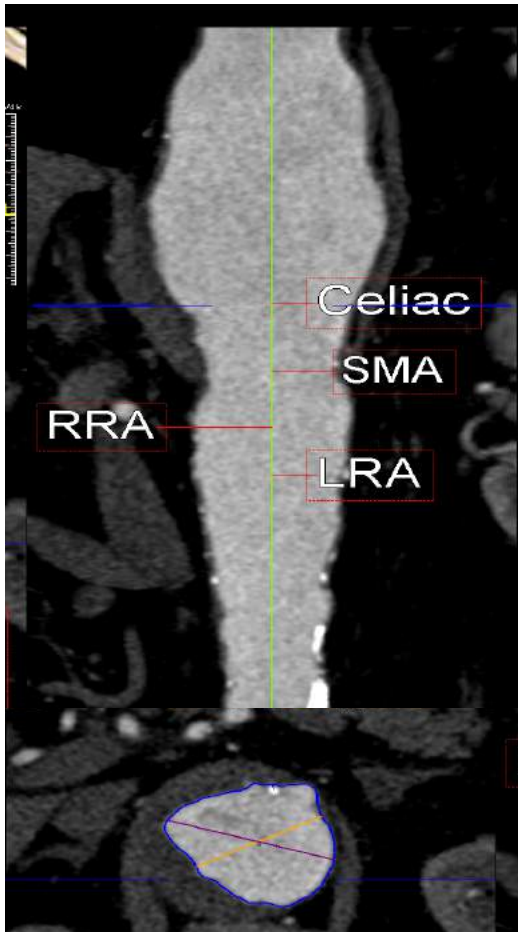

Branch Fenestration

??

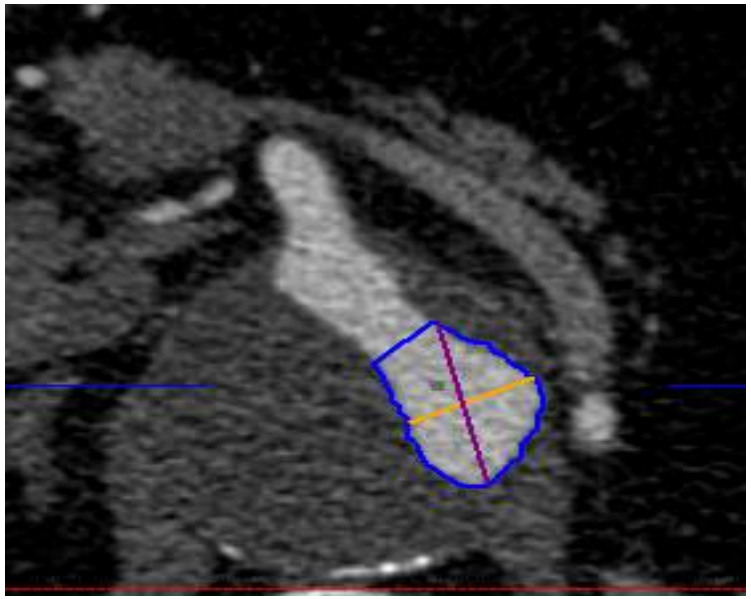

Space Considerations

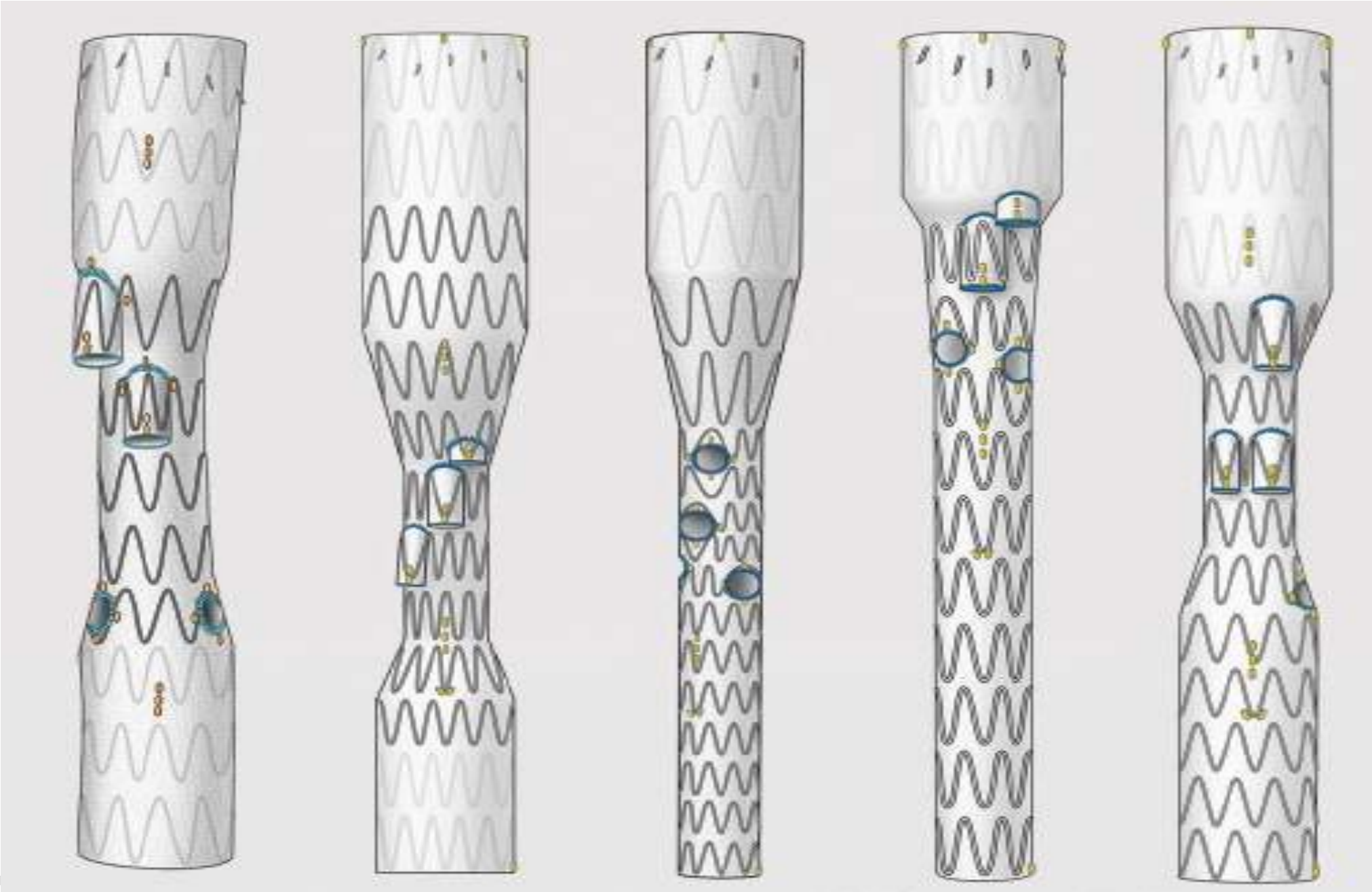

Target Vessel Anatomy

Crainocaudal

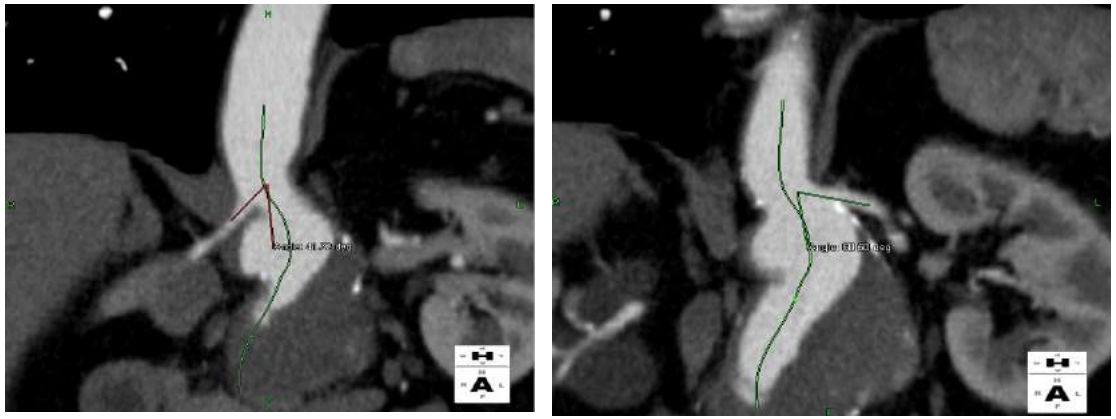

Type IV TAA

Type II/III TAA

Ant-Post

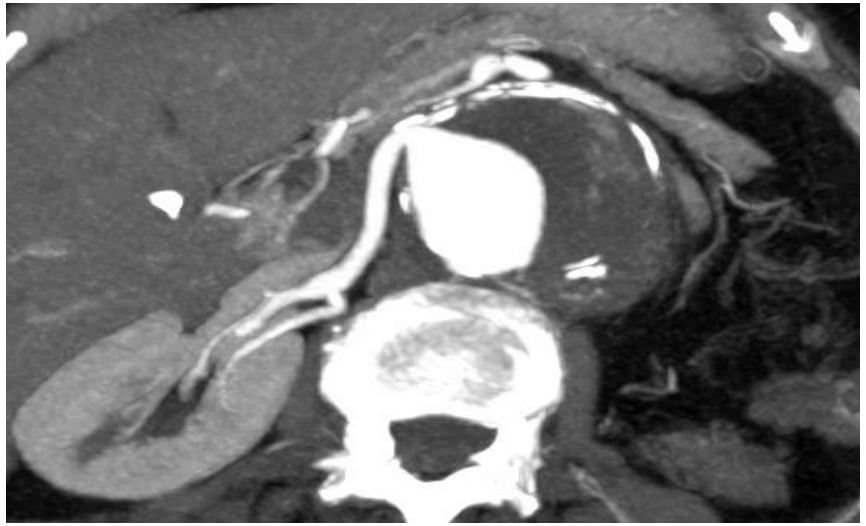

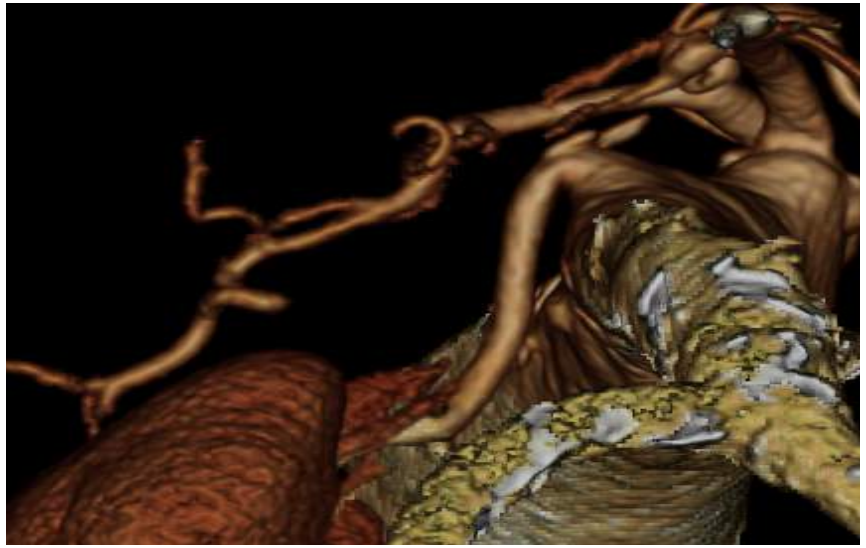

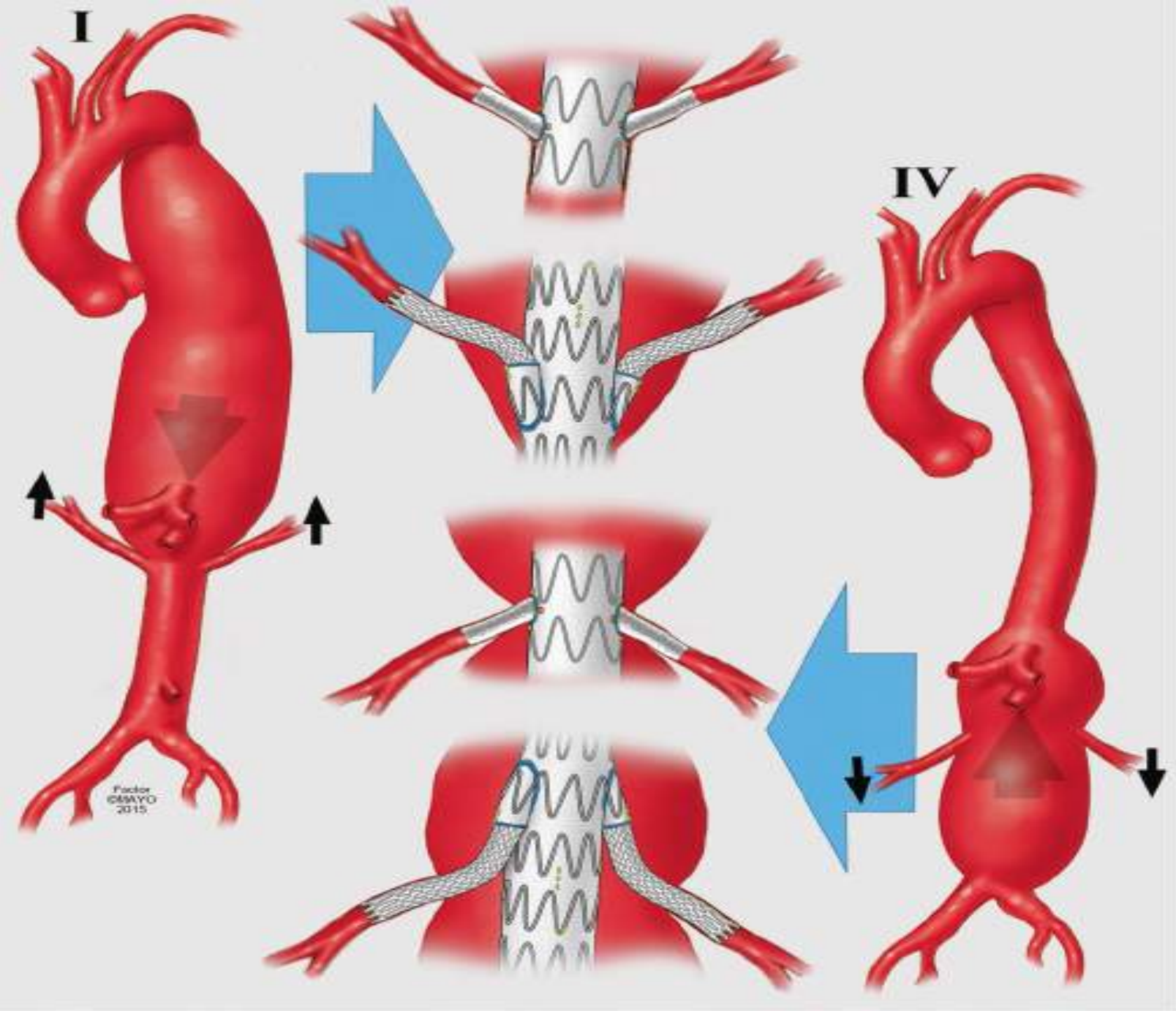
I
IV
Pacior
MAYO
2015


Sin

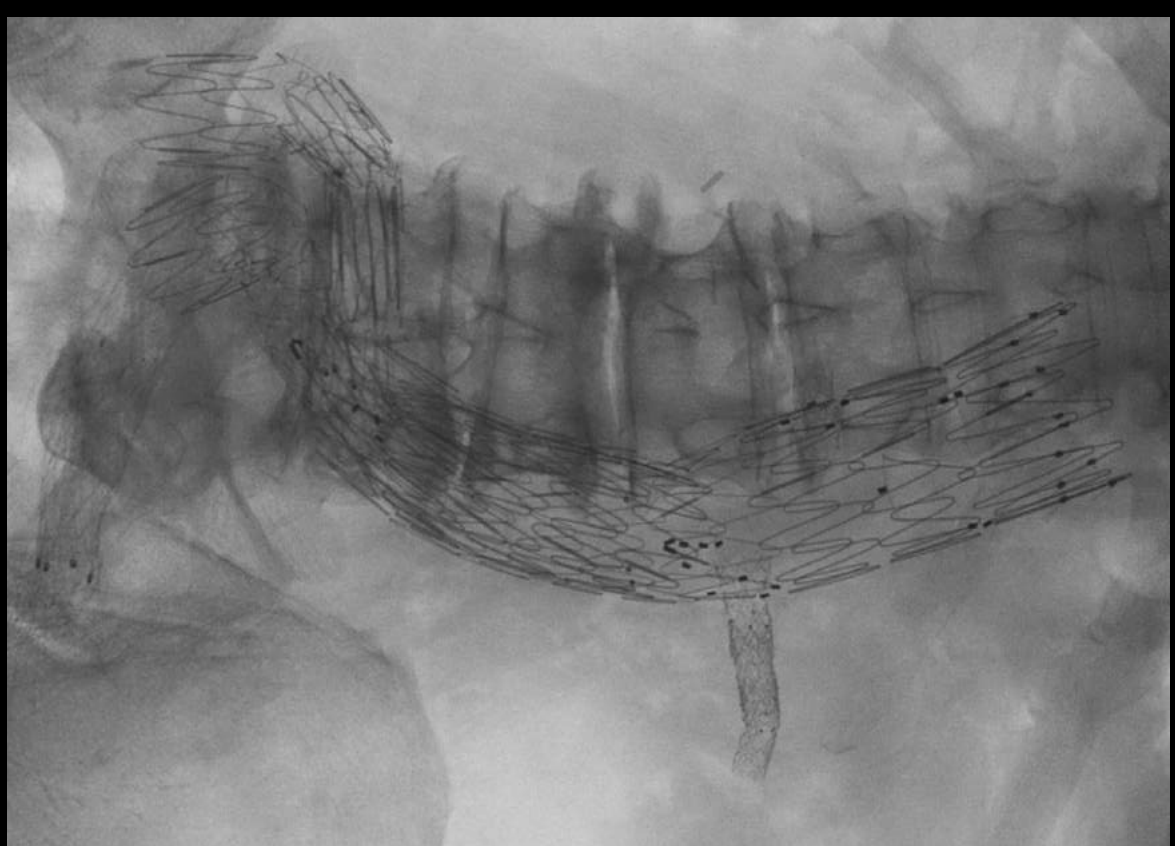

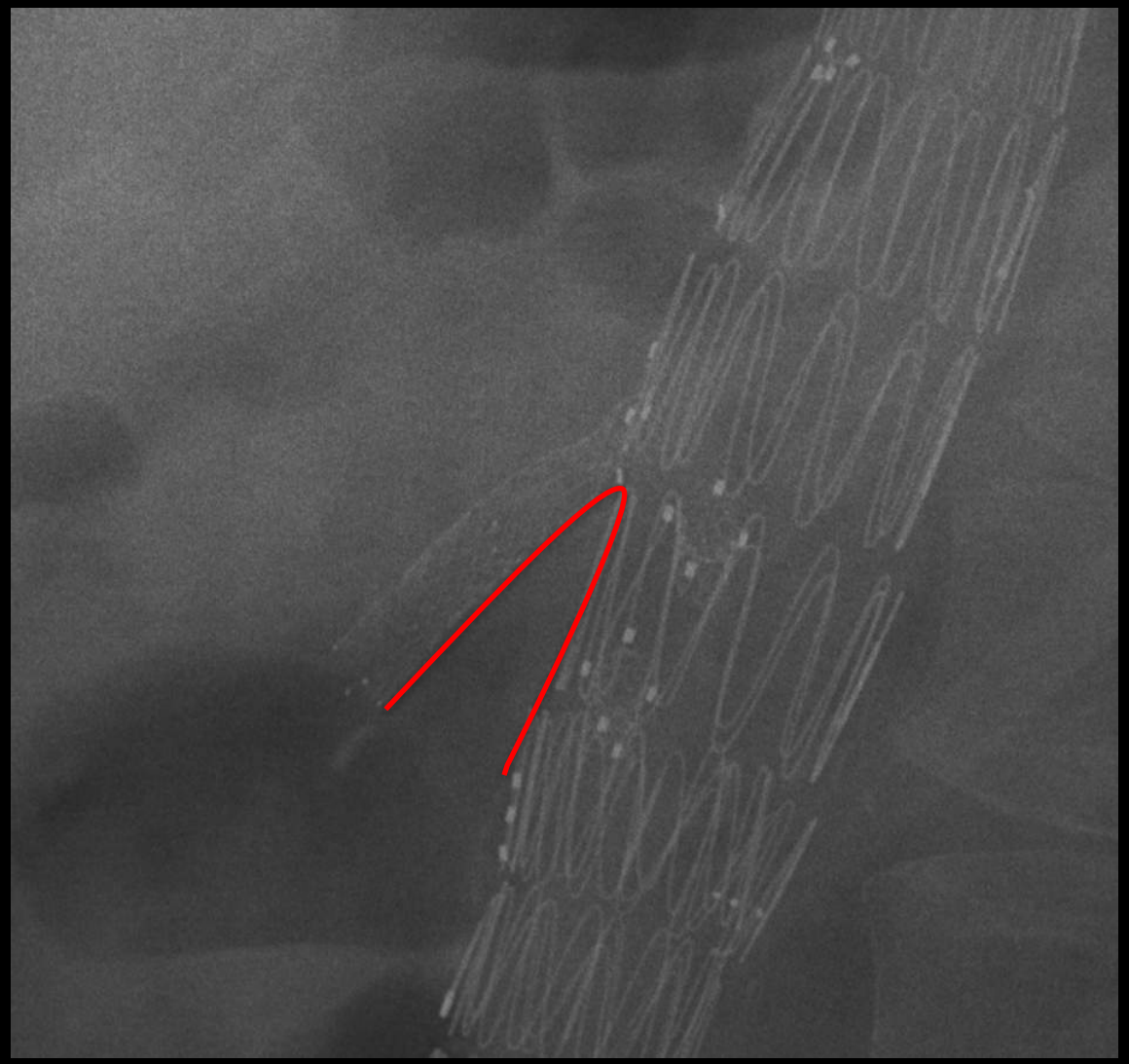

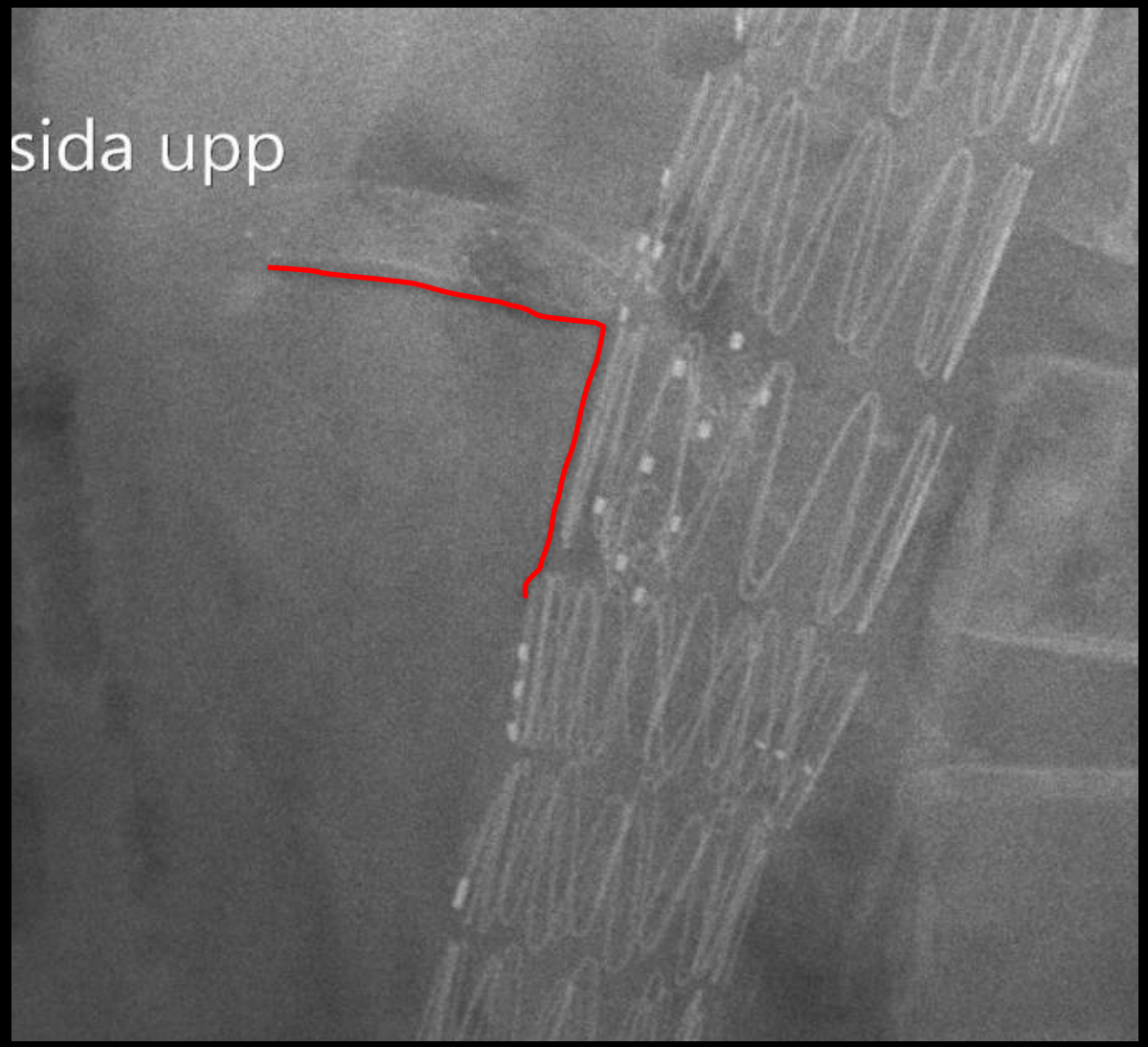
sida upp

DESIGN IMPLICATIONS FOR AORTIC COVERAGE

Branches in juxtarenal repair?

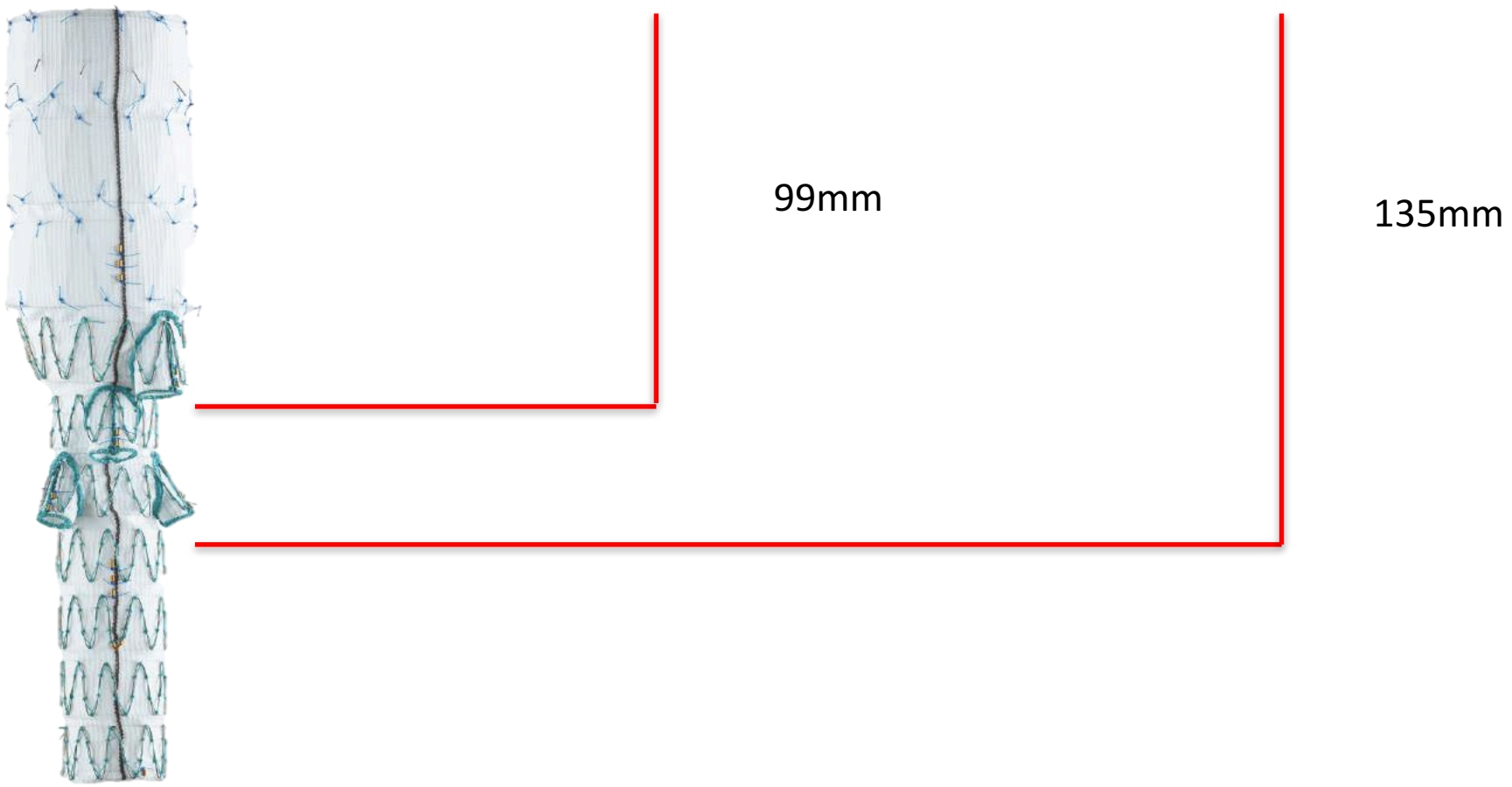

Lower extremity weakness after endovascular aneurysm repair with multibranched thoracoabdominal stent grafts

Julia D. Sobel, BS, Shant M. Vartanian, MD, Warren J. Gasper, MD, Jade S. Hiramoto, MD, Timothy A. M. Chuter, DM, and Linda M. Reilly, MD, *San Francisco, Calif*

- Lower extremity weakness 21%
  - 13% full recovery
  - 8% persistent deficit
- No Bias based on Crawford extent of aneurysm
  - Included Type II-IV aneusyms and juxta/suprarenal

Table III. Branch outcomes[a]

Branch	*No.*	*Insertion injury No. (%)*	*Patent No. (%)*	*Occluded No. (%)*	*Stenosed No. (%)*	*Stented No. (%)*	*Stenosed or occluded[b] No. (%)*	*Injured, stenosed, or occluded[b] No. (%)*
Celiac axis	76	2 (2.6)	74 (97.4)	2 (2.6)	0 (0.0)	0 (0.0)	2 (2.6)	3 (3.9)
Superior mesenteric artery	81	1 (1.2)	81 (100)	0 (0.0)	1 (1.2)	1 (1.2)	1 (1.2)	2 (2.5)
Renal artery	148	11 (7.4)	139 (93.9)	9 (6.1)[c]	4 (2.7)	3 (2.0)	13 (8.8)	21 (14.2)
χ^2		5.48	5.85	5.85	2.39	1.6	7.39	15.9
R		0.065	0.054	0.054	0.3	0.45	0.025	0

- Chuter et al JVS 2012;56
- 81pat, 306 Branches
- Mean FU 21months
- 100% Technical Branch Success

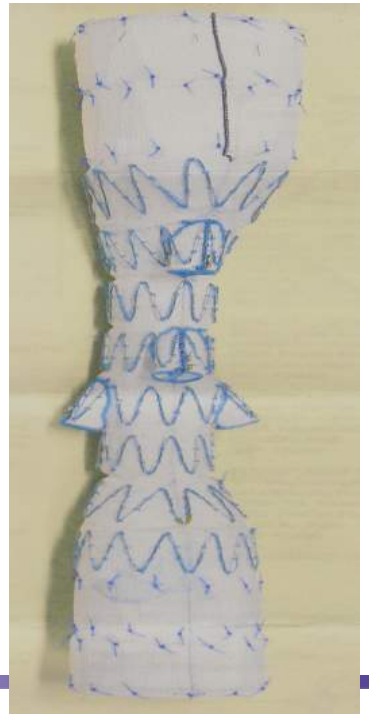

9% renal branch occlusion

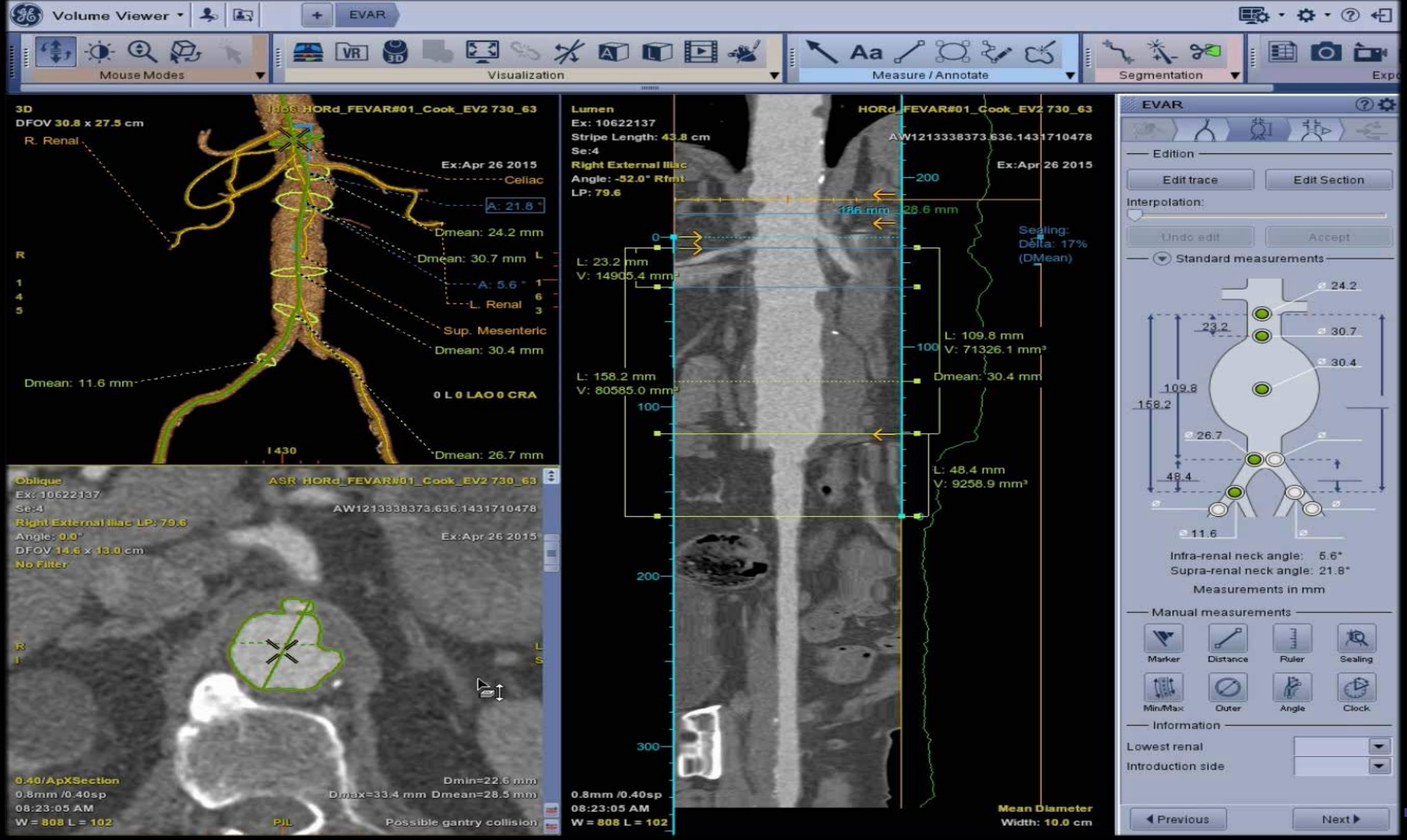

Video courtesy of S Haulon

Courtesy of Tom Carrel


H

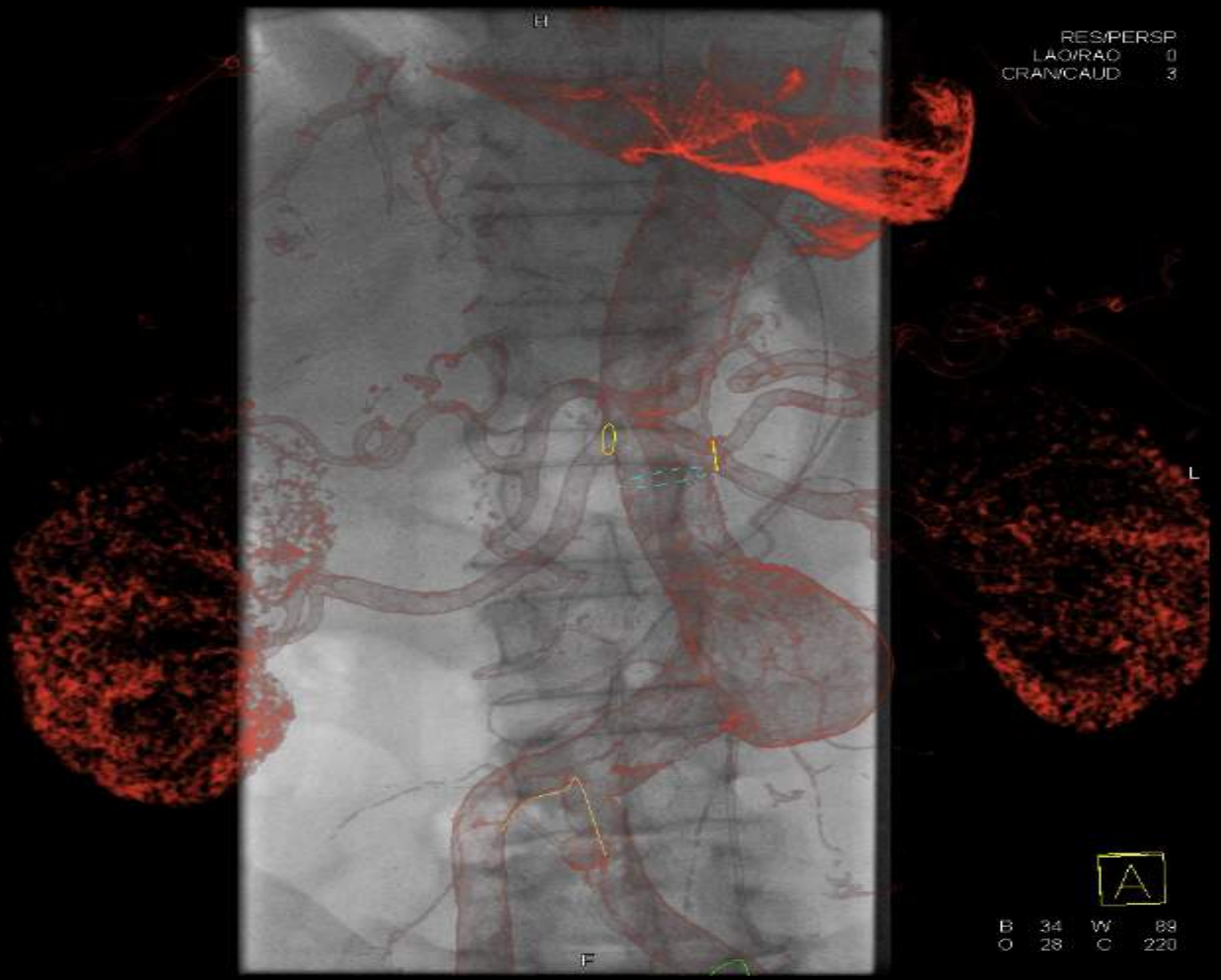
H
RES/PERSP
LAO/RAO 0
CRAN/CAUD 3
L
F
A
B 34 W 89
O 28 C 220

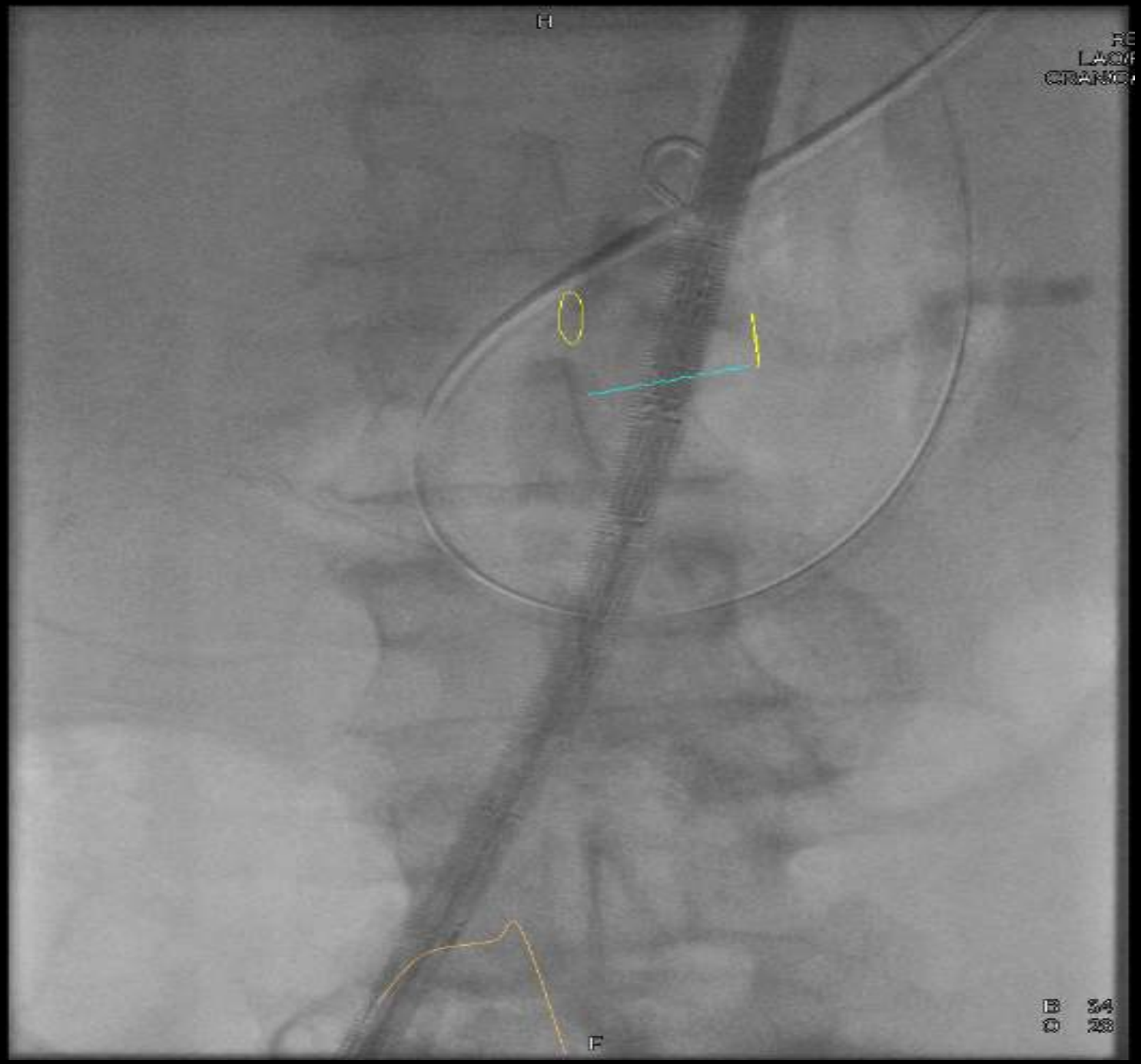
H
F


72.4 mm

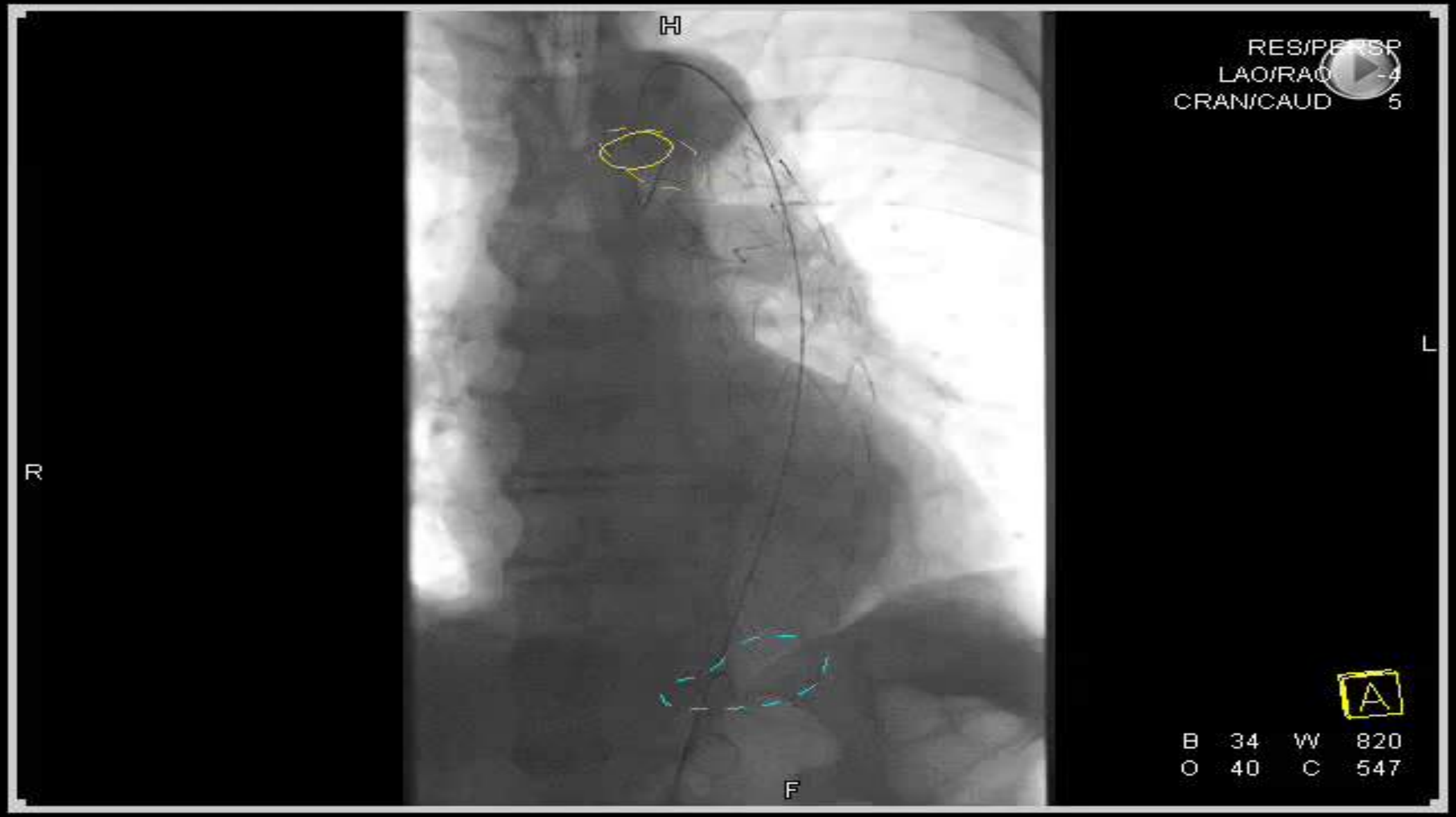
H
RES/PERSP
LAO/RAO -4
CRAN/CAUD 5
L
R
A
B 34 W 820
O 40 C 547
F

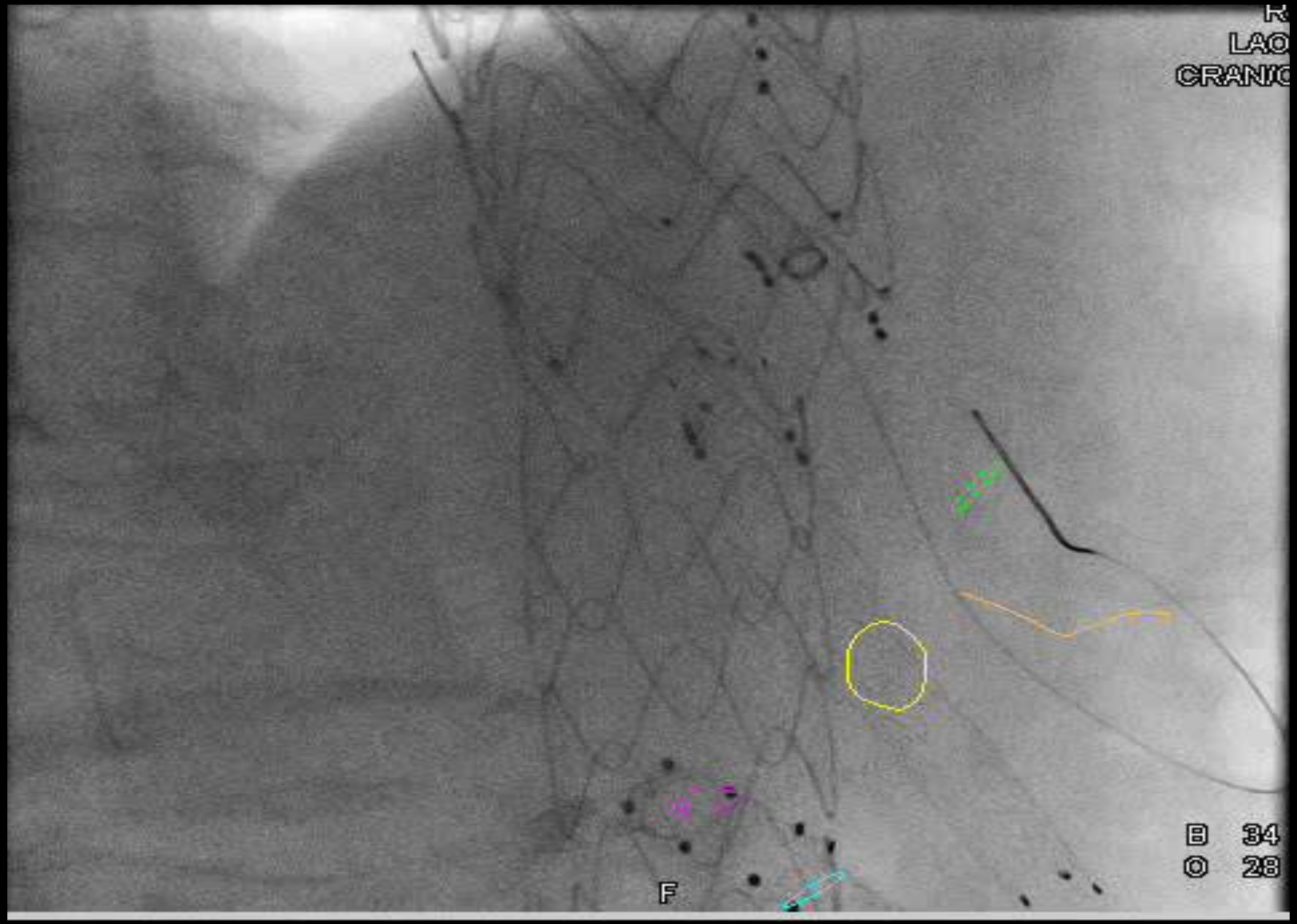
LAO
CRANIO
B 34
O 28
F

Final Imaging

2015-02-04 15:47:57

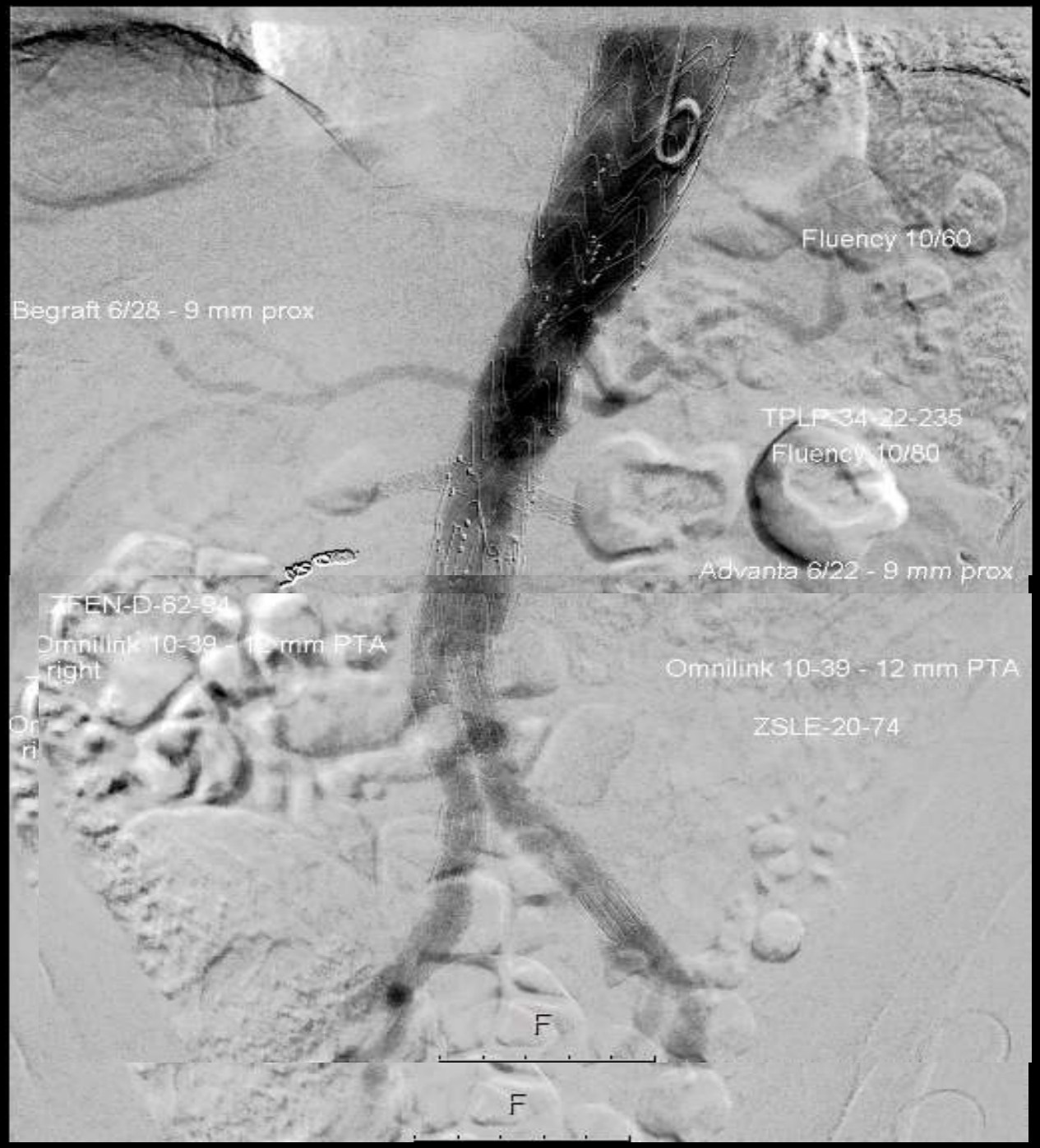

Most complications are seen and treated within 30days post EVAR

Greenhalgh RM, Comparison of endovascular aneurysm repair with open repair in patients with abdominal aortic aneurysm (EVAR trial 1), 30-day operative mortality results: randomised controlled trial. Lancet. 2004;364(9437):843-8

Early complications that demand reintervention are not seen on final DSA

Biasi L, Intra-operative DynaCT improves technical success of endovascular repair of abdominal aortic aneurysms. Journal of vascular surgery. 2009;49(2):288-95

Subanalysis show that patients who undergo CBCT require less reinterventions

Brown LC, Use of baseline factors to predict complications and reinterventions after endovascular repair of abdominal aortic aneurysm. Br J Surg 2010;97(8):1207e17

Completion Imaging

	Endoleaks	Limb issues	Branch/Fens
Angiography	++	+	+ (flow)
Discharge CT	+++	+++	+++

Cone Beam Computed Tomography

- ”angioCT”
- With or without contrast
- Protocol
  - 9/5 sec aquisition, 30F/s (220 degrees)
  - Contrast 140mgI/ml
    - 8ml/sec (8sec)
    - Total 72/40ml
- Immediate reformatting in Workstation


A
MPR 1.0mm
LAO/RAO 0
CRAN/CAUD -90
1.42cm
R
L
F
P

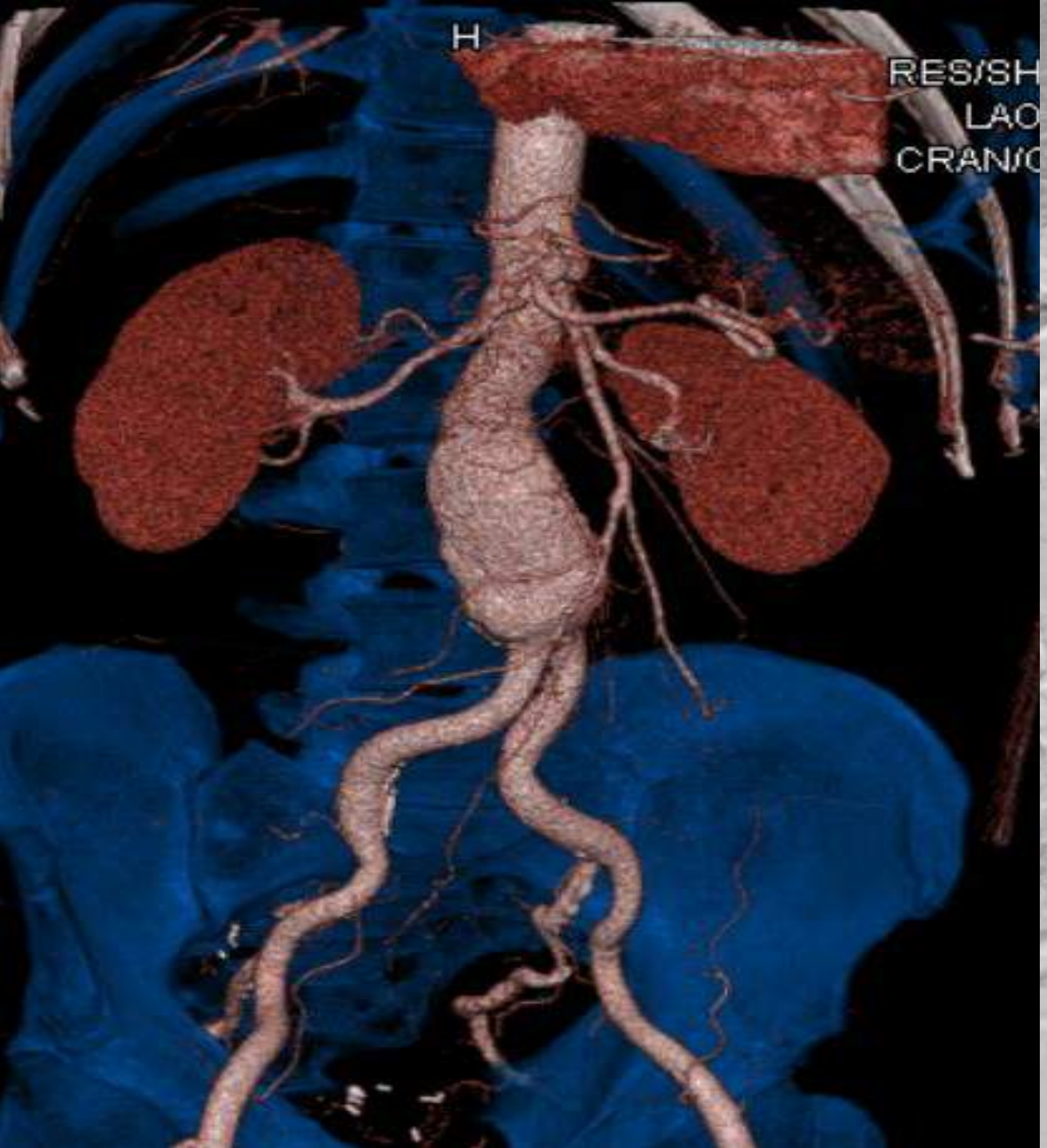
H
RES/SH
LAO
CRAN/C


ZALB 28-108
ZALL 16-72
ZALL 16-84
F


F

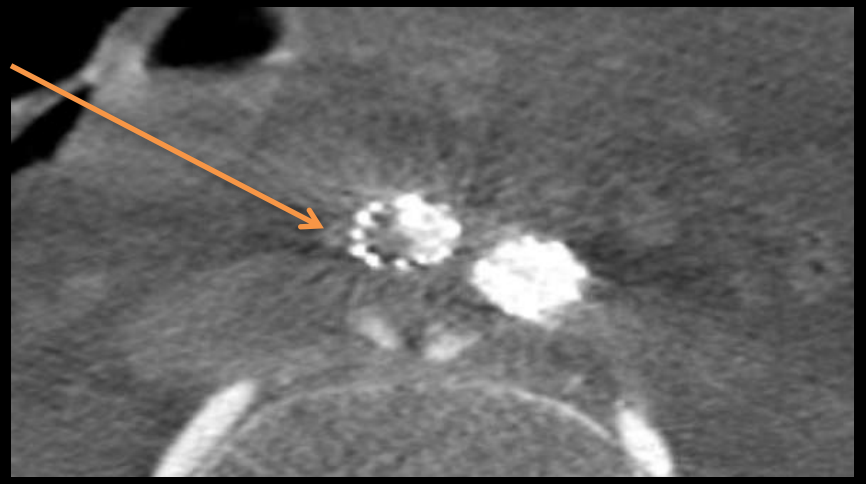

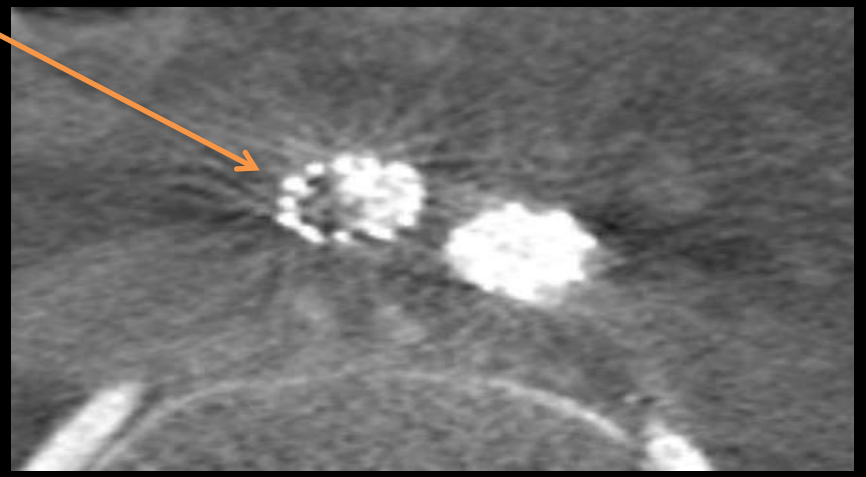

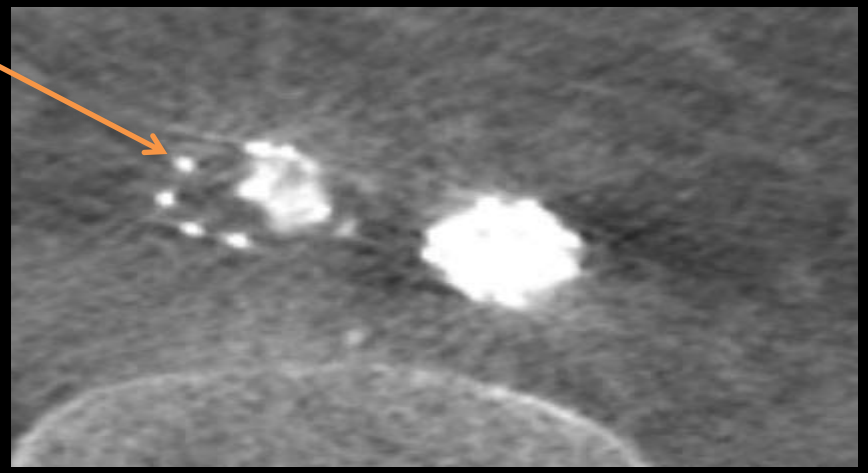

Utility of Intra-operative Cone Beam Computed Tomography in Endovascular Treatment of Aorto-iliac Occlusive Disease

P. Törnqvist *, N. Dias, B. Sonesson, T. Kristmundsson, T. Resch

Vascular Center, Department of Hematology and Vascular Diseases, Skåne University Hospital Malmö, Sweden

WHAT THIS PAPER ADDS

This study expands the utility of CBCT to the treatment of aorto-iliac occlusive disease. It shows the value of cross sectional imaging intra-operatively, even when conducting gold standard completion angiography together with intra-arterial pressure measurements. This has, to the authors' knowledge, not been investigated before and can be a supplement to other techniques used to improve technical success and patency.

Objective: Endovascular treatment of aorto-iliac occlusive disease (AIOD) is well established, but to maintain long-term patency, secondary interventions are common. Multiple stents and iliac artery tortuosity often make it difficult to evaluate stent compression intra-operatively and this might be a cause for later failure. Completion angiography (CA) and pressure gradient (PG) measurement are often used to assess the final intra-operative result. The purpose of this study was to evaluate the role of intra-operative cone beam computed tomography (CBCT) to optimize the primary operation results.

Method: Fifty-three patients (28 females) were enrolled in a prospective study. All patients underwent endovascular aorto-iliac revascularization. Final intra-operative results were evaluated with additional CBCT, after CA and PG were found to be satisfactory. Imaging findings and imaging based adjunctive procedures were recorded.

Results: One hundred and sixty five stents were placed because of AIOD. Twenty patients underwent adjunctive procedures after the primary stenting. In 24.5% (13/53) cases, adjunctive procedures were indicated solely by the CBCT findings, as both standard CA and PG were normal. Twenty-six of the 53 patients had kissing stents placed at the aortic bifurcation. Of the kissing stent patients, 34.6% required adjunctive procedures and in two thirds these stent compressions were detected only by CBCT.

Conclusion: The use of CBCT revealed a significant number of stent compressions that were not found with CA and PG. When performing endovascular procedures at the aortic bifurcation, CBCT is an excellent intra-operative evaluation method to assess the configuration of deployed stents. In this study, CBCT improved the technical results intra-operatively, which might influence the long-term patency positively.

Article history: Received 26 May 2015, Accepted 22 September 2015, Available online 2 November 2015

Keywords: Aorto-iliac occlusive disease, Cone beam computed tomography, Kissing stent

Törnqvist et al, EJVES 2016

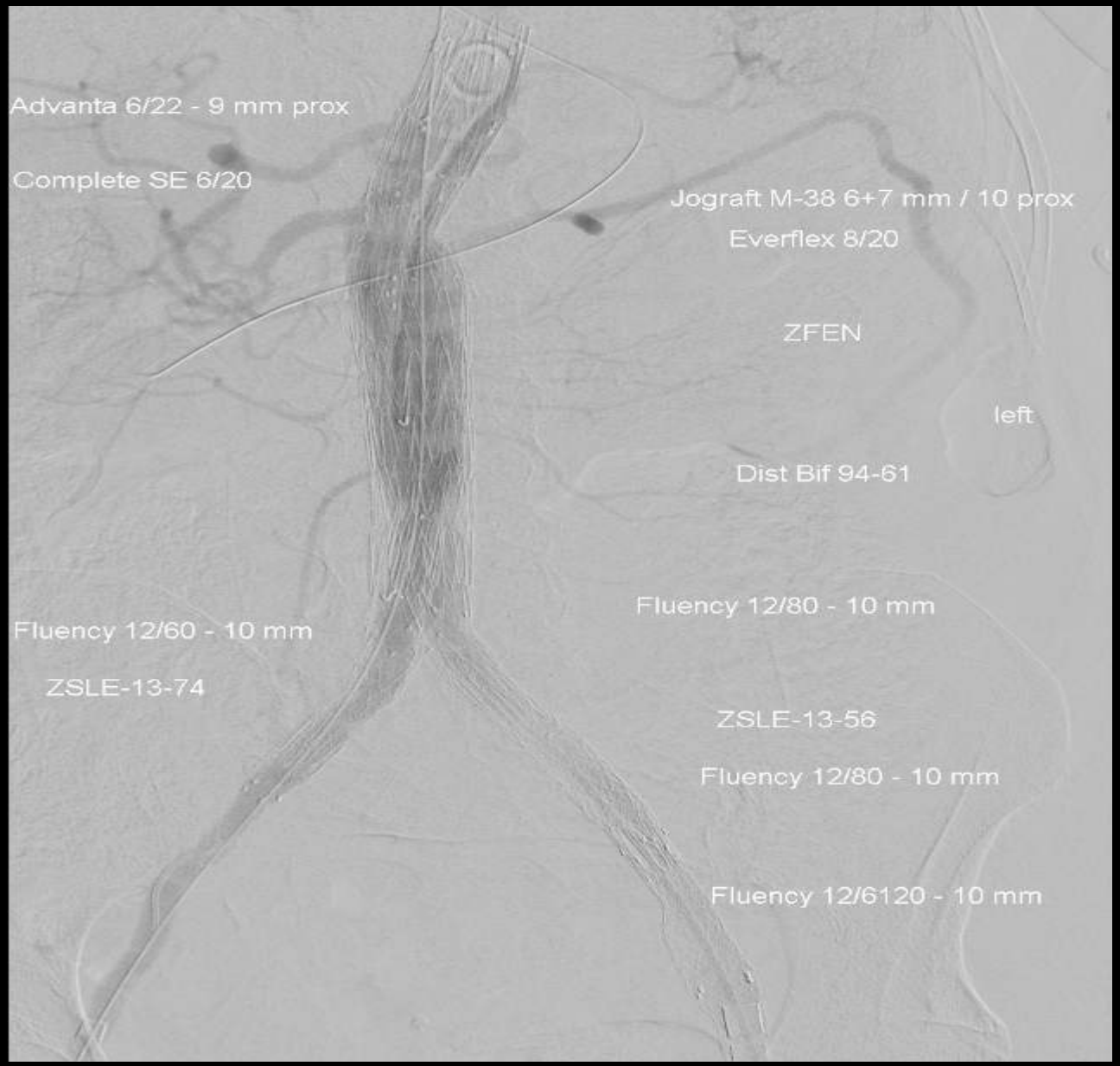

- Tripple fenestrated
- Preloaded system
- Pave and Crack

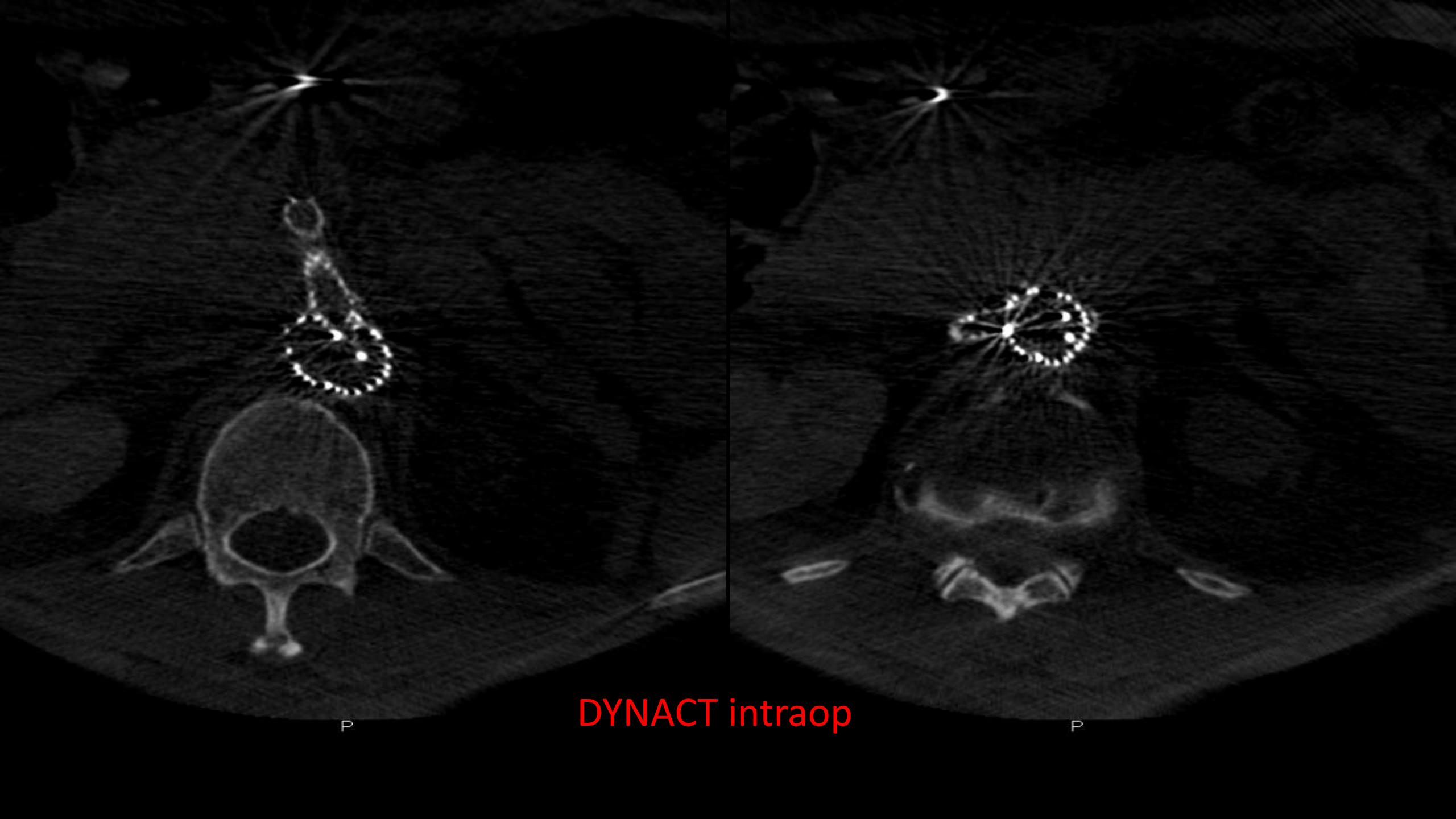

DYNACT intraop

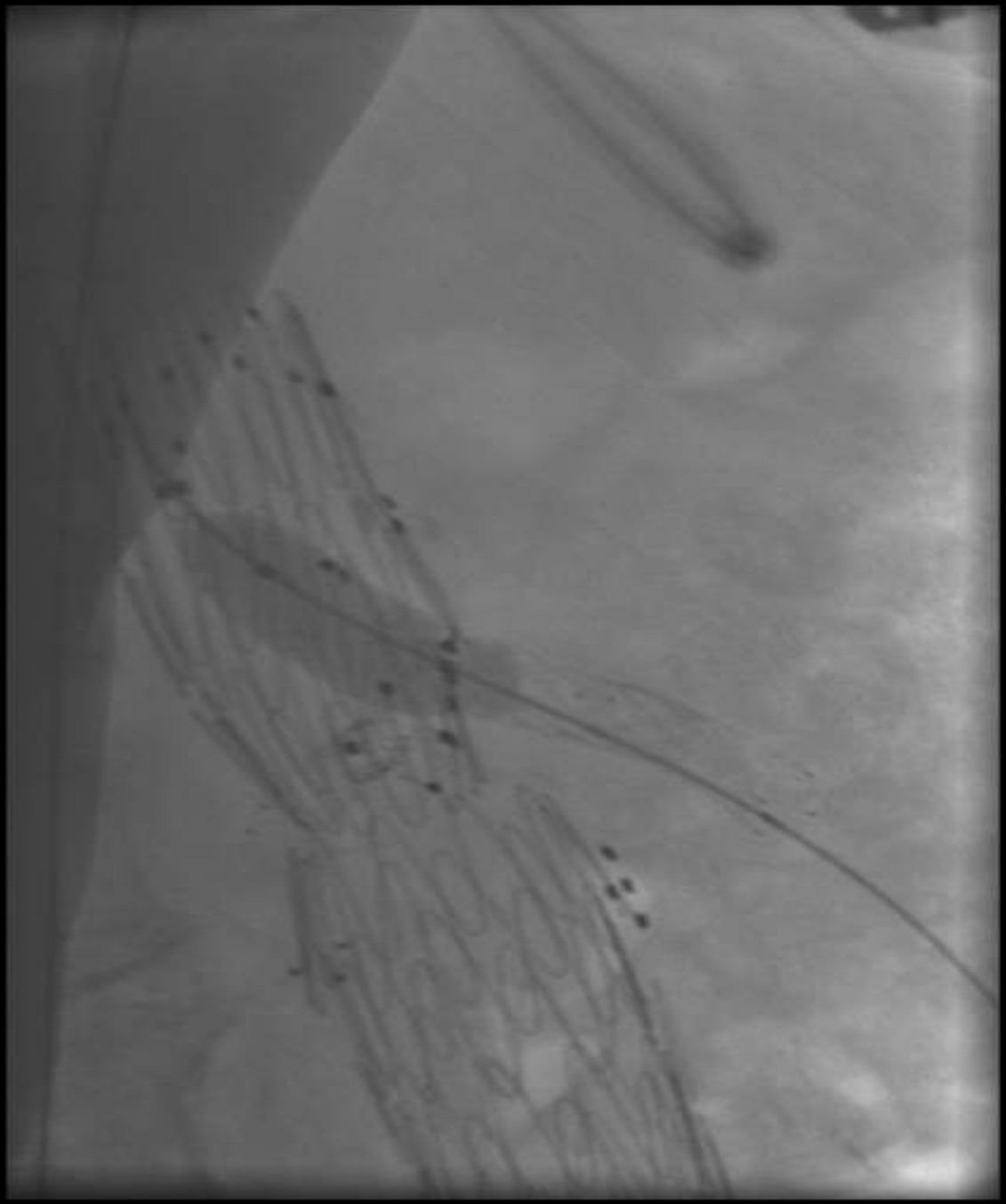

DYNACT after PTA

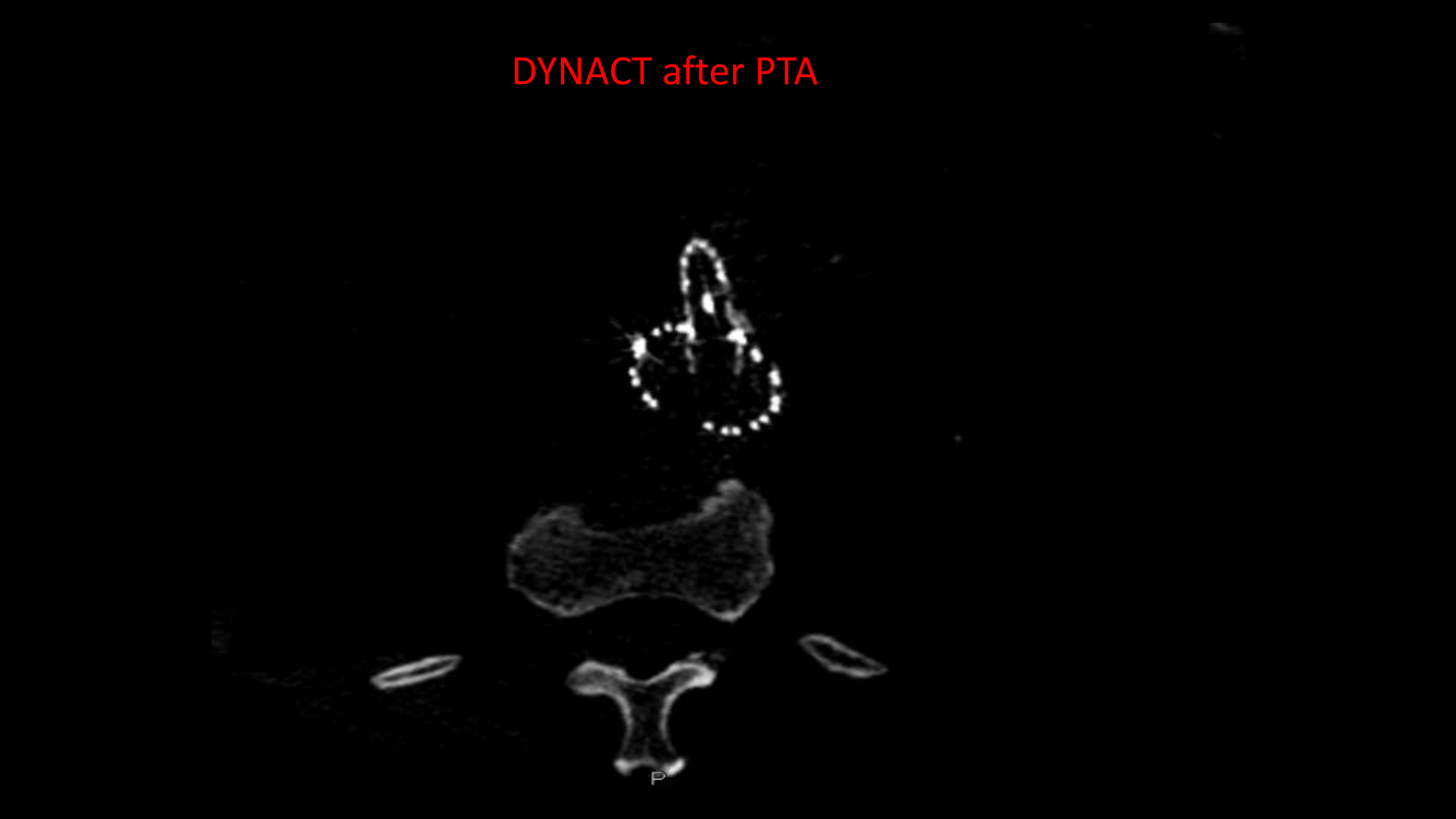

2017!!

Extra-low dose Cone Beam CT (Dyna CT)

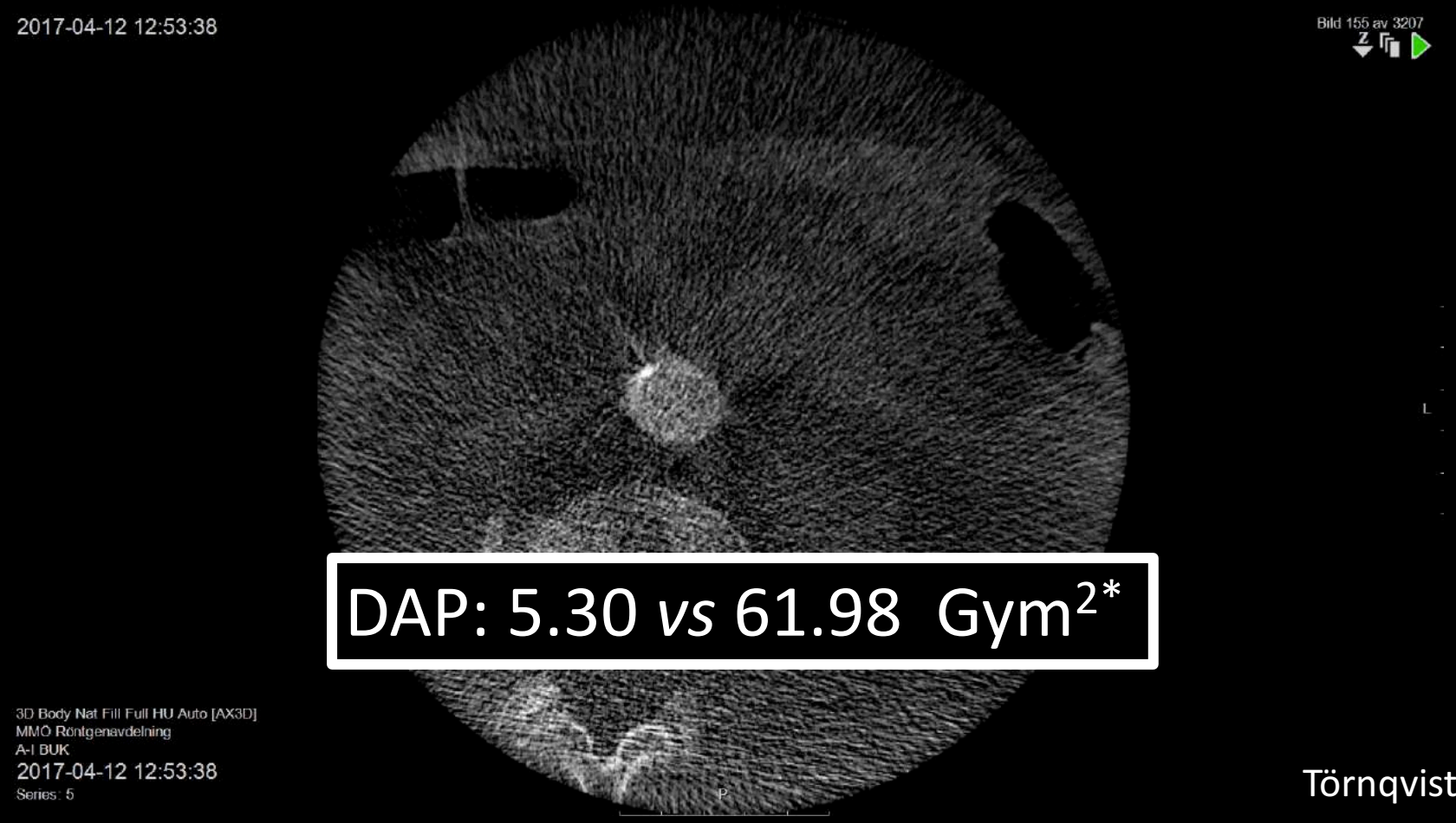

DAP: 5.30 *vs* 61.98 Gym^{2*}

Törnqvist el al, EJVES 2016

3D Imaging is Vital for Optimizing

- Planning Repair from Healthy Aorta
  - Tailor Individual Repair
  - Repair with possible Failure modes in mind
- Surgery
  - Complex repairs can be achieved with maintained outcomes
  - Minimizing operative side effects
  - More complex repair introduce new Modes of Failure
- Follow up
  - Perfecting operative Outcome
  - Complex repair introduce new Modes of Failure
  - Maximizing efficiency

Save the date!

22nd Critical Issues in Aortic Endografting June 29–30, 2018 in Malmö, Sweden