



# Tips and tricks for successful EVAR

**Prof. Fabio Verzini , MD, PhD, FEBVS**

Section of Vascular Surgery  
University of Perugia,  
S.Maria della Misericordia Hospital,  
Perugia, Italy



## Disclosure

Speaker name: Fabio Verzini

.....

X ☒ I have the following potential conflicts of interest to report:

X ☒ Receipt of grants/research support

X ☒ Receipt of honoraria and travel support  
from Cook, Gore, Medtronic

# To stay out of troubles

- Patient selection
- Case planning
- Operation
- Quality control

# To get out of troubles

- Improve fixation/seal
- Outflow management
- Endoleaks

# To stay out of troubles

- Patient selection
- Case planning
- Operation
- Quality control

# Management of Abdominal Aortic Aneurysms

## Clinical Practice Guidelines of the European Society for Vascular Surgery

F.L. Moll <sup>a,\*</sup>, J.T. Powell <sup>b</sup>, G. Fraedrich <sup>c</sup>, F. Verzini <sup>d</sup>, S. Haulon <sup>e</sup>,  
M. Waltham <sup>f</sup>, J.A. van Herwaarden <sup>a</sup>, P.J.E. Holt <sup>g</sup>, J.W. van Keulen <sup>a,h</sup>,  
B. Rantner <sup>c</sup>, F.J.V. Schlösser <sup>h</sup>, F. Setacci <sup>i</sup>, J.-B. Ricco <sup>j</sup>

Eur J Vasc Endovasc Surg (2011) 41, S1–S58

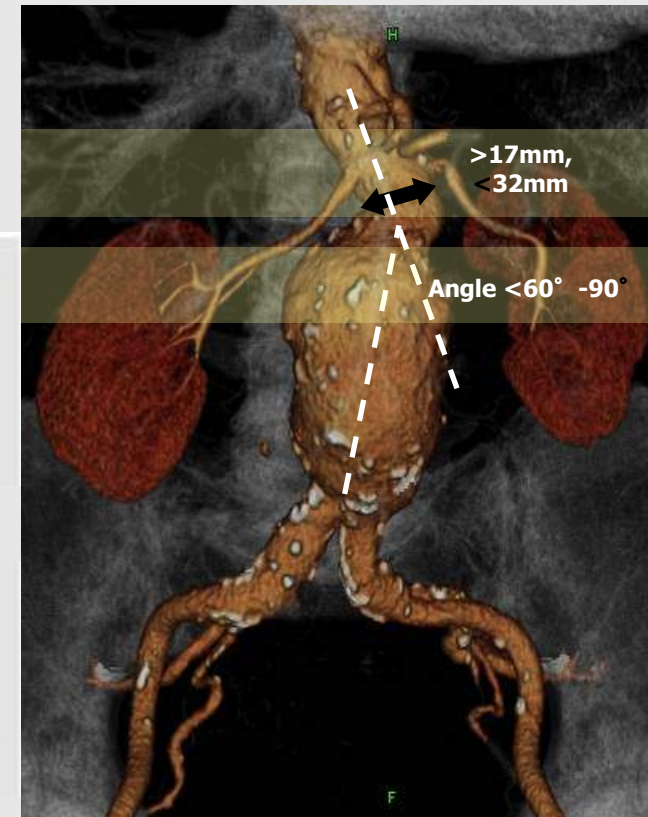
**Table 8** Minimal requirements for standard commercially available endografts.

### Proximal aortic neck

Neck diameter  $>17$  mm,  $< 32$  mm

Angle between the suprarenal aorta and the juxtarenal aorta  $<60^\circ$

Angle between the juxtarenal aorta and the long axis of the aneurysm sac  $<60^\circ$ – $90^\circ$





# Management of Abdominal Aortic Aneurysms Clinical Practice Guidelines of the European Society for Vascular Surgery

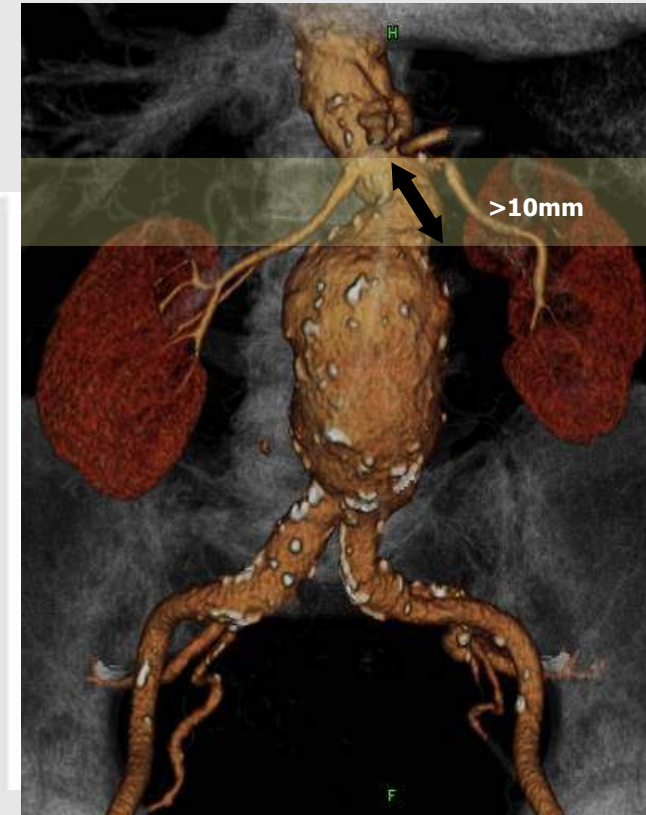
F.L. Moll <sup>a,\*</sup>, J.T. Powell <sup>b</sup>, G. Fraedrich <sup>c</sup>, F. Verzini <sup>d</sup>, S. Haulon <sup>e</sup>,  
M. Waltham <sup>f</sup>, J.A. van Herwaarden <sup>a</sup>, P.J.E. Holt <sup>g</sup>, J.W. van Keulen <sup>a,h</sup>,  
B. Rantner <sup>c</sup>, F.J.V. Schlösser <sup>h</sup>, F. Setacci <sup>i</sup>, J.-B. Ricco <sup>j</sup>

Eur J Vasc Endovasc Surg (2011) 41, S1–S58

**Table 8** Minimal requirements for standard commercially available endografts.

---

- Neck length >10 mm;
- Neck thrombus covering <50% of the proximal neck circumference
- Neck dilated <3 mm within 10 mm of the most caudal renal artery
- Focal neck enlargement <3 mm within 15 mm from the most caudal renal artery
- Neck calcification <50% of the proximal neck circumference



# Management of Abdominal Aortic Aneurysms

## Clinical Practice Guidelines of the European Society for Vascular Surgery

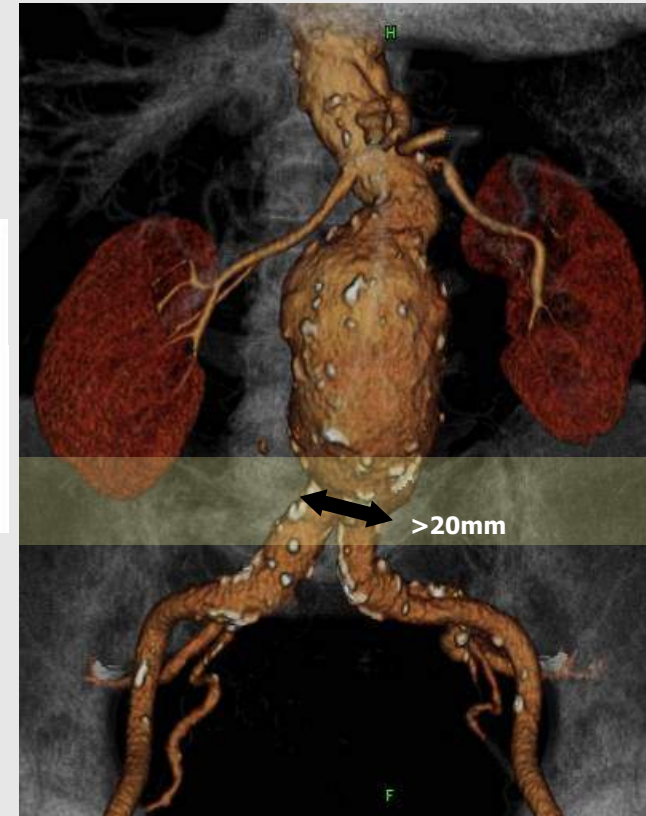
F.L. Moll <sup>a,\*</sup>, J.T. Powell <sup>b</sup>, G. Fraedrich <sup>c</sup>, F. Verzini <sup>d</sup>, S. Haulon <sup>e</sup>,  
M. Waltham <sup>f</sup>, J.A. van Herwaarden <sup>a</sup>, P.J.E. Holt <sup>g</sup>, J.W. van Keulen <sup>a,h</sup>,  
B. Rantner <sup>c</sup>, F.J.V. Schlösser <sup>h</sup>, F. Setacci <sup>i</sup>, J.-B. Ricco <sup>j</sup>

Eur J Vasc Endovasc Surg (2011) 41, S1–S58

**Table 8** Minimal requirements for standard commercially available endografts.

**Aortic bifurcation**

Aortic bifurcation diameter >20 mm in case of a bifurcated graft





# Management of Abdominal Aortic Aneurysms

## Clinical Practice Guidelines of the European Society for Vascular Surgery

F.L. Moll <sup>a,\*</sup>, J.T. Powell <sup>b</sup>, G. Fraedrich <sup>c</sup>, F. Verzini <sup>d</sup>, S. Haulon <sup>e</sup>,  
M. Waltham <sup>f</sup>, J.A. van Herwaarden <sup>a</sup>, P.J.E. Holt <sup>g</sup>, J.W. van Keulen <sup>a,h</sup>,  
B. Rantner <sup>c</sup>, F.J.V. Schlösser <sup>h</sup>, F. Setacci <sup>i</sup>, J.-B. Ricco <sup>j</sup>

Eur J Vasc Endovasc Surg (2011) 41, S1–S58

**Table 8** Minimal requirements for standard commercially available endografts.

### Iliac artery

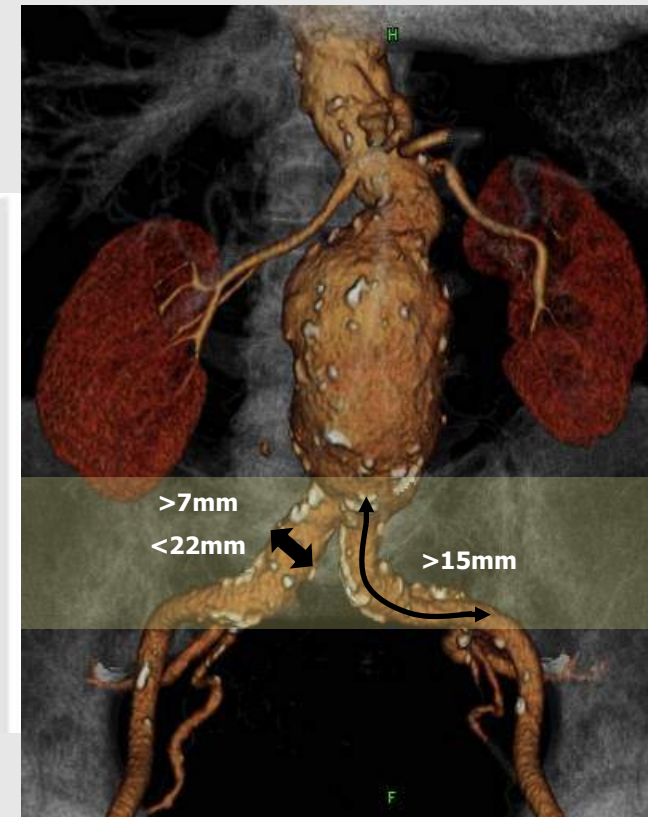
Iliac luminal diameter > 7 mm

Angle between the long axis of the aneurysm and the iliac axis < 60°

Iliac calcification: non extensively circumferential

Iliac neck diameter < 22 mm

Iliac neck length > 15 mm



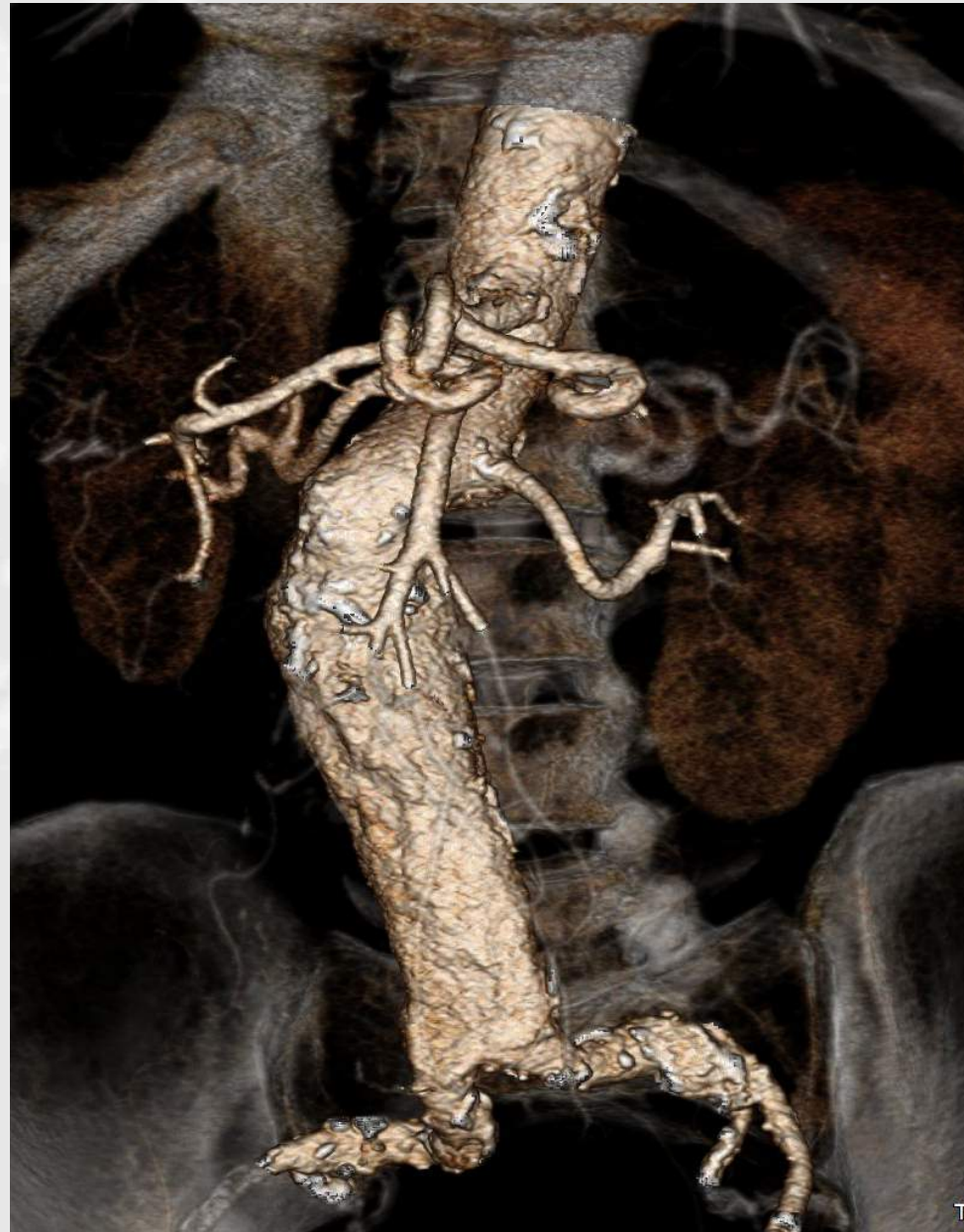
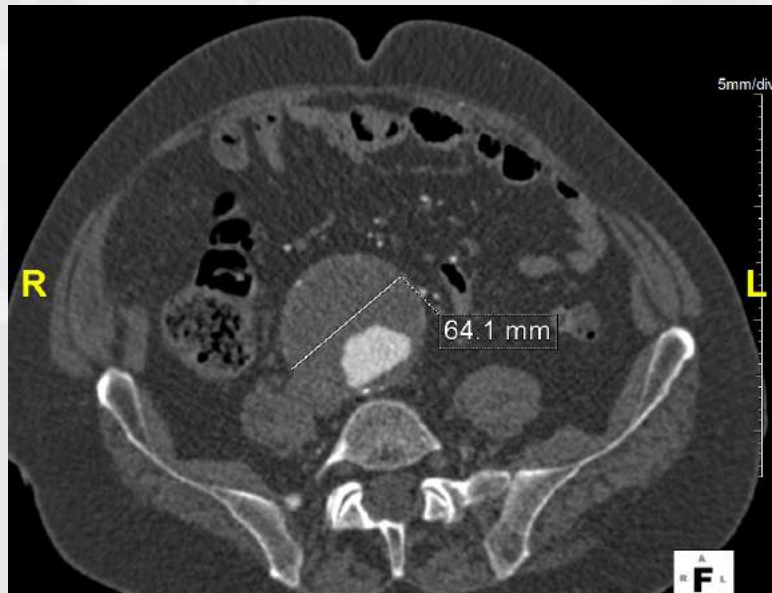
Male, 64 y.o.

62 mm AAA

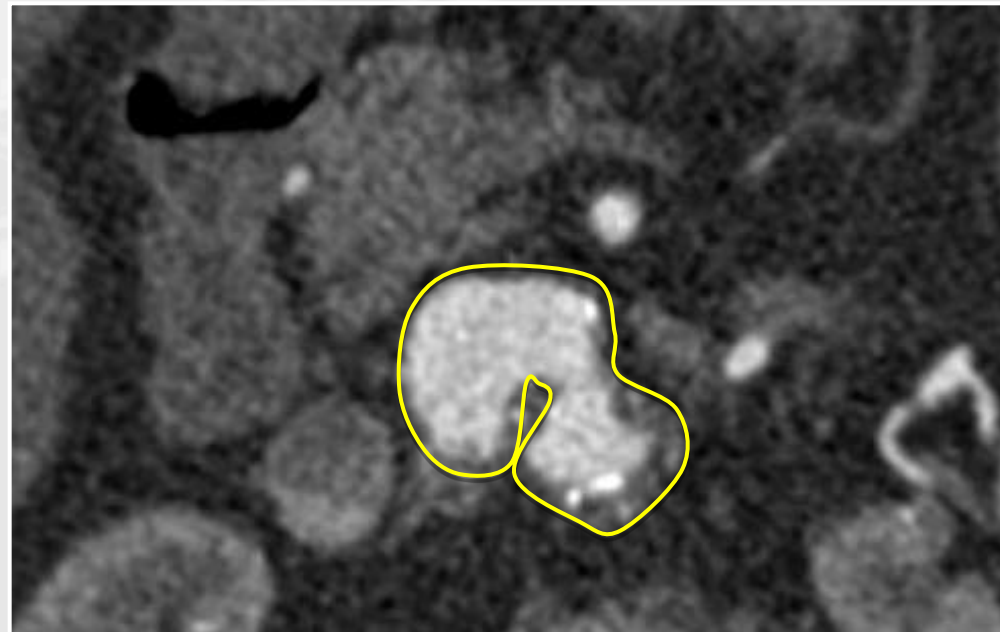
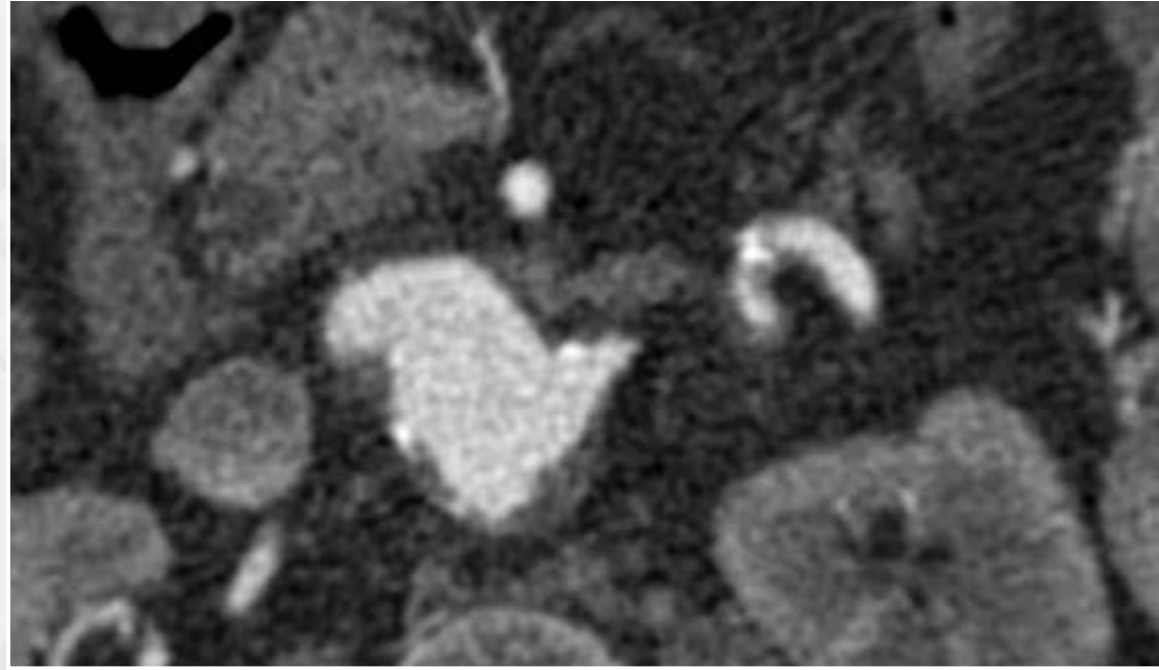
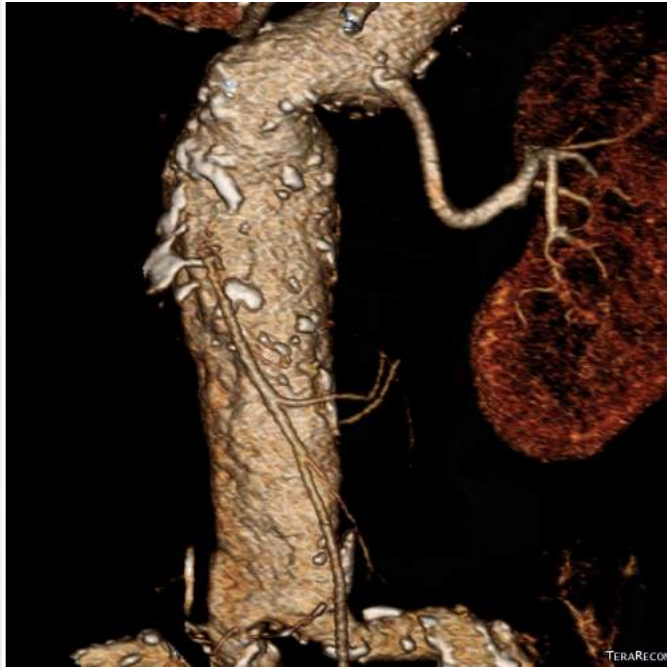CAD (previous CABG + PTCA)

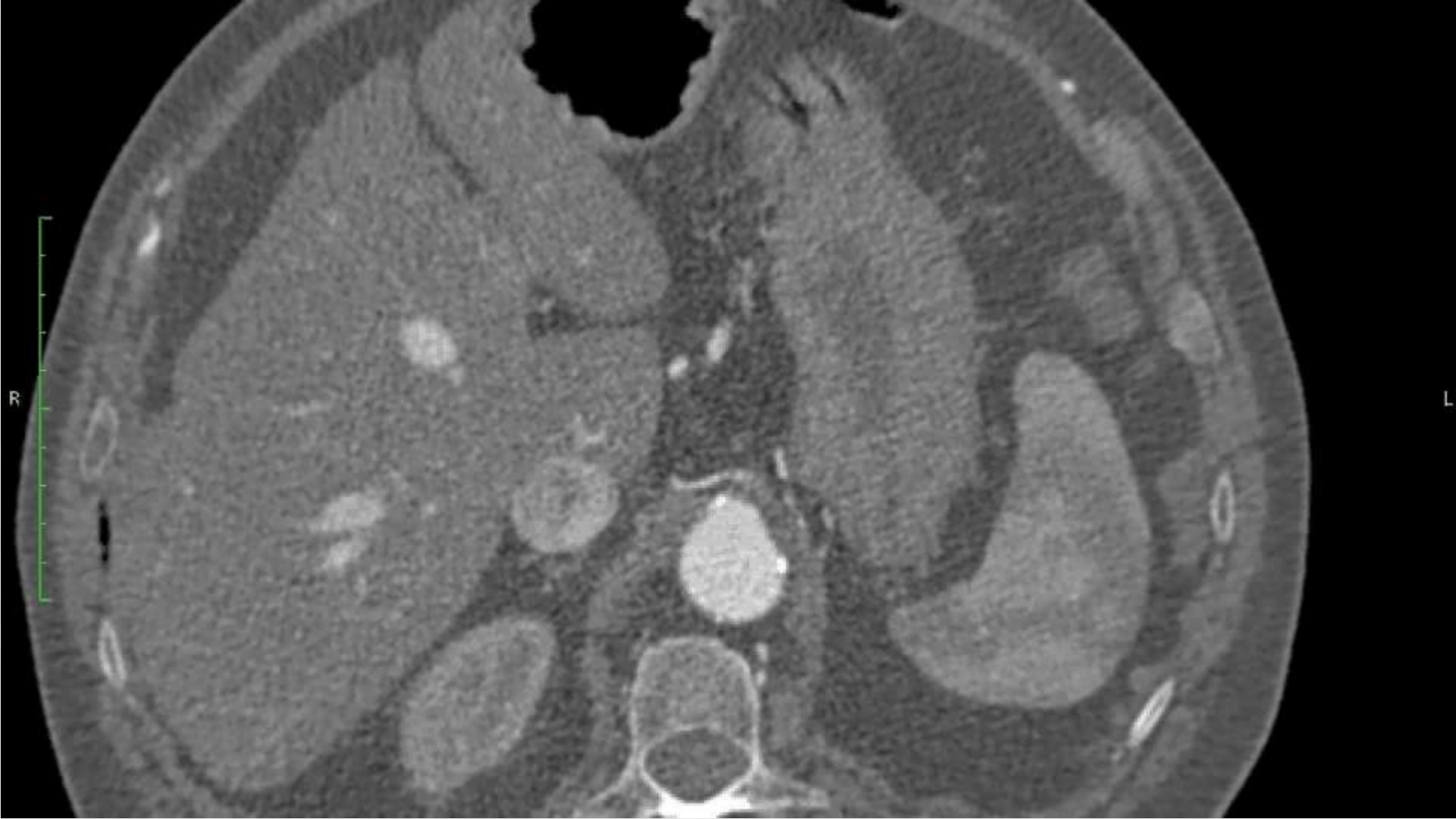
Chronic AF (warfarin)

Respiratory failure waiting for lung  
transplant









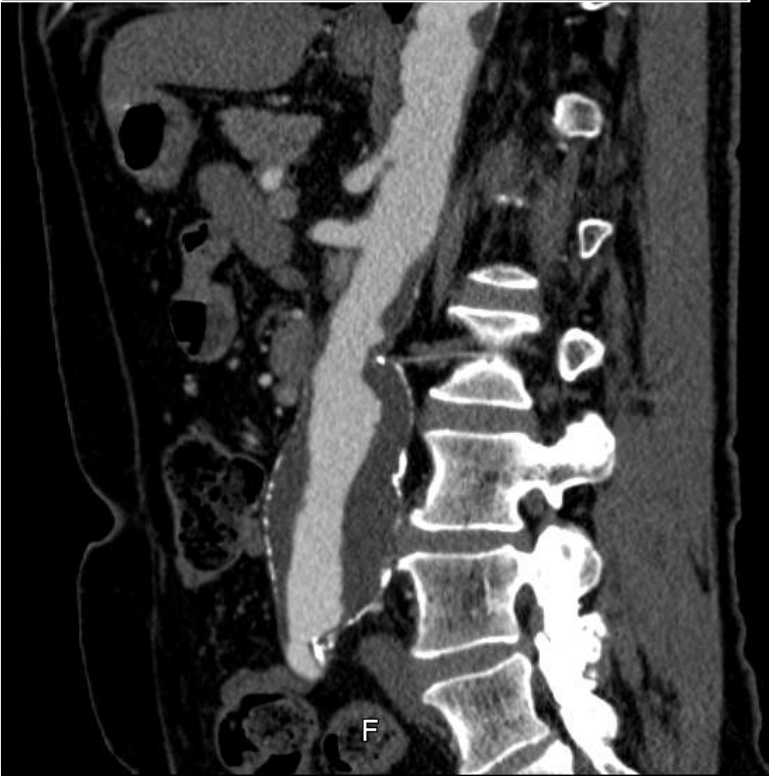

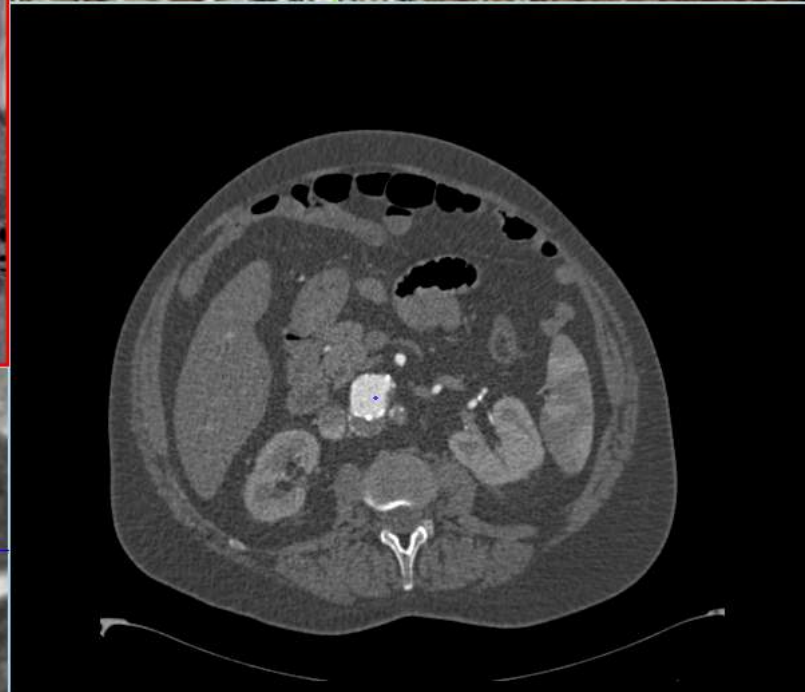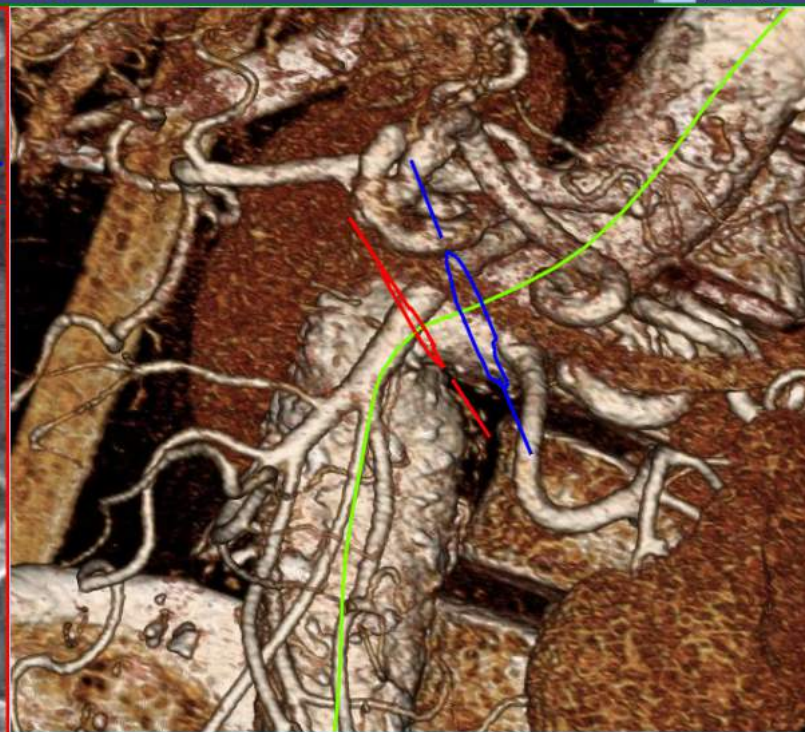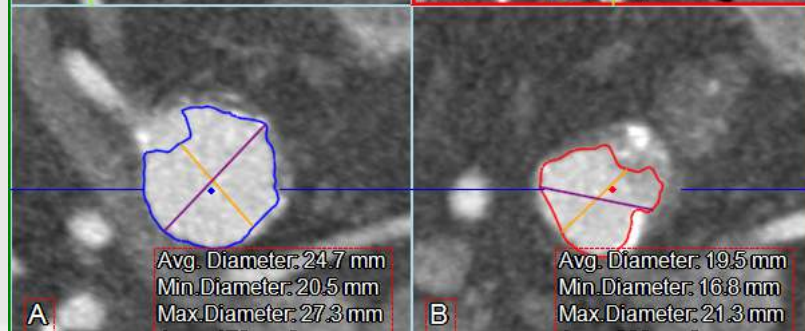
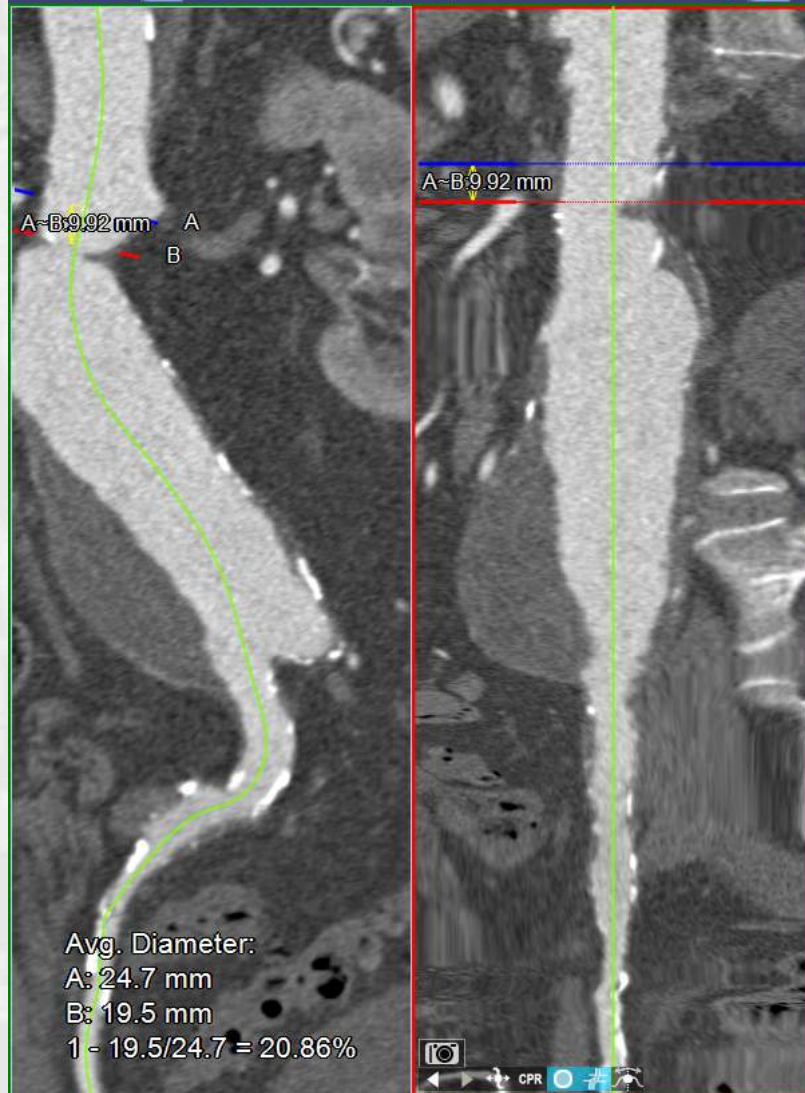
# To stay out of troubles

- Patient selection
- Case planning
- Operation
- Quality control

# Pre-op planning

- CT-Angio 1 mm (4-6 weeks)
- MPR (Multiplanar reconstruction)
- MIP (Maximum intensity projection)
- Center line analysis
- Thoracic-abdominal Ct-Angio





Workflow Template 3D Setting Series

VolBrowse

2x2 3D 1x1 3D 1x1 MIP

1x1 MPR 2x2 MIP 2x2 MPR

Left = Rotate on volume Middle = zoom or center Left + Right = W/L Alt + Left mouse = center in 2D or 3D images

Left = Slice on MPR Rt = Pan Middle + Rt = slice or scroll

Validate Add Output

Tool

Slab FreeROI Regio... Bone Batch

Auto Manual

Extract

List

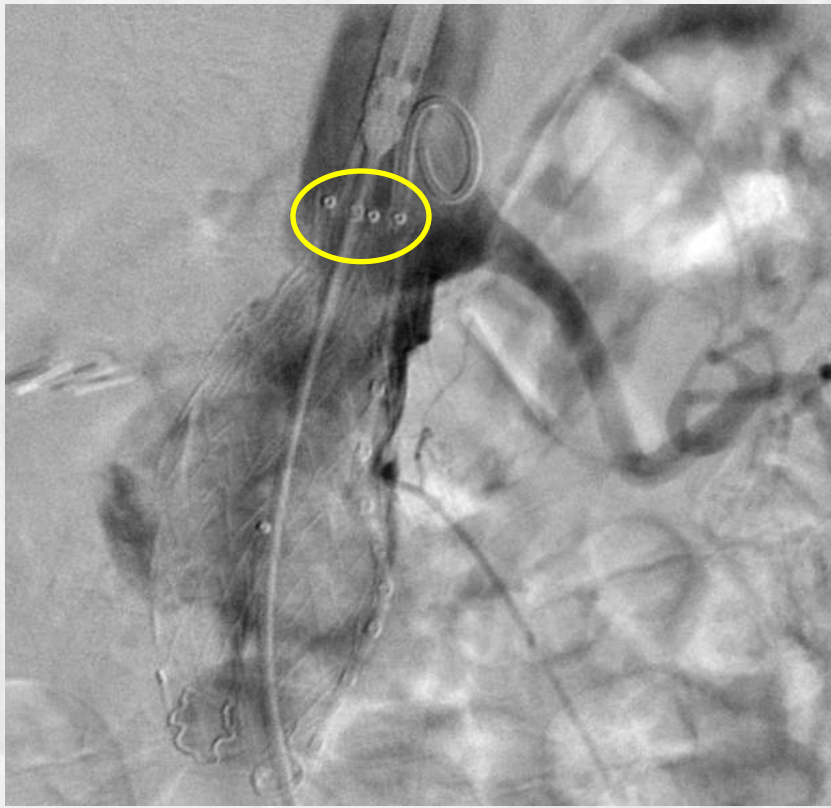Undo Clear Reverse 5 cc

Erosion/Dilation: -2 -1 +1 +2

3D MIP MPR MiniIP TMAP A S C

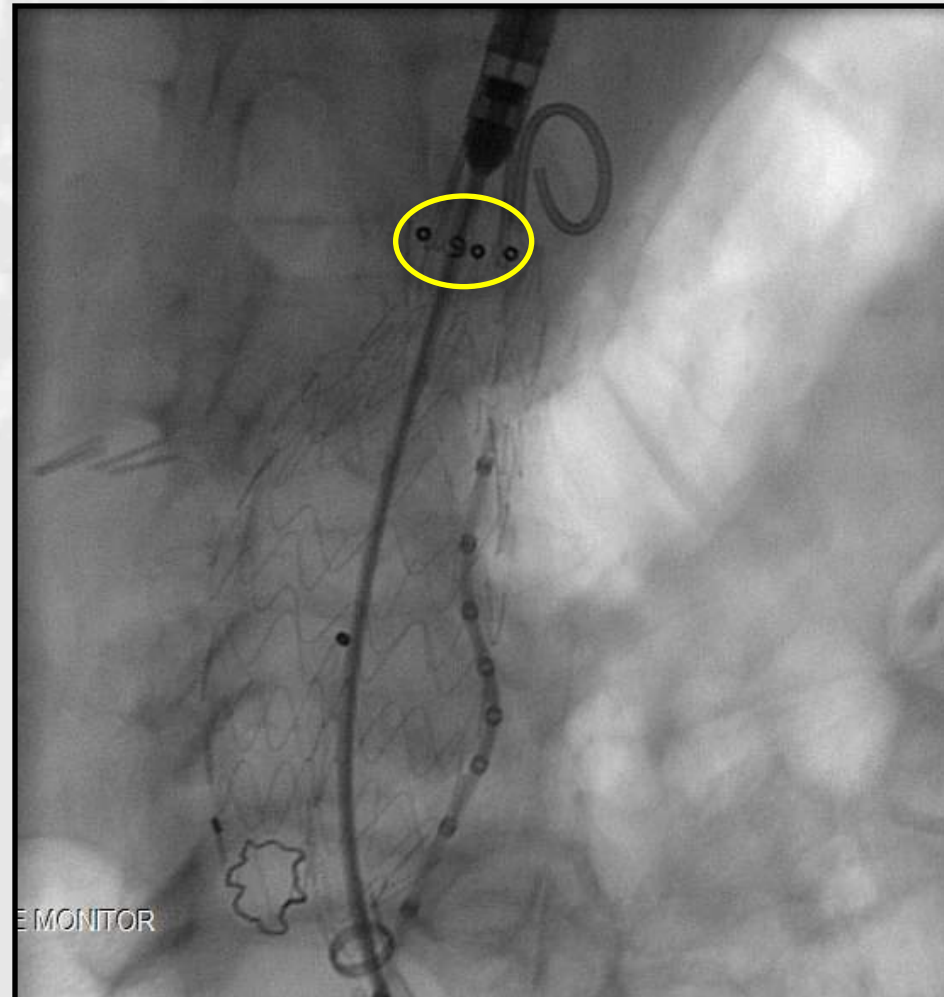
A H P R F L Reset Clear Mask



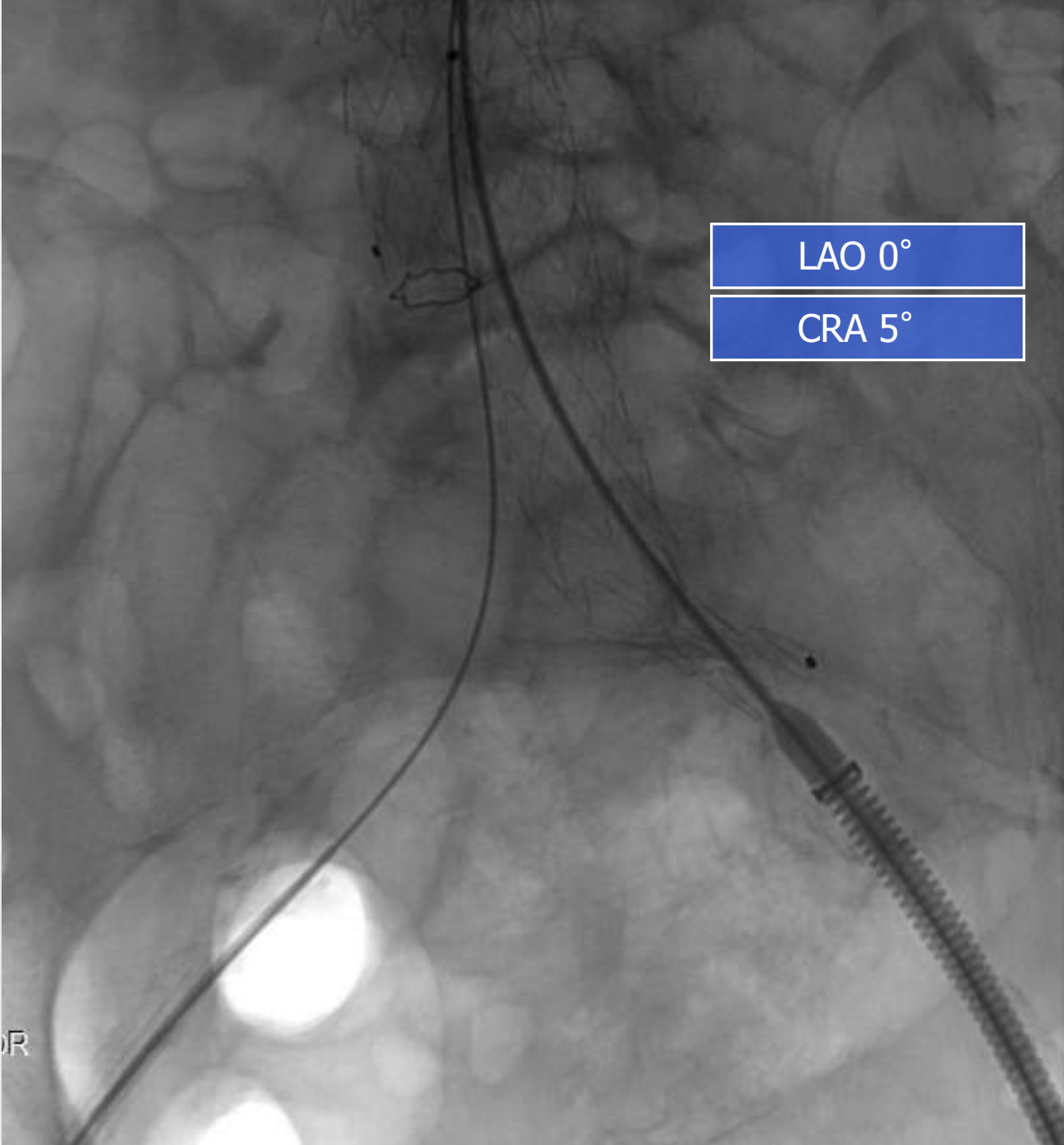


RAO 19°

CRA 10°



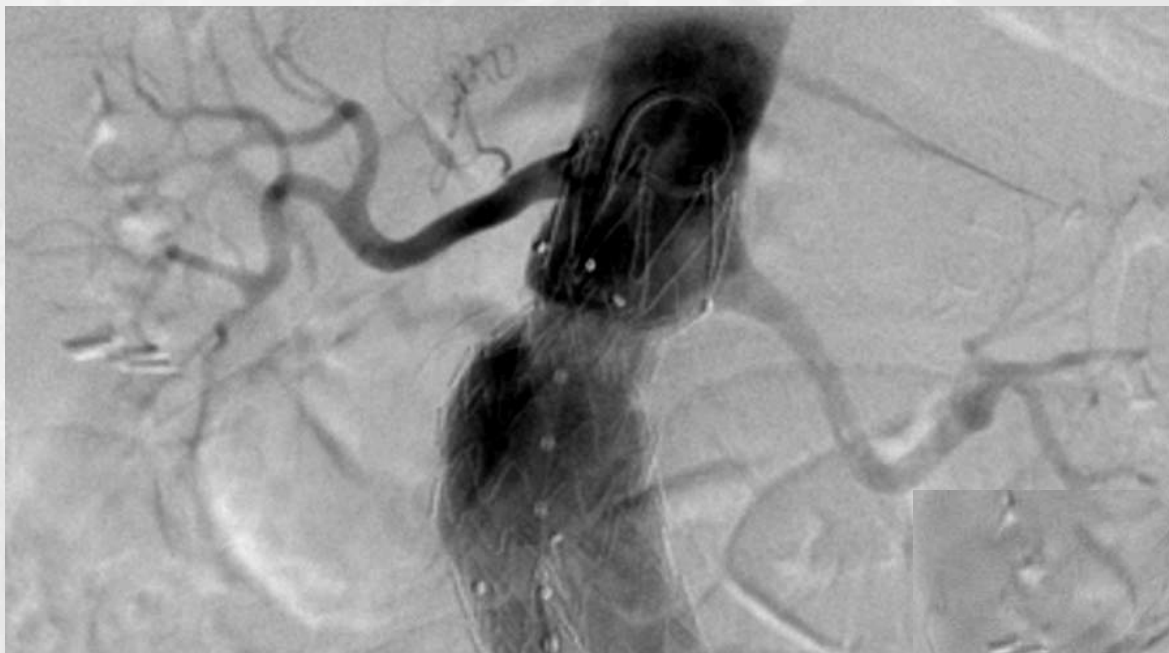




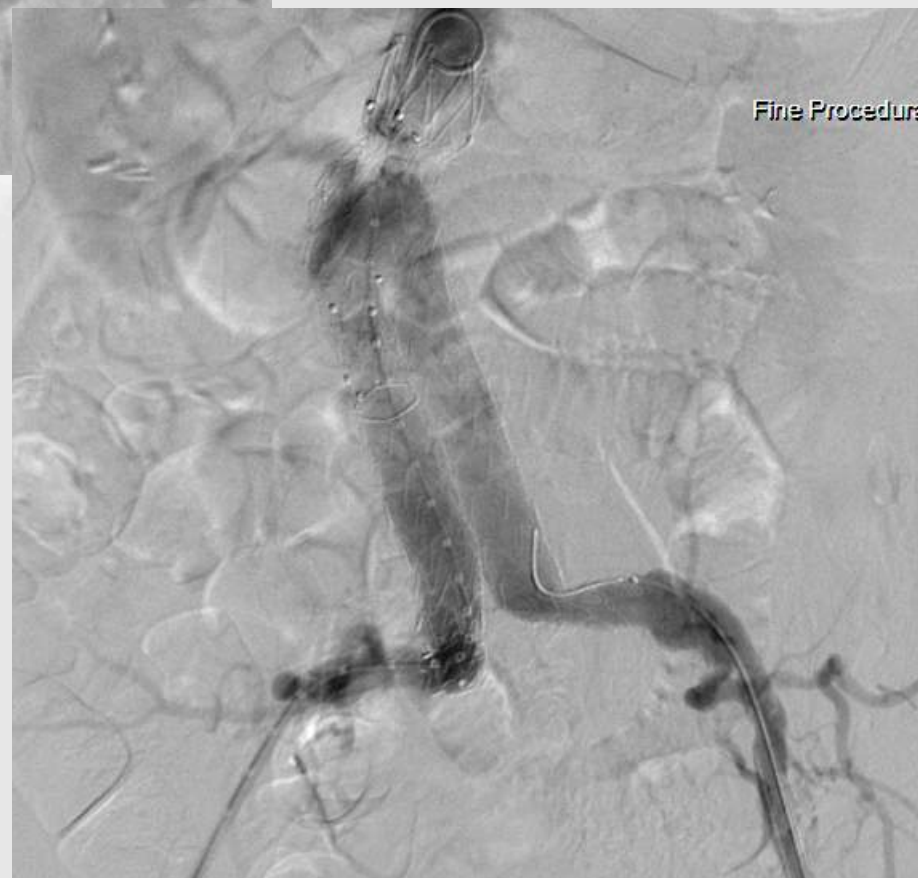LAO 0°

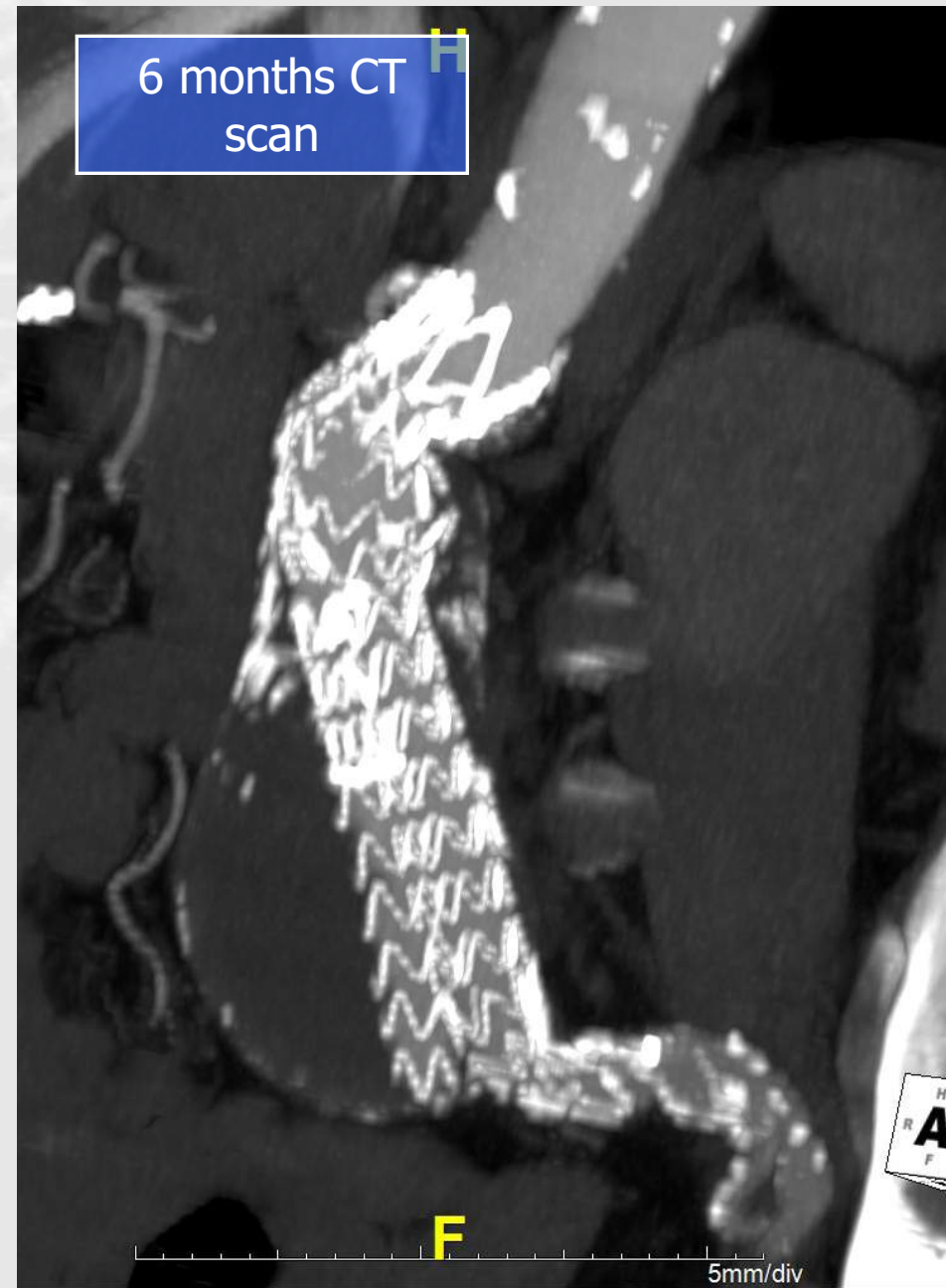
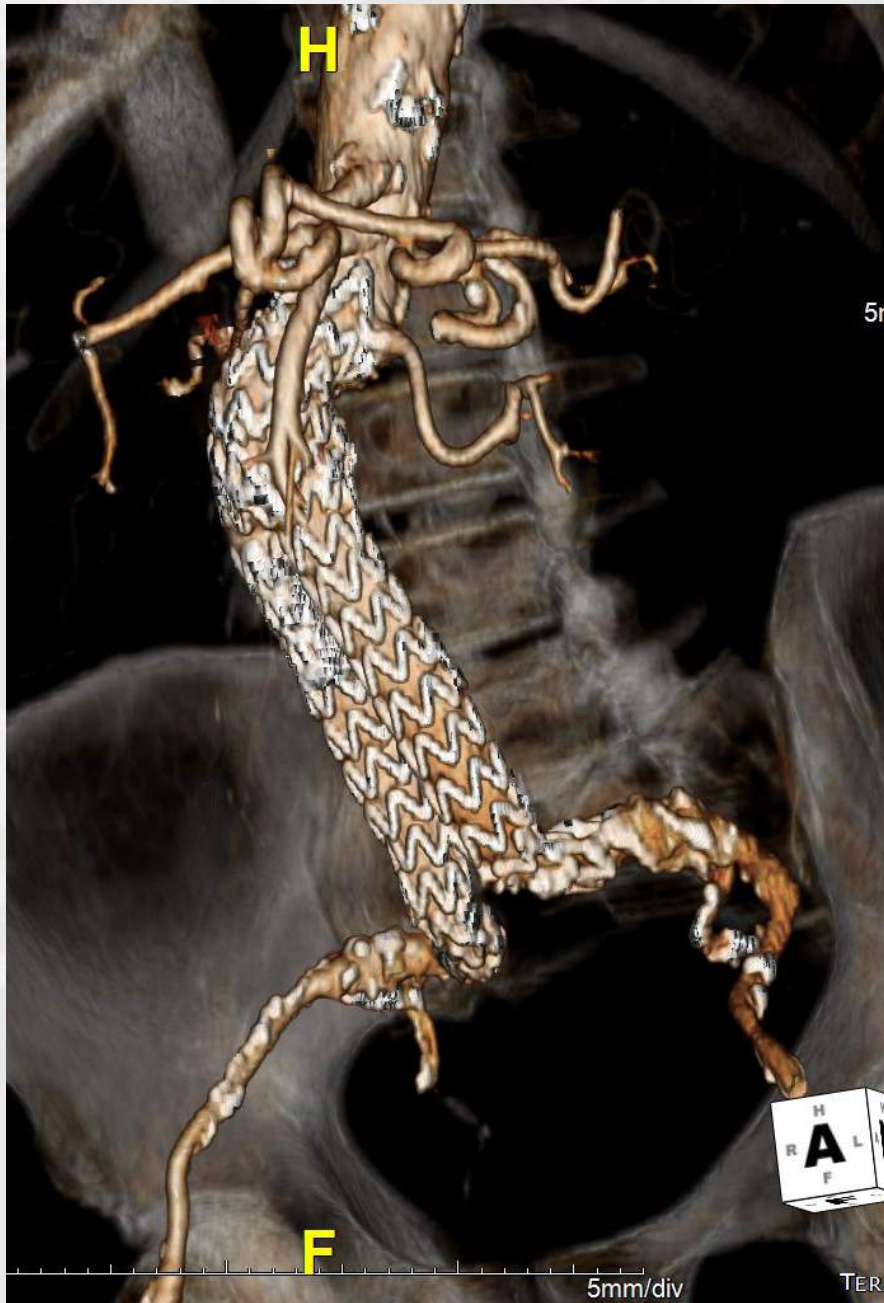CRA 5°

OR



Final Angio



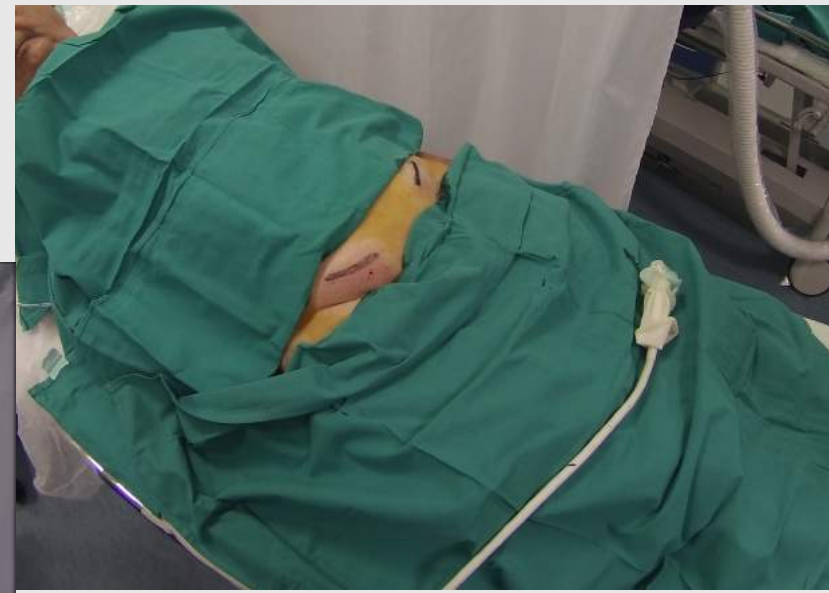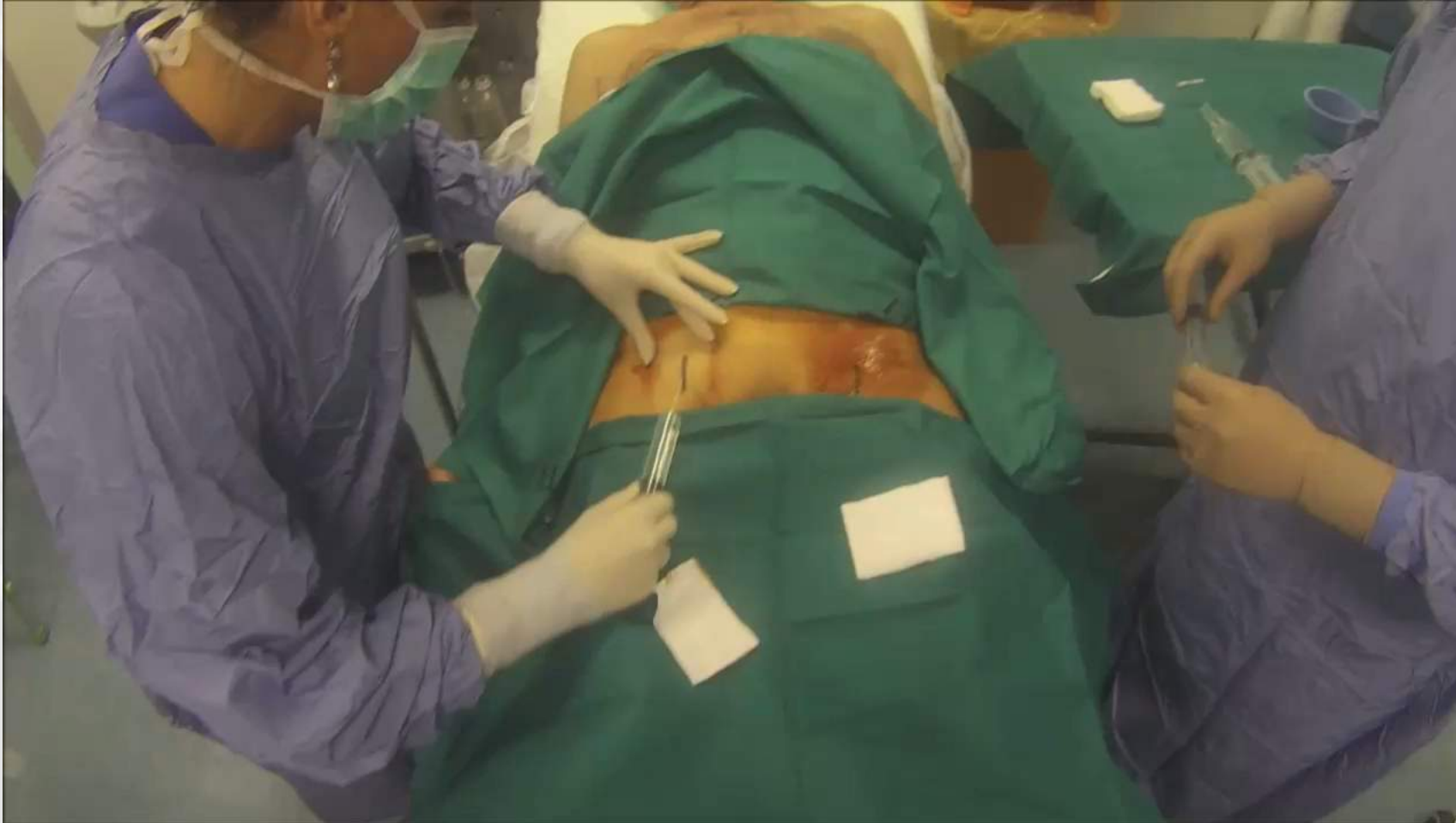


# To stay out of troubles

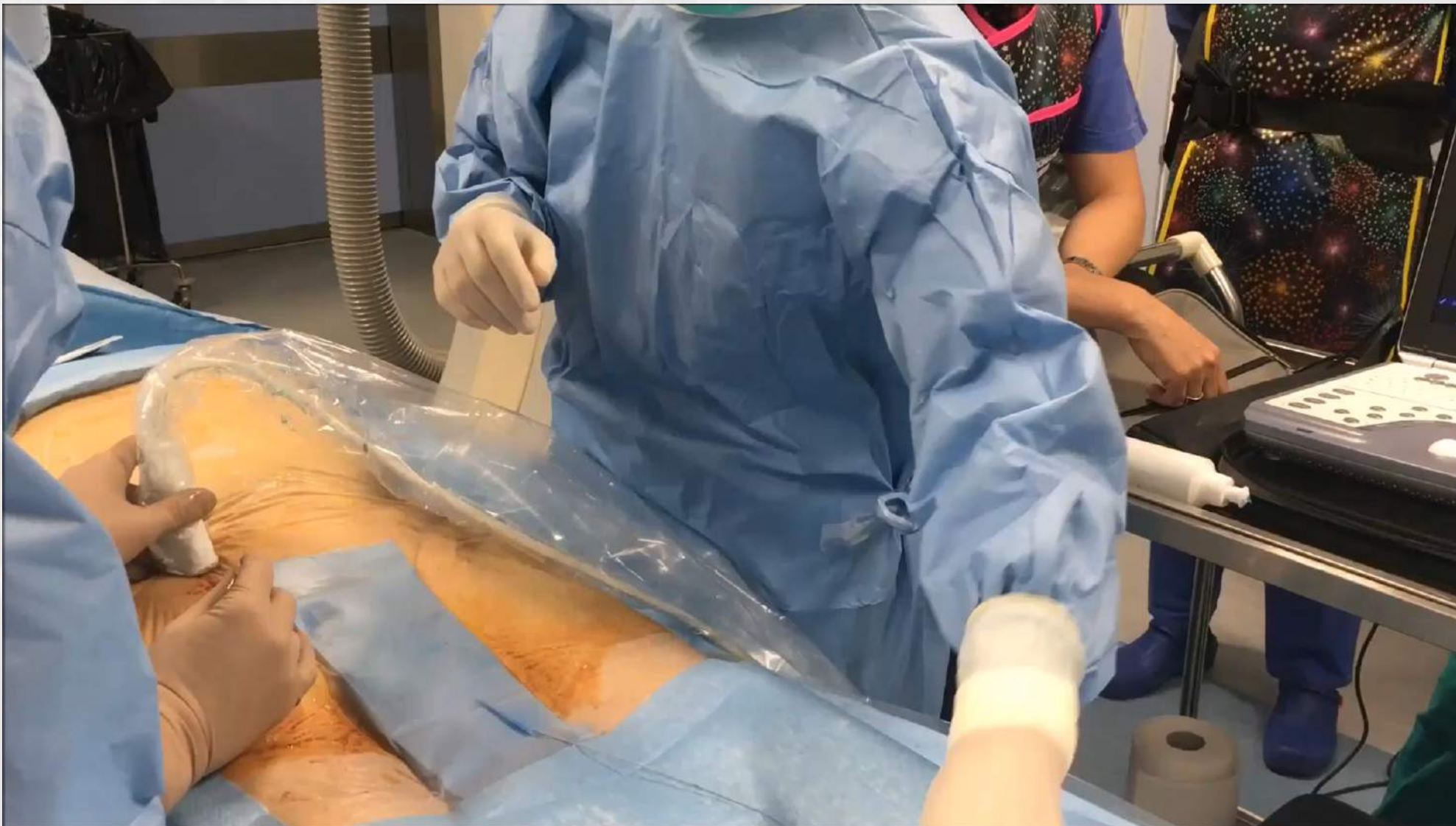- Patient selection
- Case planning
- Operation
- Quality control
- Local anesthesia
- Percutaneous access
- Intra-operative imaging
- Knowledge of specific graft characteristics



- Local anesthesia

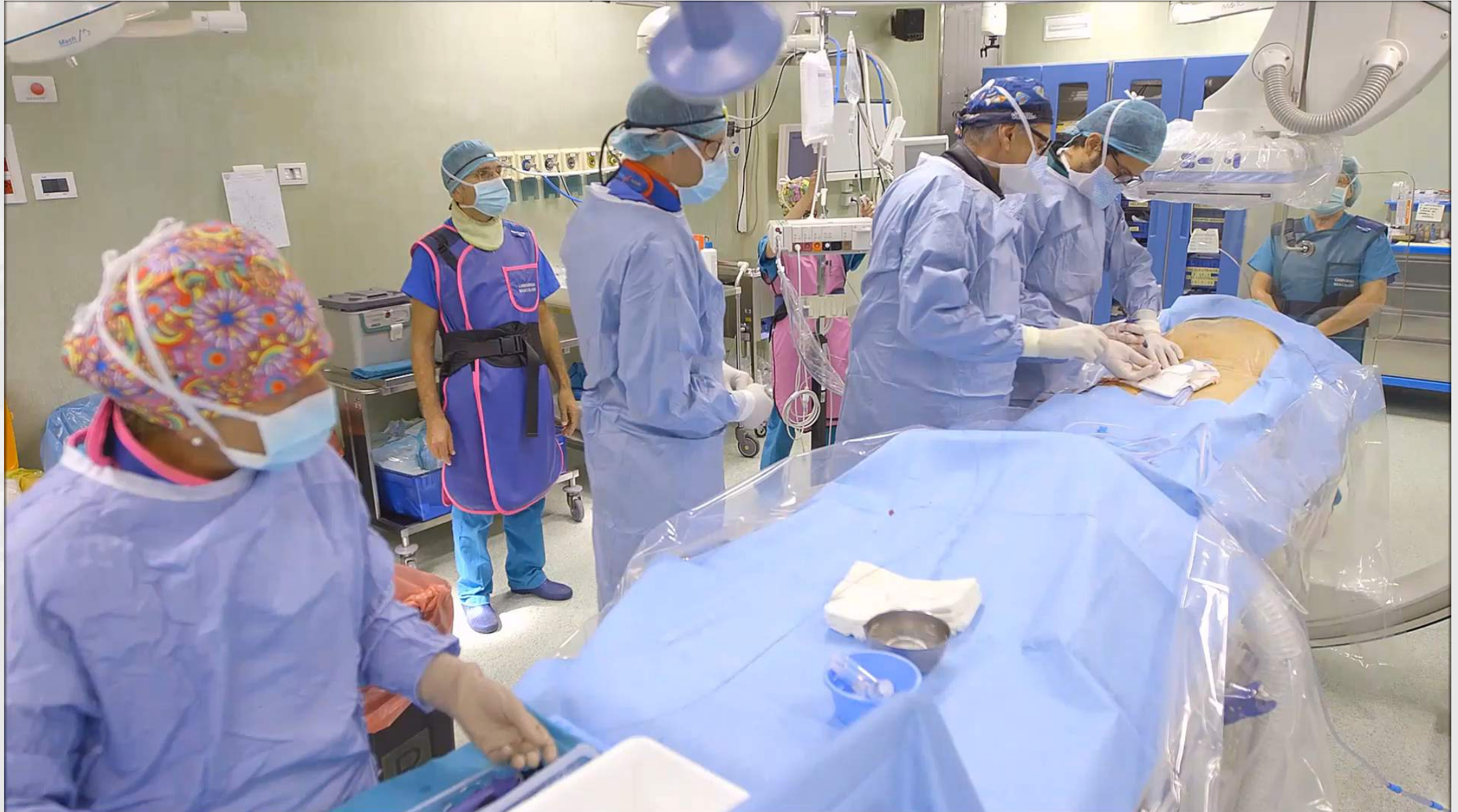

- Percutaneous access

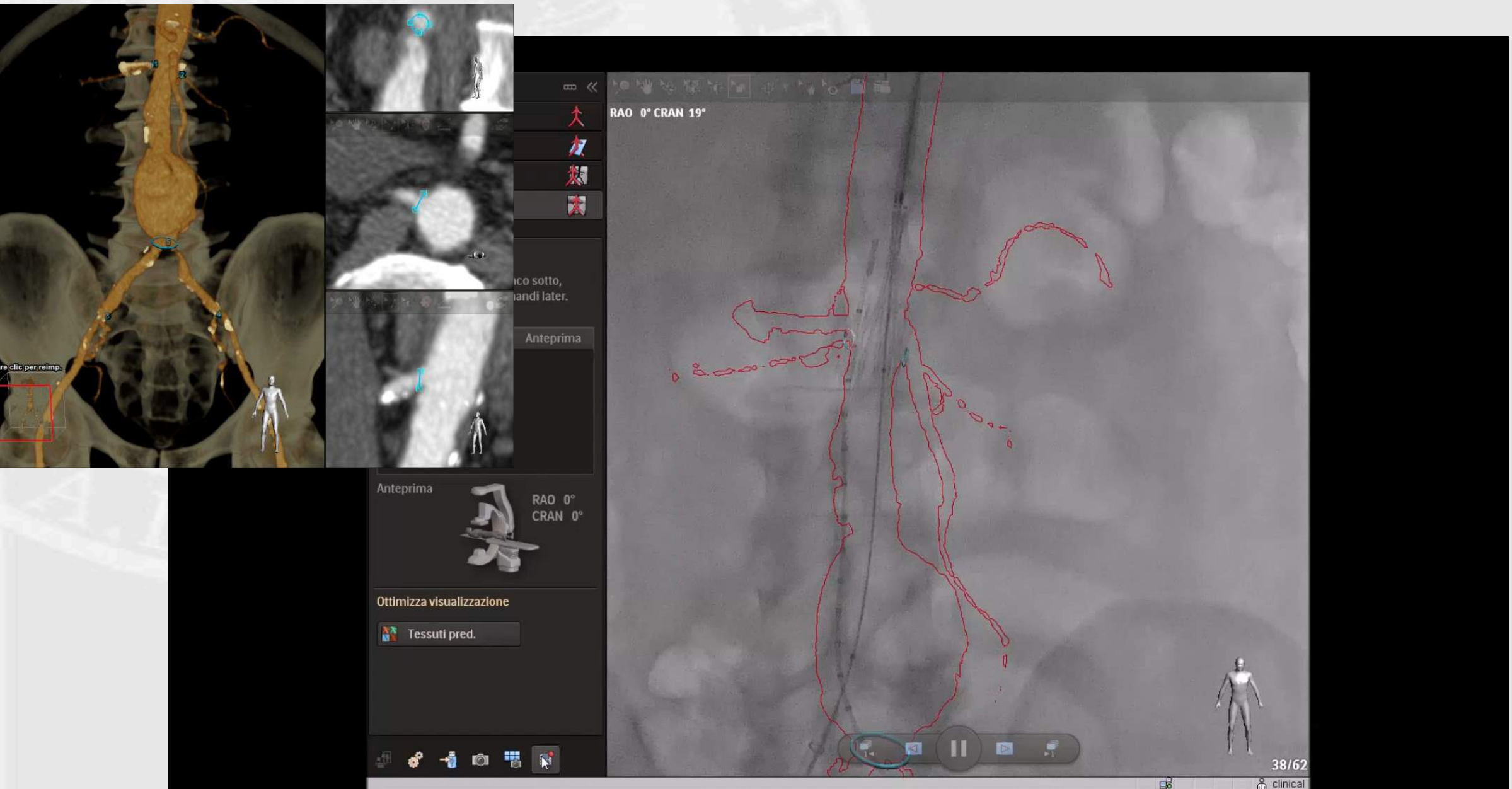



- Percutaneous access

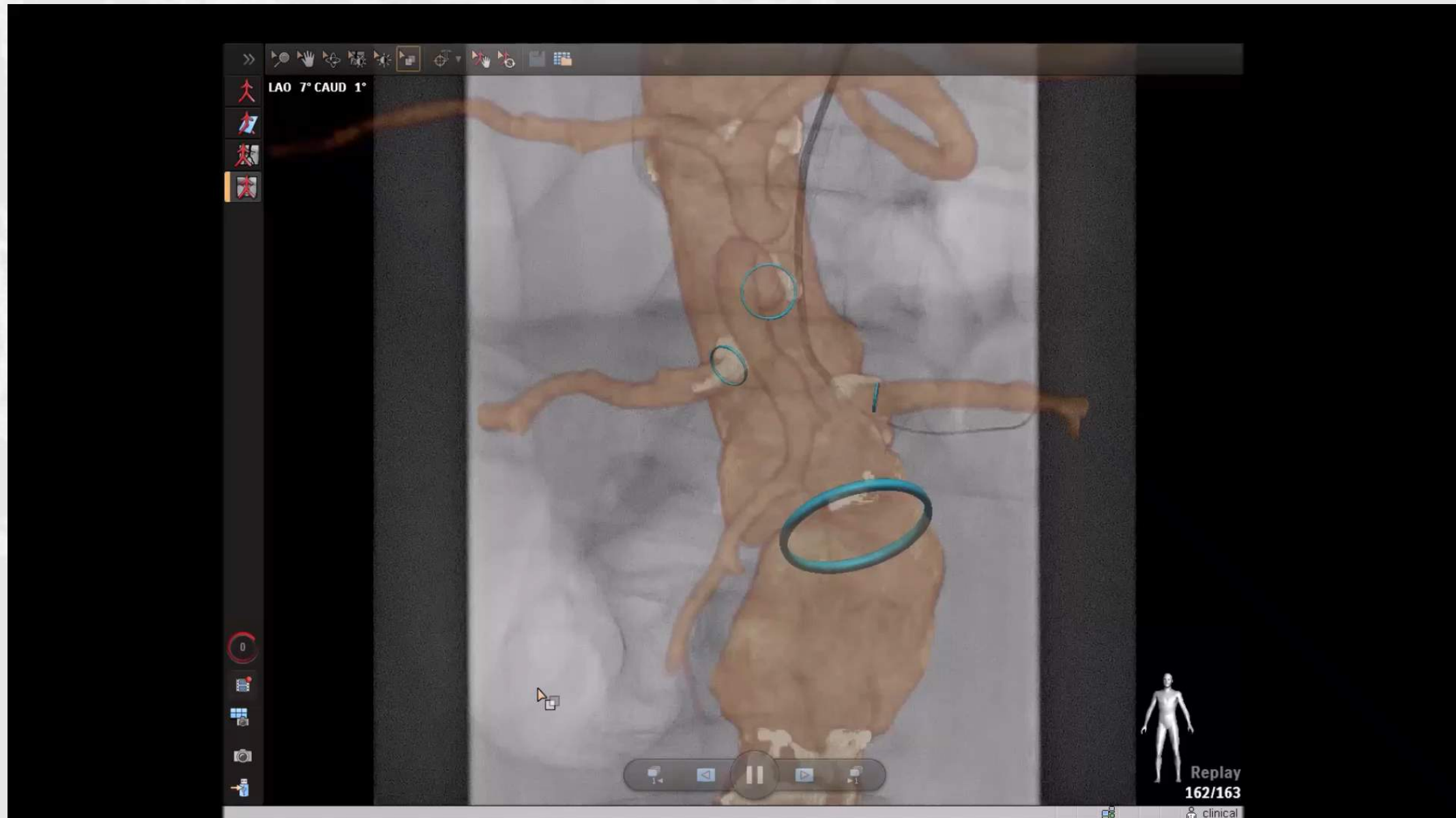


- Intra-operative imaging



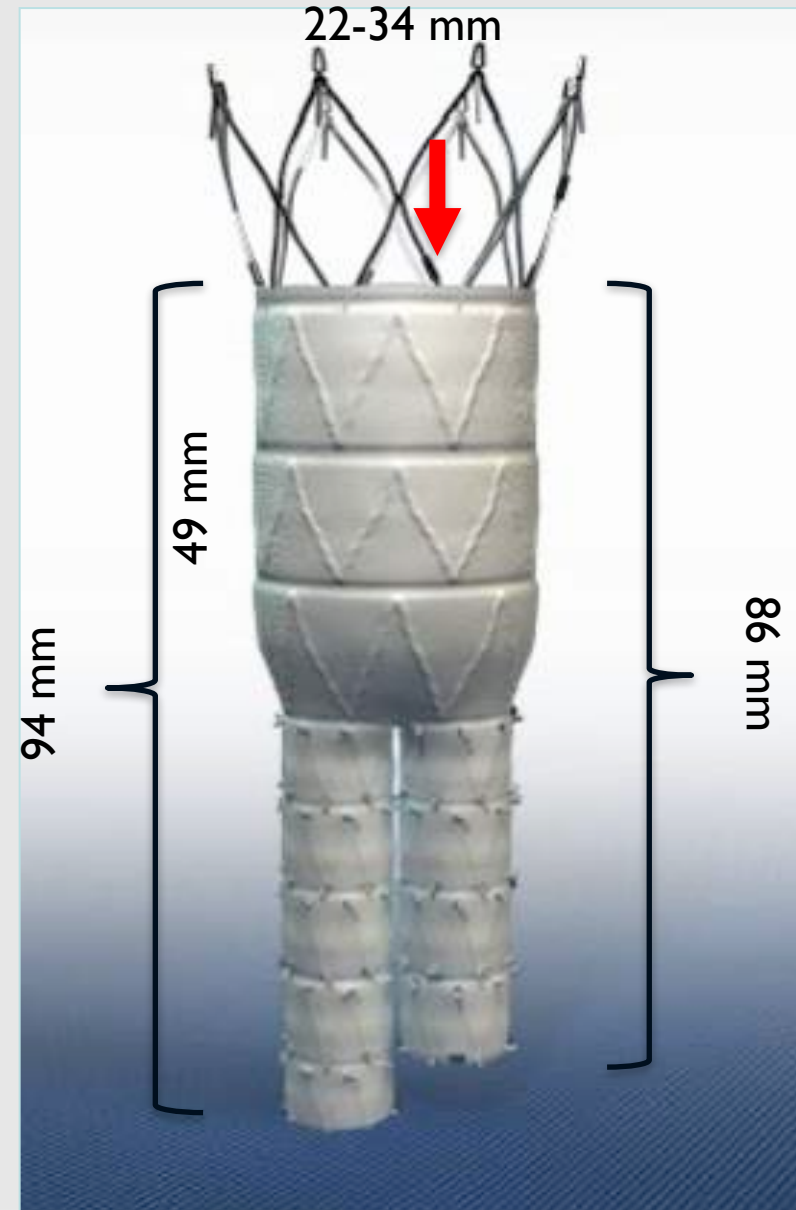
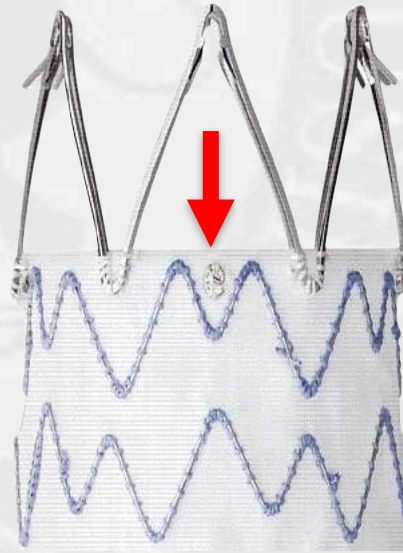


- Intra-operative imaging



- Knowledge of specific graft characteristics

Every mm of  
graft/neck apposition  
counts

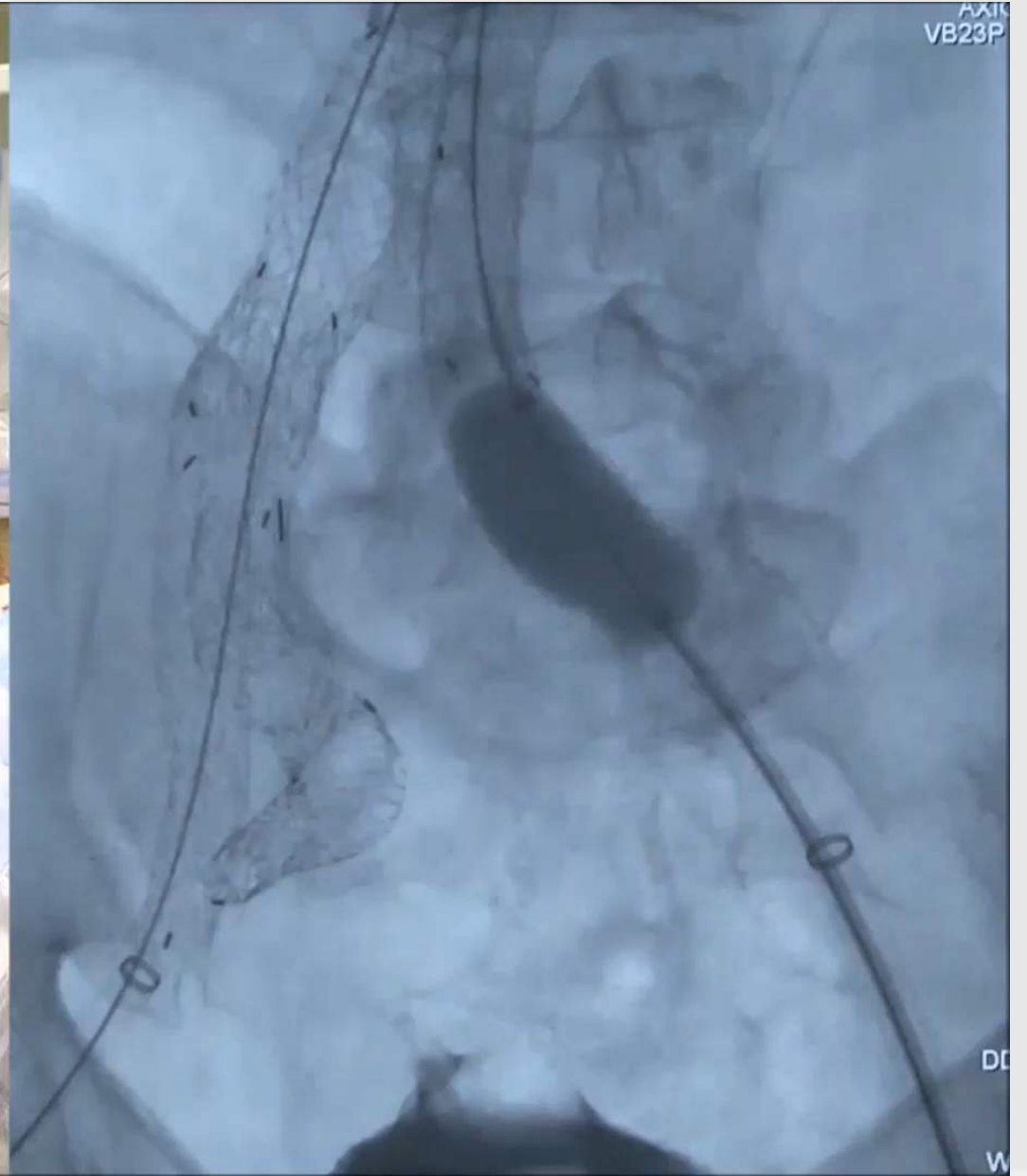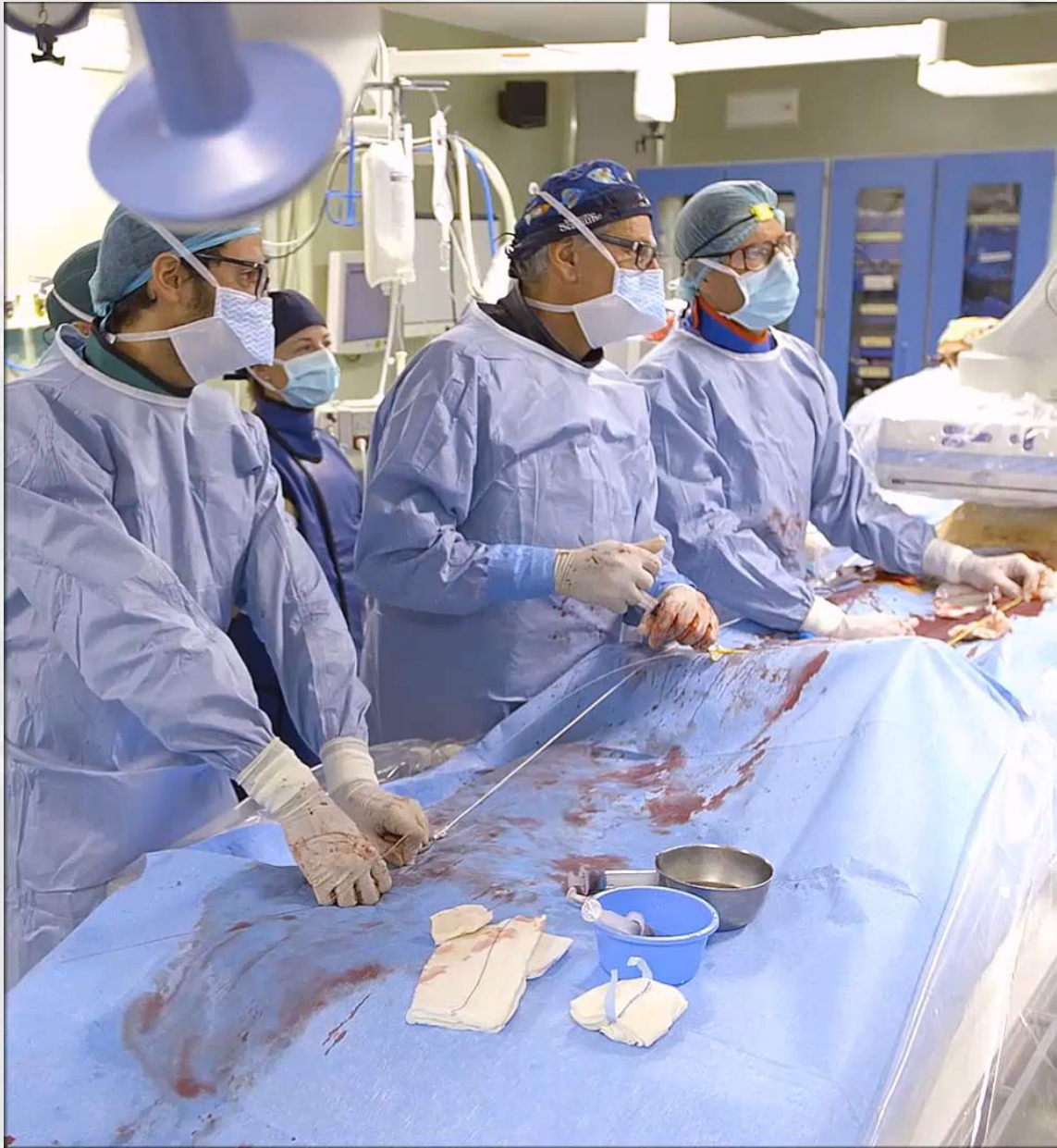


# To stay out of troubles

- Patient selection
- Case planning
- Operation
- **Quality control**

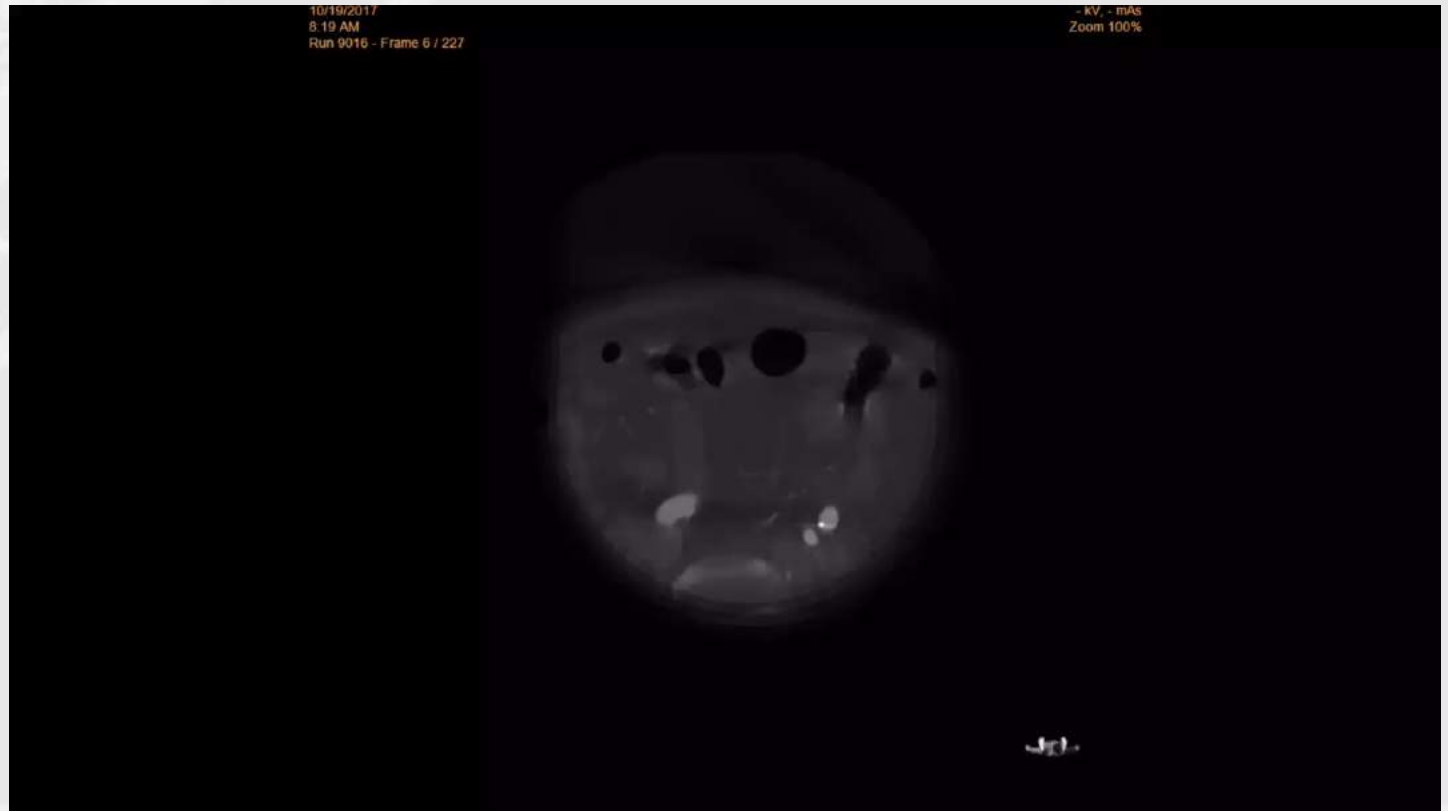
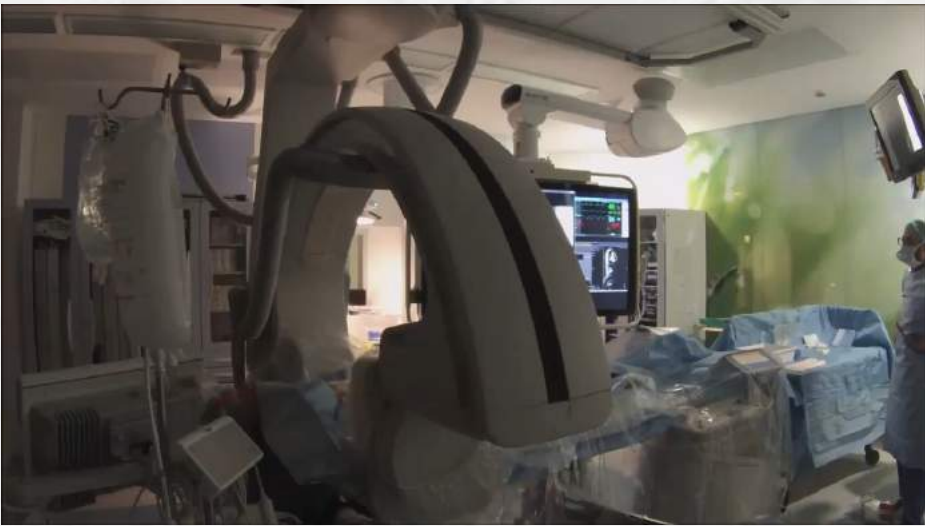
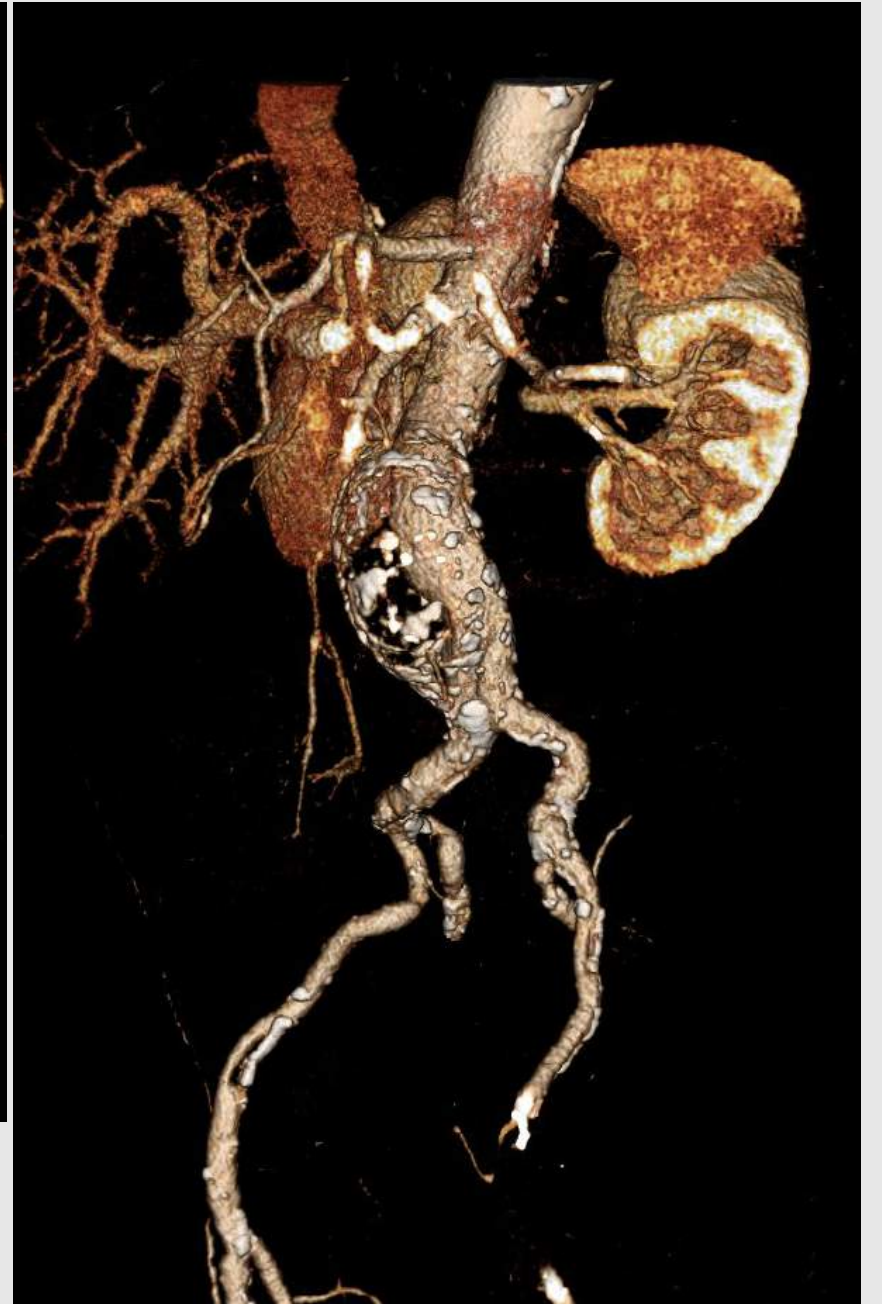
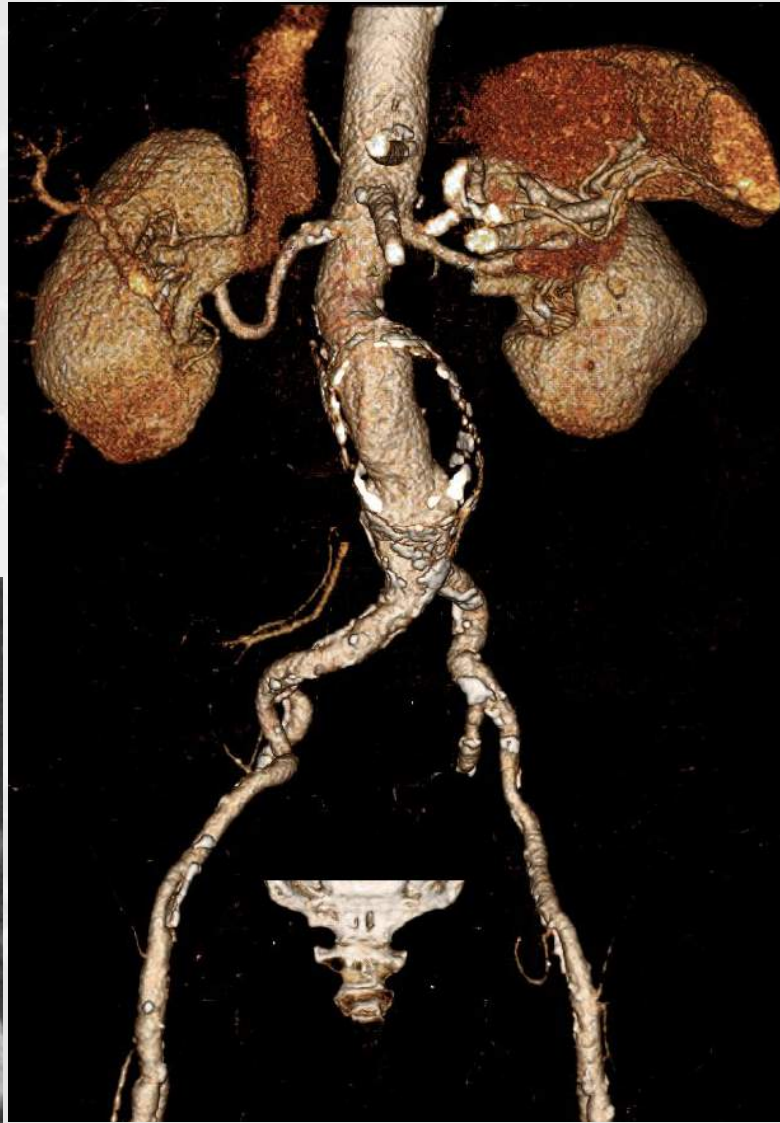
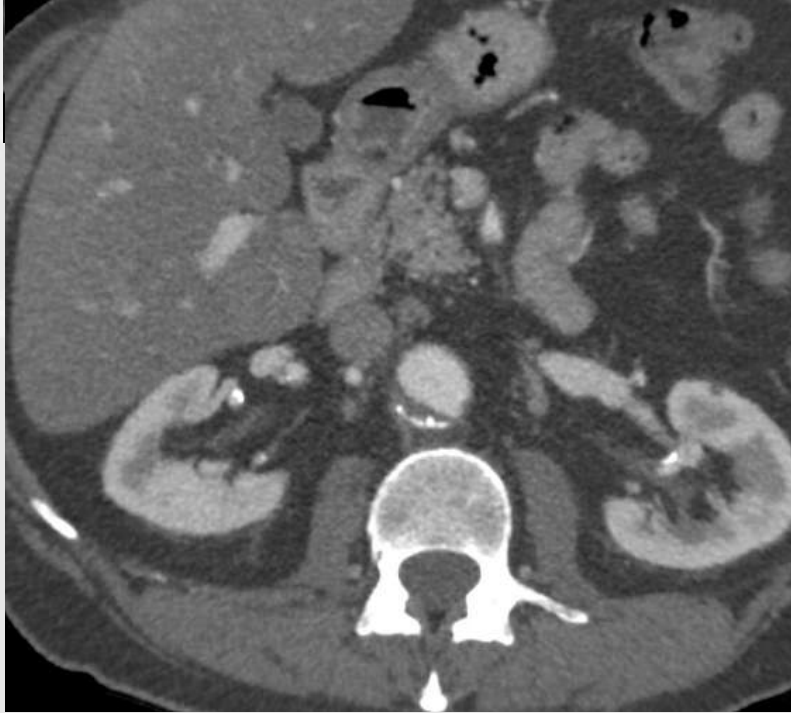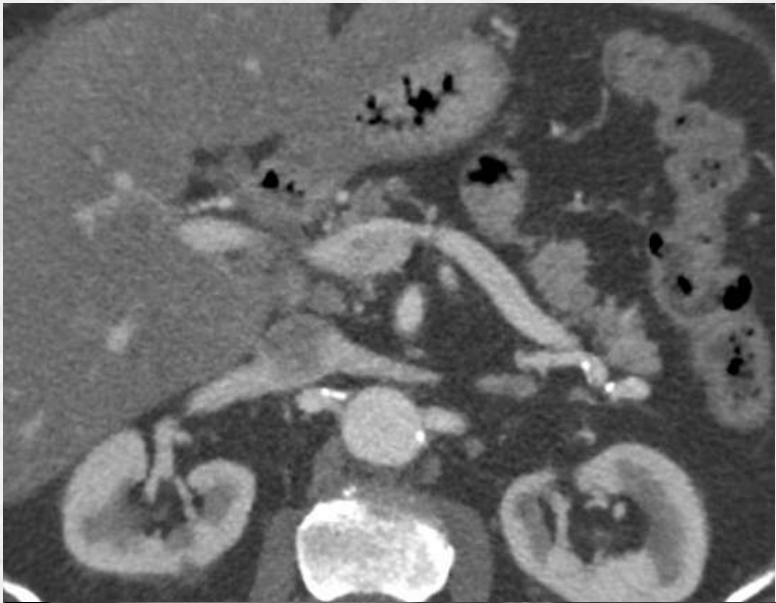
- Quality control



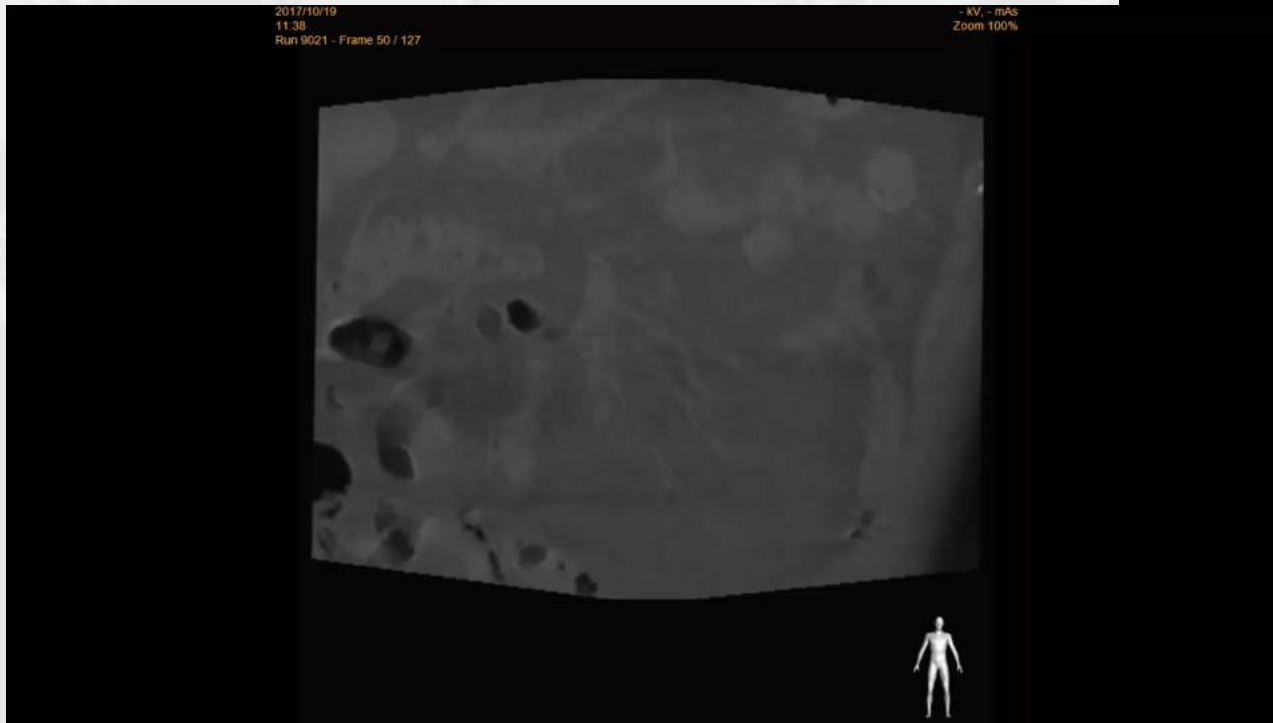
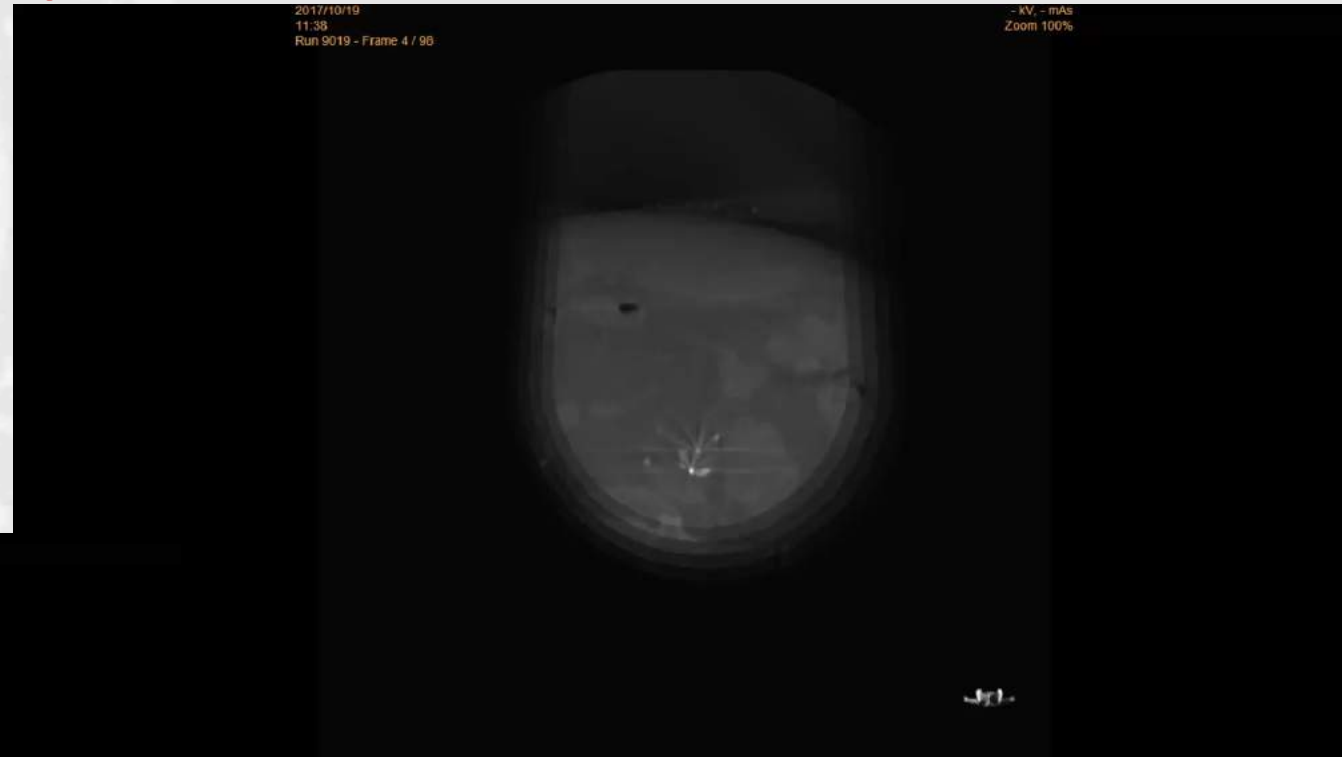

- Quality control



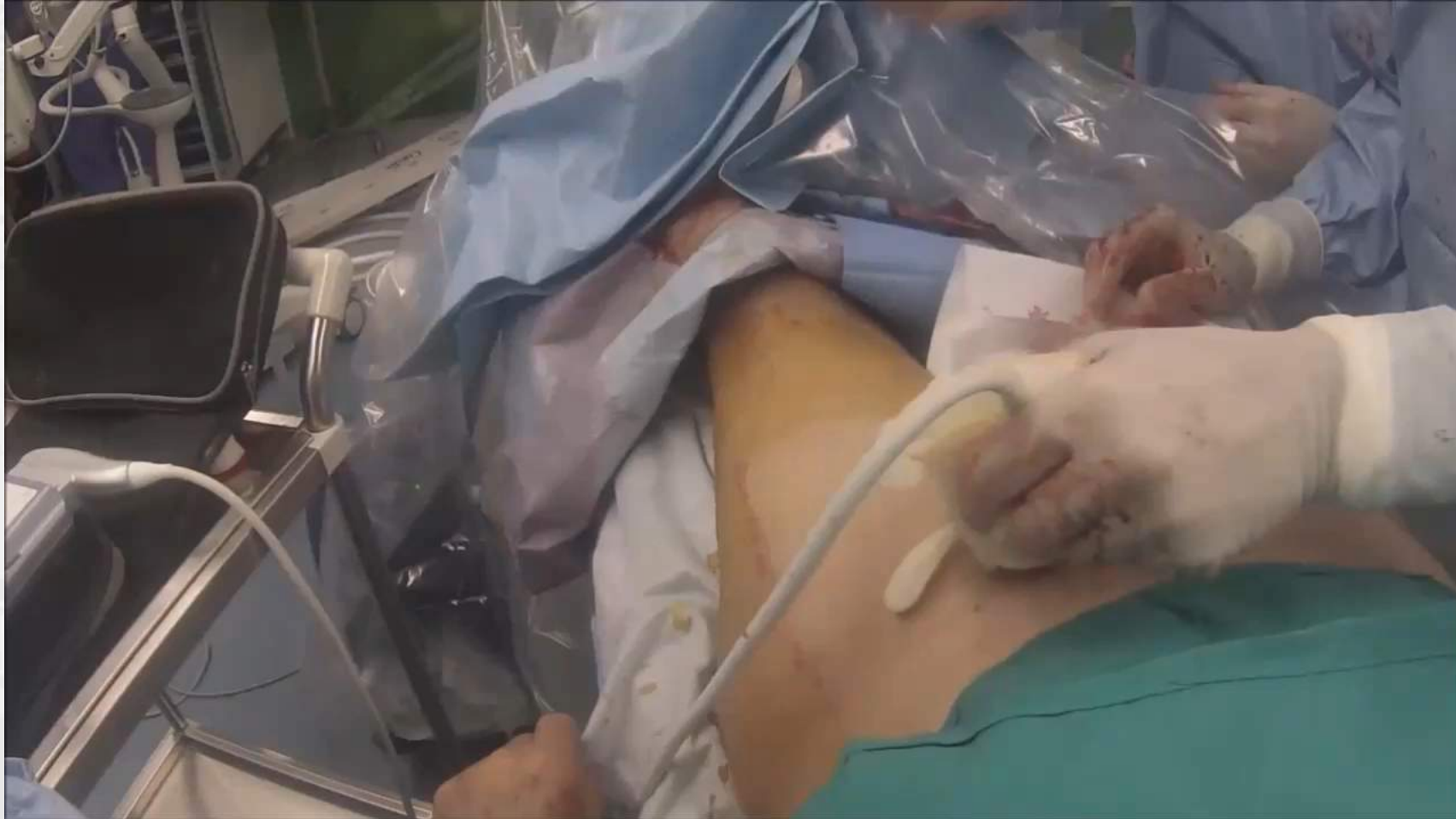

- Quality control





- Quality control







# Tips and tricks for successful EVAR

**Prof. Fabio Verzini , MD, PhD, FEBVS**

Section of Vascular Surgery  
University of Perugia,  
S.Maria della Misericordia Hospital,  
Perugia, Italy