

# EVAR with Preventive IMA Plug and Endoanchor Fixation



K. Oikonomou, K. Pfister, W. Schierling, P. Kasprzak  
Department of Vascular and Endovascular Surgery  
University Medical Centre Regensburg

# Case Presentation

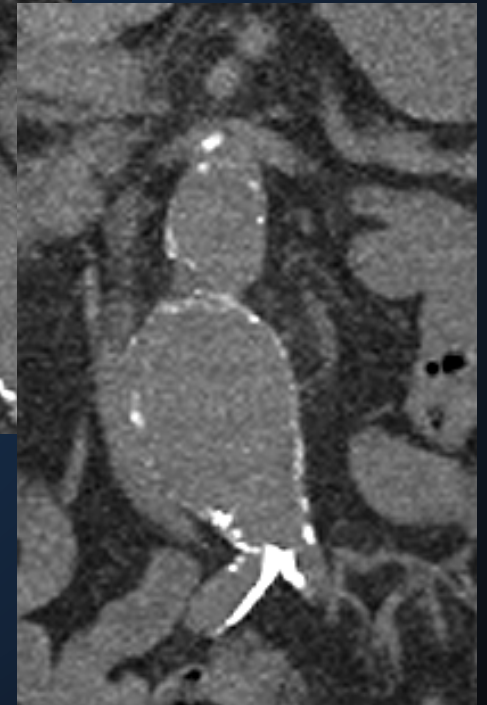
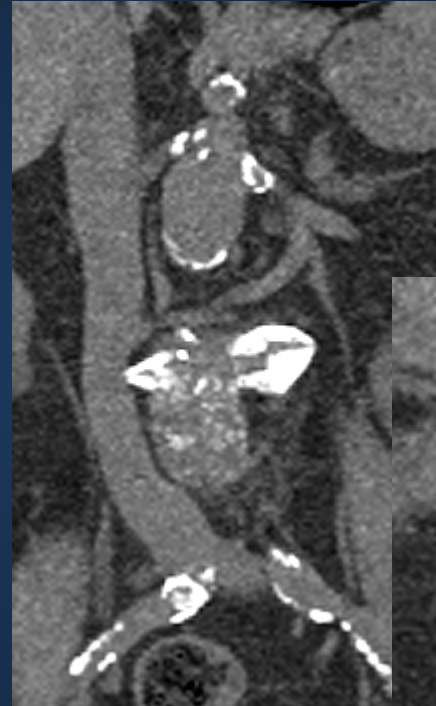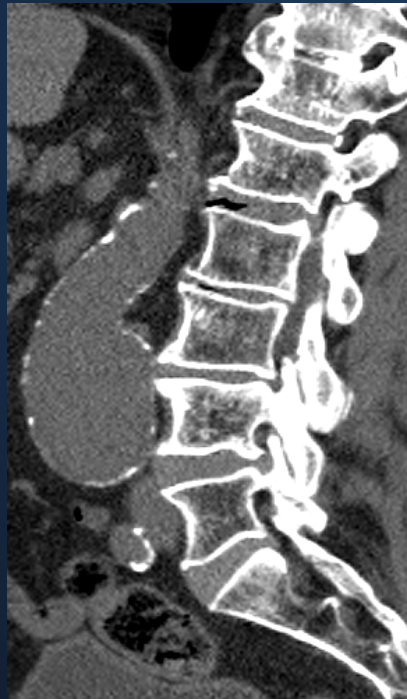- 75 year-old Patient
- CAD
- COPD
- Diabetes
- Renal insufficiency

# Case Presentation

- Asymptomatic infrarenal aneurysm
- Dmax 55 mm
- Proximal neck
  - Slightly bell shaped
- Prominent AMI
- Calcified Iliac arteries

# Case Presentation

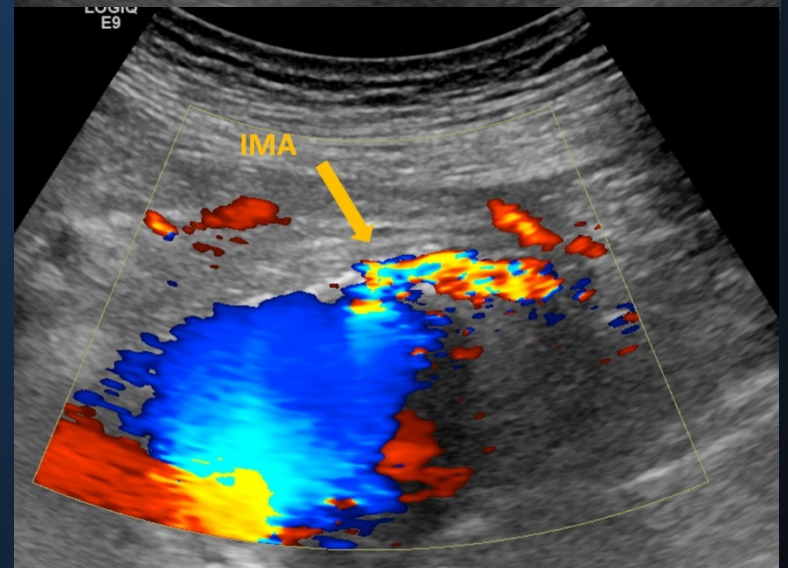
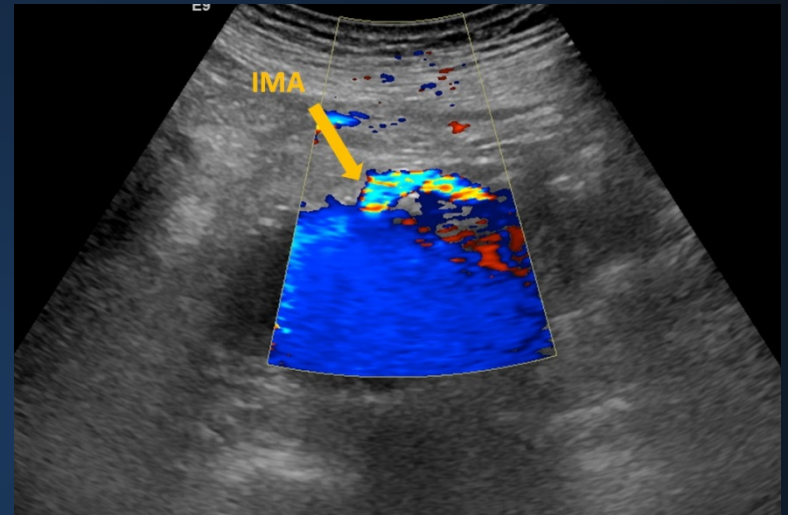
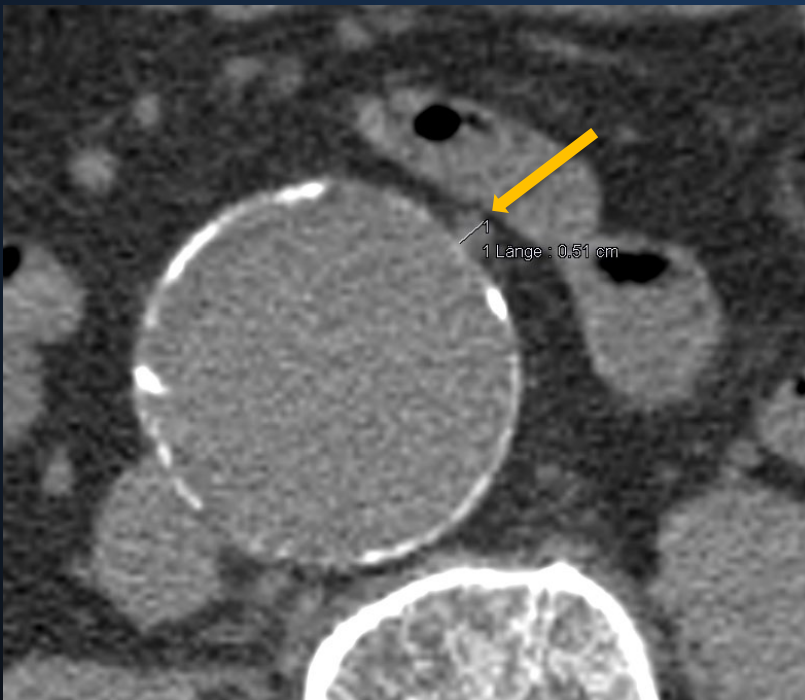
- 55 mm infrarenal Aneurysm
- Conical proximal Neck





# Case Presentation

- Prominent IMA 5mm



# Case Presentation

- Bilateral femoral access
- Plug embolization of the IMA (6mm Amplatzer)
- Gore C3 RLT 311416; PLC 141200 left
- Endoanchor fixation
- Intraoperative CEUS